

5 points on



ANTERIOR CRUCIATE LIGAMENT INJURIES IN YOUNG ATHLETES

Brian M. Schulz, MD, David Levy, BA, and Christopher S. Ahmad, MD

In the past, tibial eminence fractures were considered the pediatric equivalent of adult anterior cruciate ligament (ACL) tears, and ACL tears in the skeletally immature patient were thought to be rare. Recently, however, this idea has been challenged by newer studies reporting a higher incidence of ACL tears in young athletes. Up to 47% of patients aged 7 to 12 years and 65% of patients aged 13 to 18 years who present with an acute traumatic knee hemarthrosis are found to have an ACL tear at time of arthroscopy.¹ Several factors are implicated in the increased incidence of ACL tears in the pediatric population. First, there has been an increase in overall youth participation in cutting-and-pivoting sports, including soccer, football, hockey, and skiing. Second, these athletes are playing at higher intensity at younger ages. Increased participation and intensity in cutting-and-pivoting and contact sports, combined with increased physician awareness and diagnostic methods, are responsible for the increased incidence in pediatric ACL injuries. Last, treatment of ACL injuries in skeletally immature patients remains controversial. In this article, we outline 5 points on diagnosis and treatment of ACL injuries in young athletes.

1 In the workup for a suspected ACL injury in a young patient, associated injuries should be investigated and maturity assessed.

Similar to those in adults, ACL injuries in children most often result from noncontact mechanisms involved in cutting and pivoting. Patients often experience an audible pop and rapid-onset effusion. After the initial event, some young athletes resume full activity without seeking medical attention. Therefore, it is not unusual for patients to sustain repeated episodes of instability before finally seeking medical attention when a bucket-handle meniscal tear causes acute loss of knee extension.

Identifying concomitant injuries that may affect management is crucial. Both active and passive range of motion, as well as varus and valgus instability at 0° and 30° of flexion, should be assessed. Palpation at the distal femoral and proximal tibial physes is performed to evaluate for physeal fractures. Joint-line tenderness, or a positive McMurray test, may signify a meniscal tear. ACL tears

are reliably diagnosed with Lachman and pivot shift tests if the patient is capable of fully relaxing the injured leg.

An estimate of the patient's remaining growth potential influences choice of treatment. Therefore, maturity must be assessed, on the basis of chronologic age, physiologic age, and skeletal maturity. The average adolescent growth spurt begins at 12.5 years in young men and 10.5 years in young women, with completion of growth by 16 years and 14 years, respectively.² Menarche is a sign of maturity in young women, though its timing may be unreliable, as onset of regular menses can be delayed in some athletes. Comparison of the patient's height with that of older siblings and parents can assist in predicting the amount of growth remaining. These predictors of chronologic age serve only as a rough estimate, as they can be widely variable in the normal population. Physiologic age, best classified with use of the Tanner staging system, is a more accurate predictor of future growth, and can be estimated by assessing the characteristics of hair in the axilla and thighs. Above all, skeletal age is the most important factor in estimating remaining growth



Dr. Schulz is Orthopaedic Surgery Resident, Department of Orthopaedic Surgery, Columbia University Medical Center, New York, New York.



Mr. Levy is Medical Student, Columbia University College of Physicians and Surgeons, New York, New York.



Dr. Ahmad is Associate Professor of Clinical Orthopaedic Surgery, Department of Orthopaedic Surgery, Columbia University Medical Center.

Address correspondence to: Brian M. Schulz, MD, Department of Orthopaedic Surgery, Columbia University Medical Center, 11th Floor, 622 W 168th St, PH 1132, New York, NY 10032 (tel, 502-553-9222; fax, 212-305-6193; e-mail, brian.m.schulz@gmail.com).

Am J Orthop. 2011;40(6):279-283. Copyright Quadrant HealthCom Inc. 2011. All rights reserved.

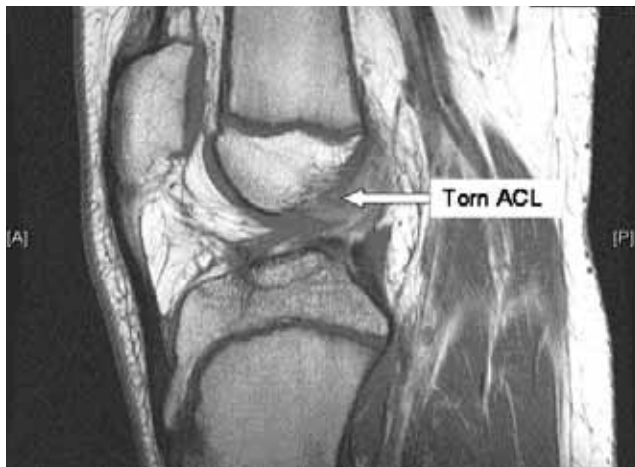

Figure 1. Sagittal magnetic resonance imaging shows anterior cruciate ligament tear in patient with open physes.

potential. Skeletal age can be determined by comparing a posteroanterior radiograph of the patient's hand with images printed in *Radiographic Atlas of Skeletal Development of the Hand and Wrist*.³ Routine radiographs of the knee can be used to assess the degree of physal maturation as well as the presence of physal and tibial eminence fractures. A finding of tenderness at the physis in the setting of negative radiographs warrants magnetic resonance imaging (MRI) to assess for physal injury. MRI is also indicated for suspected ACL injury, meniscal tears, or osteochondral fractures (Figure 1).

2 The natural history of nonoperative treatment for complete ACL tears in children is poor.

The optimum treatment of ACL tears in the skeletally immature patient is the subject of much debate. Supporters of nonoperative management believe that surgical reconstruction should be delayed until the patient reaches skeletal maturity and that physical therapy, bracing, and activity modification should be instituted as temporizing measures. For partial ACL tears, Kocher and colleagues⁴ reported successful nonoperative management in patients younger than 15 years of skeletal age who had normal to near normal Lachman and pivot shift results.

For complete ACL tears, the results of nonoperative treatment are consistently poor. These patients tend to experience persistent instability and pain, and tend not to return to sports. In turn, repeated episodes of instability lead to meniscal tears, chondral injuries, stretching of secondary restraints, and even degenerative joint changes, such as osteophyte formation and joint-space narrowing. Millett and colleagues⁵ found a significantly higher incidence of medial meniscal tears with longer time from initial injury to surgery in pediatric patients. Furthermore, they found that the number of repairable meniscal tears was inversely related to chronicity of ACL injury. Skeletally immature patients who have undergone ACL reconstruction have higher rates of return to sports, more stability, and lower rates of secondary

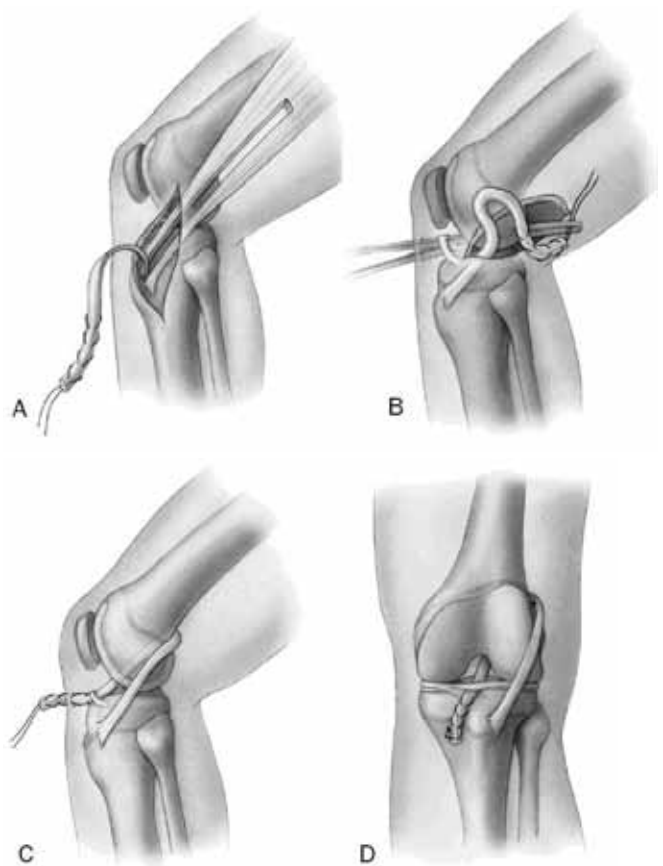


Figure 2. Illustration of anterior cruciate ligament reconstruction using combined intra- and extra-articular physal-sparing technique. (A) Iliotibial band released proximally. (B) Graft brought through over-the-top position using curved clamp. (C) Graft pulled through joint, under intermeniscal ligament. (D) Graft secured to periosteum. Reproduced with permission from Kocher MS, Garg S, Micheli LJ. Physal sparing reconstruction of the anterior cruciate ligament in skeletally immature prepubescent children and adolescents. Surgical technique. *J Bone Joint Surg Am.* 2006;88(suppl 1, pt 2):283-293.

meniscal tears when compared with patients who initially have undergone nonoperative management.⁶⁻⁹

At least 2 explanations can account for the failure of nonoperative management. First, functional braces do not provide adequate stability for patients with ACL deficiency. The precise mechanism of brace efficacy is unknown, and in young patients, proper fit of a brace can be difficult because of their variability in leg length and girth. Second, nonadherence to activity modification is a frequent issue in young patients. Young athletes are often reluctant to adjust their postinjury activity level given their constant exposure to sports and the significance that society and individuals place on athletics. Furthermore, children and adolescents may not appreciate the long-term consequences of an acute knee condition.

Treatment of ACL deficiency in young patients with associated cartilage and meniscal damage has outcomes that are worse than when cartilage and meniscal damage is not present. Shelbourne and Gray¹⁰ found a negative cor-

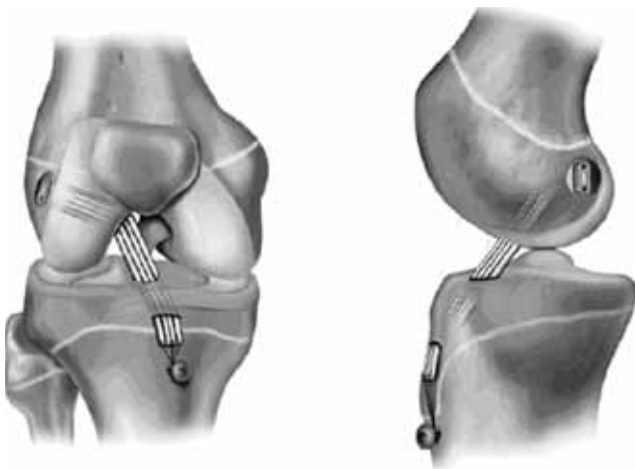


Figure 3. Anteroposterior and lateral illustrations of all-epiphyseal anterior cruciate ligament reconstruction technique. Reproduced with permission from Anderson AF. Transepiphyseal replacement of the anterior cruciate ligament using quadruple hamstring grafts in skeletally immature patients. *J Bone Joint Surg Am.* 2004;86(suppl 1, pt 2):201-209.

relation between long-term subjective and objective outcomes and degree of cartilage and meniscal injury at time of ACL reconstruction. Patients without evidence of chondral or meniscal damage at time of ACL reconstruction had subjective and objective results similar to those of controls. Furthermore, 97% of these patients reported participating in athletic activities at the same or higher level of competition as before surgery. Patients found to have meniscal and cartilage injuries at time of ACL reconstruction, however, had more subjective symptoms and evidence of arthritis at 5- to 15-year follow-up. Shelbourne and Gray concluded that ACL reconstruction is indicated, in patients who want to remain active, to prevent episodes of instability and further damage to the meniscus and cartilage.

3 There is a risk for growth disturbance with ACL reconstruction.

A major concern in managing a skeletally immature patient with an ACL injury is iatrogenic growth plate injury. The closure rate of the distal femoral and proximal tibial physes in young men and young women is 0% at 11 years, 53% at 14 years, and 100% at 16 years or older, and the tibial growth plate has a tendency to close centrally earlier than in the periphery.¹¹ The more growth that remains, the higher the potential for an iatrogenic injury to the physis and, should such an injury occur, the larger the magnitude of the growth disturbance.

Adult ACL reconstruction techniques violate the distal femoral and proximal tibial physis and have shown potential for significant growth arrest, angular deformity, or leg-length discrepancy. Reports of postoperative growth disturbance in the skeletally immature patient are uncommon but do exist. In a series of 24 skeletally immature patients who underwent ACL reconstruction, Lipscomb and Anderson¹² found 7 patients with a leg-length discrepancy. Of these 7 patients, 5 had differences of 6 to 10 mm, 1 had

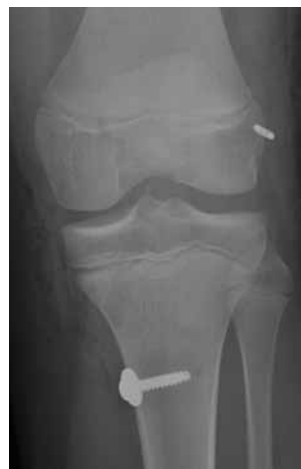

Figure 4. Anteroposterior radiograph after physal-respecting partial transphyseal anterior cruciate ligament reconstruction with transphyseal tibial tunnel and intraepiphyseal femoral tunnel.

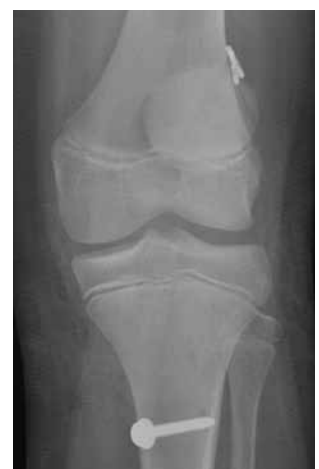

Figure 5. Postoperative anteroposterior radiograph of patient who underwent complete transphyseal anterior cruciate ligament reconstruction.

a difference of 13 mm, and 1 had an operative extremity 2 cm shorter than the contralateral extremity. The leg-length differences, attributed to stapling of the tibial and femoral physes, led Lipscomb and Anderson to modify their fixation technique. Koman and Sanders¹³ presented a case of premature closure of the lateral distal femoral physis that resulted in a valgus deformity. The deformity was thought to be caused by the femoral fixation screw, which traversed the lateral distal femoral growth plate and caused growth arrest. Kocher and colleagues¹⁴ identified 15 skeletally immature patients with growth disturbances after ACL reconstruction. These disturbances included 8 cases of valgus deformity caused by premature arrest of the lateral distal femoral physis, 3 cases of tibial recurvatum from arrest of the tibial tubercle apophysis, 2 cases of genu valgum, and 2 cases of leg-length discrepancy. These growth disturbances resulted from hardware or bone plugs being placed across the physis, from use of large tunnels, and from lateral extra-articular tenodesis.

4 Surgical technique can minimize the risk for growth disturbance.

Research has shown that drilling smaller tunnels, drilling them perpendicular to the physis, filling them only with soft-tissue graft, and lowering graft tensioning minimize the risk for iatrogenic physal injury (Table). In the prepubescent patient, physal-sparing ACL reconstruction is recommended if there is a concomitant meniscal tear or chondral injury, or

Table. Factors Which Minimize Risk of Physal Injury

- Small Tunnels
- Tunnels filled with only soft tissue
- Vertically oriented tunnel placement
- Decreased graft tensioning

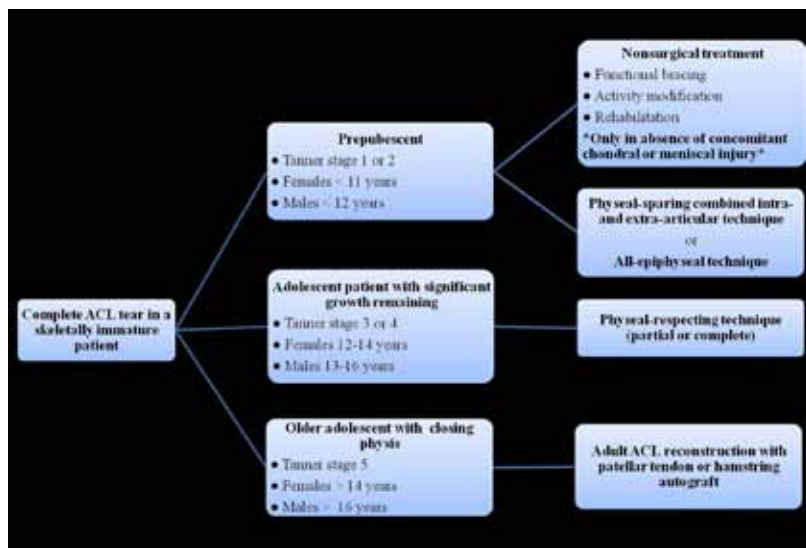


Figure 6. Treatment algorithm for anterior cruciate ligament tears in skeletally immature patients.

if nonoperative management had failed. Multiple physal-sparing techniques have been developed. In general, results are poorer with extra-articular techniques because these techniques are less anatomical and often require extensive dissection or fixation devices near the femoral or tibial physis. Conversely, intra-articular reconstructions have been more successful. Rates of return to preoperative levels of sporting competition range from 67% to 80% with intra-articular reconstructions. Furthermore, no growth abnormalities were reported with any of these techniques. For prepubescent patients, we advocate either a combined intra- and extra-articular reconstruction¹⁵ or the all-epiphyseal technique.^{16,17}

Kocher and colleagues^{15,18} have reported excellent results for a combined intra- and extra-articular physal-sparing reconstruction (Figure 2). Iliotibial band autograft is left intact at its insertion on Gerdy's tubercle. The free proximal end of the graft is brought through the over-the-top position, through the joint, under the intermeniscal ligament, and into a groove prepared in the anteromedial tibial metaphysis. Of 44 children with Tanner stage 1 or 2 growth followed for a mean of 5.3 years after surgery, none developed leg-length discrepancy or angular deformity, and only 2 underwent revision reconstruction for graft failure.

Similar results were reported by Anderson^{16,17} for an all-epiphyseal technique that creates epiphyseal tunnels in the distal femur and proximal tibia (Figure 3). The idea is to create an anatomical position of the hamstring autograft. Under fluoroscopic guidance, the femoral tunnel is started on the lateral condyle distal to the femoral physis, and the tibial tunnel originates anteromedial and proximal to the tibial physis. A cortical button and washer are used for femoral fixation. The graft is then secured distally with locking whipstitch sutures tied to a screw situated distal to the tibial physis. There were no leg-length discrepancies, angular deformities, or revision surgeries reported at 4-year follow-up.

For pubescent adolescents with moderate growth remaining (Tanner stage 3 or 4), we advocate either a physal-respecting procedure (Figure 4) or a physal-sparing intraepiphyseal technique. The principles of a physal-respecting technique are to create tunnels that cross the physis and to use soft-tissue grafts with fixation that do not cross the physis. Tunnel location can be made in anatomical positions. In reports of 10 and 16 adolescent patients, respectively, Fuchs and colleagues¹⁹ and Shelbourne and colleagues²⁰ used patellar tendon grafts that crossed both the tibial and femoral physes. They ensured that the bone plugs and interference screws were placed in metaphyseal bone such that only soft-tissue graft crossed the physes. In 2 larger studies, Aichroth and colleagues⁹ and Kocher and colleagues²¹ performed trans-physal reconstructions (Figure 5) using

hamstring autografts. No growth disturbances or angular deformities were reported in either study.

In adolescent patients approaching skeletal maturity (Tanner stage 5), the risk for growth disturbance is minimal, and adult ACL reconstruction techniques can be used.

In the skeletally immature patient who wants to maintain a high level of activity, the trend now is to be more aggressive with treating ACL injuries to avoid the risks for additional meniscal and cartilage damage and stretching of secondary restraints from repeated episodes of instability. We recommend a trial of nonoperative management only in the prepubescent patient without associated chondral or meniscal injury. Otherwise, we recommend ACL reconstruction using a technique based on remaining growth potential—a physal-sparing technique in the prepubescent or pubescent patient with a large amount of growth remaining and a physal-respecting technique in the patient with less growth remaining. For the adolescent patient who has minimal growth potential, we recommend standard adult ACL reconstruction (Figure 6).

5

Postoperative rehabilitation is required to ensure the best outcome.

For 6 weeks after surgery, the patient should be in a brace to protect the reconstruction. Six weeks of restricted weight-bearing is recommended for the more skeletally immature patient who underwent physal-sparing iliotibial band reconstruction, whereas 2 weeks is recommended for the adolescent patient who underwent physal-respecting hamstring reconstruction. Aggressive rehabilitation, which typically lasts 3 months, consists of leg strengthening, range-of-motion exercises, patellar mobilization, and proprioception training. This rehabilitation is often followed by 3 more months of plyometrics, straight-line jogging, and sport-specific exercises. Patients can expect

to return to full activities about 6 months after surgery. Typically recommended is use of a functional knee brace during athletics for 1 year after surgery. In the case of concomitant medial or lateral collateral ligament injury, rehabilitation and functional bracing should take place before ACL reconstruction to allow time for the collateral ligament injury to heal.²

AUTHORS' DISCLOSURE STATEMENT

The authors report no actual or potential conflict of interest in relation to this article.

REFERENCES

1. Stanitski CL, Harvell JC, Fu F. Observations on acute knee hemarthrosis in children and adolescents. *J Pediatr Orthop*. 1993;13(4):506-510.
2. Brafman RT, Fabian LM, Ahmad CS. Knee ligament injuries in young athletes. In: Ahmad CS, ed. *Pediatric and Adolescent Sports Injuries*. Rosemont, IL: American Academy of Orthopaedic Surgeons; 2010:1-16.
3. Greulich WW, Pyle SI. *Radiographic Atlas of Skeletal Development of the Hand and Wrist*. 2nd ed. Stanford, CA: Stanford University Press; 1959.
4. Kocher MS, Micheli LJ, Zurakowski D, Luke A. Partial tears of the anterior cruciate ligament in children and adolescents. *Am J Sports Med*. 2002;30(5):697-703.
5. Millett PJ, Willis AA, Warren RF. Associated injuries in pediatric and adolescent anterior cruciate ligament tears: does a delay in treatment increase the risk of meniscal tear? *Arthroscopy*. 2002;18(9):955-959.
6. Mizuta H, Kubota K, Shiraiishi M, Otsuka Y, Nagamoto N, Takagi K. The conservative treatment of complete tears of the anterior cruciate ligament in skeletally immature patients. *J Bone Joint Surg Br*. 1995;77(6):890-894.
7. Pressman AE, Letts RM, Jarvis JG. Anterior cruciate ligament tears in children: an analysis of operative versus nonoperative treatment. *J Pediatr Orthop*. 1997;17(4):505-511.
8. McCarroll JR, Rettig AC, Shelbourne KD. Anterior cruciate ligament injuries in the young athlete with open physes. *Am J Sports Med*. 1988;16(1):44-47.
9. Aichroth PM, Patel DV, Zorrilla P. The natural history and treatment of rupture of the anterior cruciate ligament in children and adolescents. A prospective review. *J Bone Joint Surg Br*. 2002;84(1):38-41.
10. Shelbourne KD, Gray T. Results of anterior cruciate ligament reconstruction based on meniscus and articular cartilage status at the time of surgery. Five- to fifteen-year evaluations. *Am J Sports Med*. 2000;28(4):446-452.
11. Sasaki T, Ishibashi Y, Okamura Y, Toh S. MRI evaluation of growth plate closure rate and pattern in the normal knee joint. *J Knee Surg*. 2002;15(2):72-76.
12. Lipscomb AB, Anderson AF. Tears of the anterior cruciate ligament in adolescents. *J Bone Joint Surg Am*. 1986;68(1):19-28.
13. Koman JD, Sanders JO. Valgus deformity after reconstruction of the anterior cruciate ligament in a skeletally immature patient. A case report. *J Bone Joint Surg Am*. 1999;81(5):711-715.
14. Kocher MS, Saxon HS, Hovis WD, Hawkins RJ. Management and complications of anterior cruciate ligament injuries in skeletally immature patients: survey of the Herodicus Society and the ACL Study Group. *J Pediatr Orthop*. 2002;22(4):452-457.
15. Kocher MS, Garg S, Micheli LJ. Physseal sparing reconstruction of the anterior cruciate ligament in skeletally immature prepubescent children and adolescents. *J Bone Joint Surg Am*. 2005;87(11):2371-2379.
16. Anderson AF. Transepiphyseal replacement of the anterior cruciate ligament in skeletally immature patients. A preliminary report. *J Bone Joint Surg Am*. 2003;85(7):1255-1263.
17. Anderson AF. Transepiphyseal replacement of the anterior cruciate ligament using quadruple hamstring grafts in skeletally immature patients. *J Bone Joint Surg Am*. 2004;86(suppl 1, pt 2):201-209.
18. Kocher MS, Garg S, Micheli LJ. Physseal sparing reconstruction of the anterior cruciate ligament in skeletally immature prepubescent children and adolescents. Surgical technique. *J Bone Joint Surg Am*. 2006;88(suppl 1, pt 2):283-293.
19. Fuchs R, Wheatley W, Uribe JW, Hechtman KS, Zvijac JE, Schurhoff MR. Intra-articular anterior cruciate ligament reconstruction using patellar tendon allograft in the skeletally immature patient. *Arthroscopy*. 2002;18(8):824-828.
20. Shelbourne KD, Gray T, Wiley BV. Results of transepiphyseal anterior cruciate ligament reconstruction using patellar tendon autograft in Tanner stage 3 or 4 adolescents with clearly open growth plates. *Am J Sports Med*. 2004;32(5):1218-1222.
21. Kocher MS, Smith JT, Zoric BJ, Lee B, Micheli LJ. Transphyseal anterior cruciate ligament reconstruction in skeletally immature pubescent adolescents. *J Bone Joint Surg Am*. 2007;89(12):2632-2639.

This paper will be judged for the Resident Writer's Award.

Electronic Publications

As of June 2011, all electronically published articles will require registration for full-text access. Registration is free at www.amjorthopedics.com and does not require a print subscription.

How to Register:

- Visit www.amjorthopedics.com
- Click on "Register" at top right
- Follow on-screen instructions
- Activate your account

