Arthroscopic Biceps Tenodesis to Supraspinatus Tendon: Technical Note

Laurent Lafosse, MD, Anup A. Shah, MD, Robert B. Butler, MD, and Rachel L. Fowler, BA

Open or arthroscopic biceps tenodesis is performed when the proximal biceps tendon is thought to be a pain generator. The biceps tendon generates pain, it is believed, in partial-thickness tears of the biceps, in biceps instability, and in biceps tendinopathy, often occurring with rotator cuff pathology and affecting shoulder biomechanics. Management of biceps tendon pathology has been a subject of much interest among shoulder surgeons. Several techniques for tenodesis of the biceps tendon have been described, but few incorporate the biceps into the rotator cuff tendon. These studies have involved techniques that provide a secure tenodesis and fewer incisions with good results.[1-7]

A new technique developed by the senior author (L.L.) incorporates the long head of the biceps tendon with the supraspinatus in patients with anterosuperior rotator cuff tears. Tenodesing the biceps to the supraspinatus theoretically creates opposing forces that help to depress the humeral head and restore some function of the biceps tendon as a dynamic stabilizer. Although this rationale is not supported by biomechanical studies, we have had good results with this technique.

Surgical Technique

The patient is placed in the beach-chair position with the arm in a longitudinal traction device weighing approximately 3 kg (Figure 1A). A standard 30° scope is used for the entire procedure, and a pressure-sensitive fluid pump set to 60 mm Hg is commonly used. A traditional posterior portal is made, and a diagnostic arthroscopy is performed. Our indications for biceps tenodesis include biceps tendonitis (hyperemia, synovitis), tendinopathy, partial- or full-thickness tears, and biceps instability. In addition, the subscapularis is always thoroughly examined.

Once the decision is made to perform a biceps tenodesis, an additional portal is made through the rotator interval just anterior to the long head of the biceps tendon or the supraspinatus ("d" portal in Figure 1B). In cases of anterosuperior cuff tears, this area can be accessed easily from the subacromial space and is often used to prepare the tuberosity for cuff repairs. We obtain this portal with needle localization and use a blunt trocar to create a path for instruments and the scope. If no cuff tear is evident, the portal can still be used, but care must be taken not to damage the intact cuff. The lateral portal ("c") becomes the viewing portal, and "d" becomes the primary working portal (Figure 1B). With this portal, the surgeon can view the supraspinatus, biceps, and subscapularis as well as anchor placement.

"Our indications for biceps tenodesis include biceps tendonitis (hyperemia, synovitis), tendinopathy, partial- or full-thickness tears, and biceps instability."

When intra-articular visualization is adequate, the greater tuberosity is prepared, and a double-loaded suture anchor (5.5 mm; DePuy Mitek, Raynham, Massachusetts) is placed posterior to the biceps groove (Figure 2A). The distance from the biceps groove depends on the size of the anterosuperior cuff tear. With small tears, the anchor is placed just posterior to the groove; in medium-sized tears, the anchor is placed more posteriorly. If no cuff tear is evident, the anchor is placed in the groove.

Next, the biceps is tenodesed to the supraspinatus and humeral head using the lasso-loop technique described by Lafosse and colleagues.[8] Before sutures are passed, the biceps is partially transected near its insertion into the superior labrum (Figure 2B). This step is performed so that the surgeon can pass sutures at sufficient distance from the tenotomy site. A suture limb is then passed through the biceps at the level of the tear and pulled out to form a small lasso, and the instrument is then passed through the lasso and its limb pulled through (Figures 3A, 3B).

Dr. Lafosse is from Clinique Generale d'Annecy, Annecy, France. Dr. Shah and Dr. Butler are from Harvard Shoulder Service/Massachusetts General Hospital, Boston, Massachusetts. Ms. Fowler is from Harvard Shoulder Service/Brigham and Women's Hospital, Boston, Massachusetts.

Address correspondence to: Laurent LaFosse, MD, Clinique Generale d'Annecy, 4 Chemin de la Tour la Reine, 74000 Annecy, France (tel, +33 (0) 450 33 04 69; fax, +33 (0) 450 33 04 71; e-mail, contact@alps-surgery-institute.com).

***Am J Orthop.* 2011;40(7):345-347.**

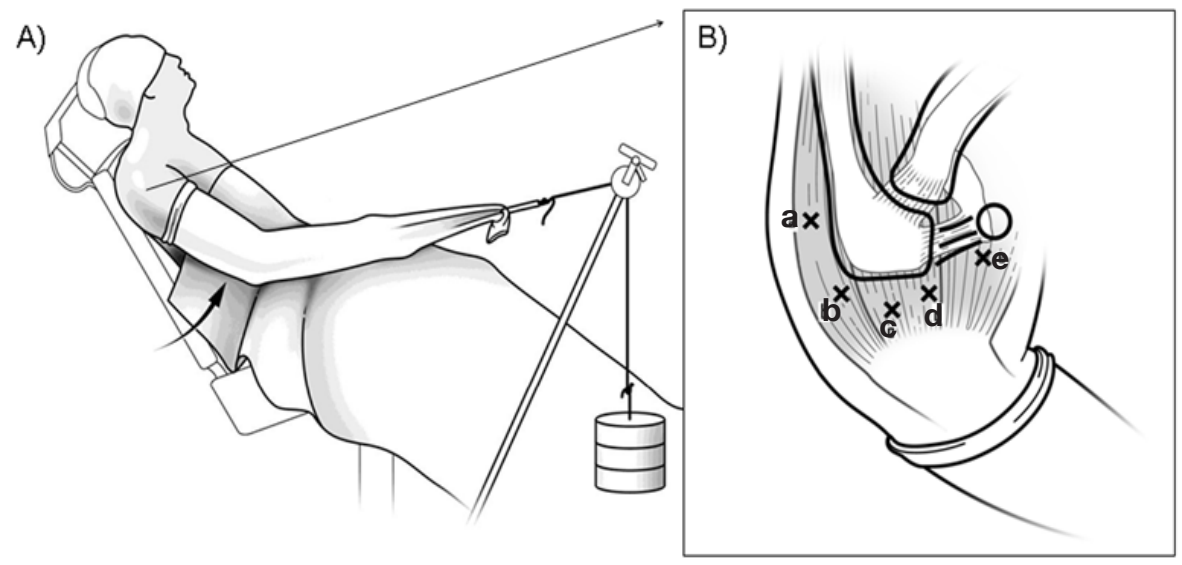

Figure 1. (A) Beach-chair positioning for patient and longitudinal traction device weighing approximately 3 kg. (B) Arthroscopic portals used: (a) posterior, (b) posterior lateral, (c) lateral, (d) anterior lateral, (e) anterior.

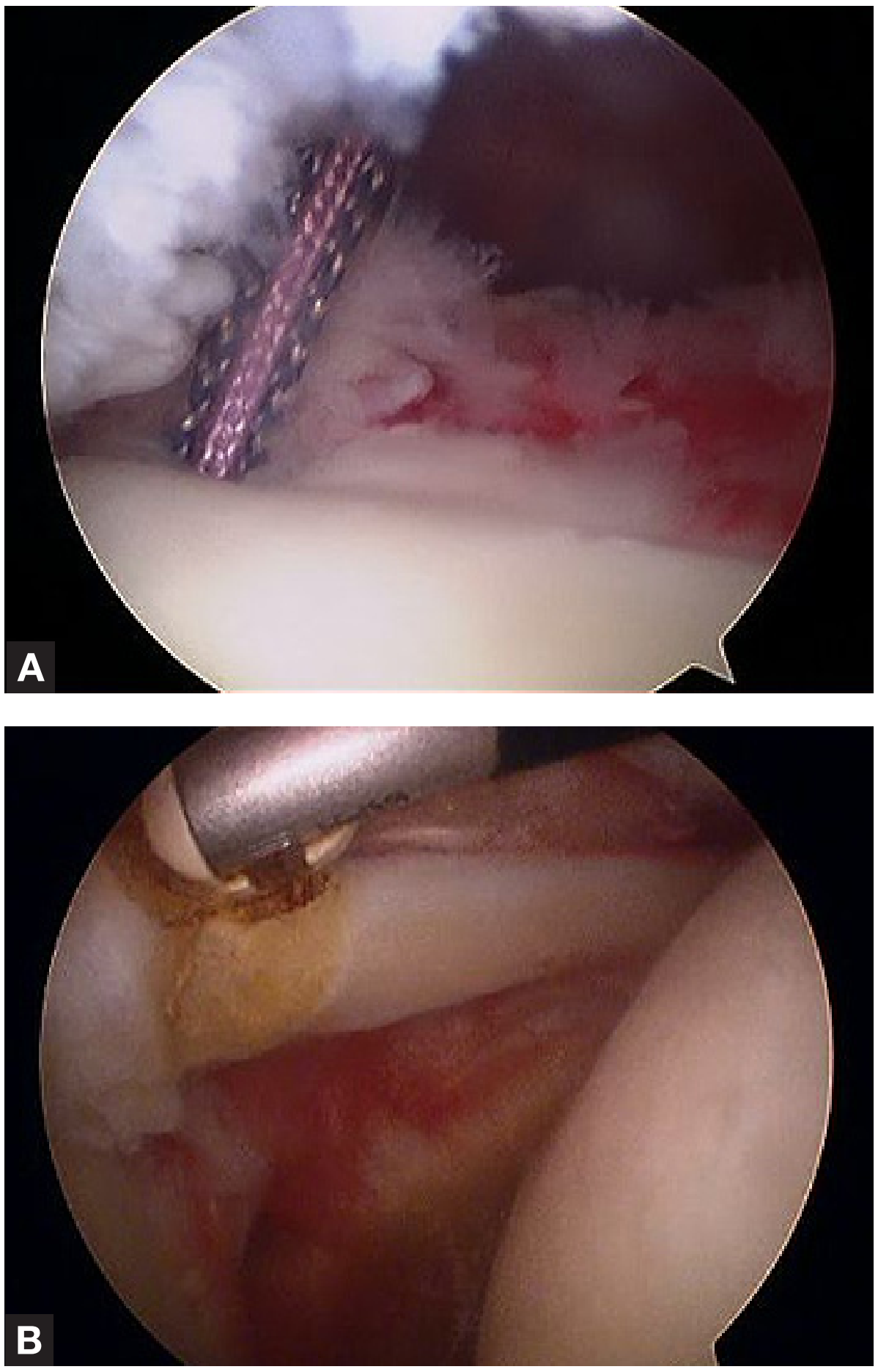

Figure 2. (A) Double-loaded anchor (5.5 mm; DePuy Mitek, Raynham, Massachusetts) placed in greater tuberosity posterior to biceps groove. (B) Partial transection of biceps near superior labral insertion before passing sutures.

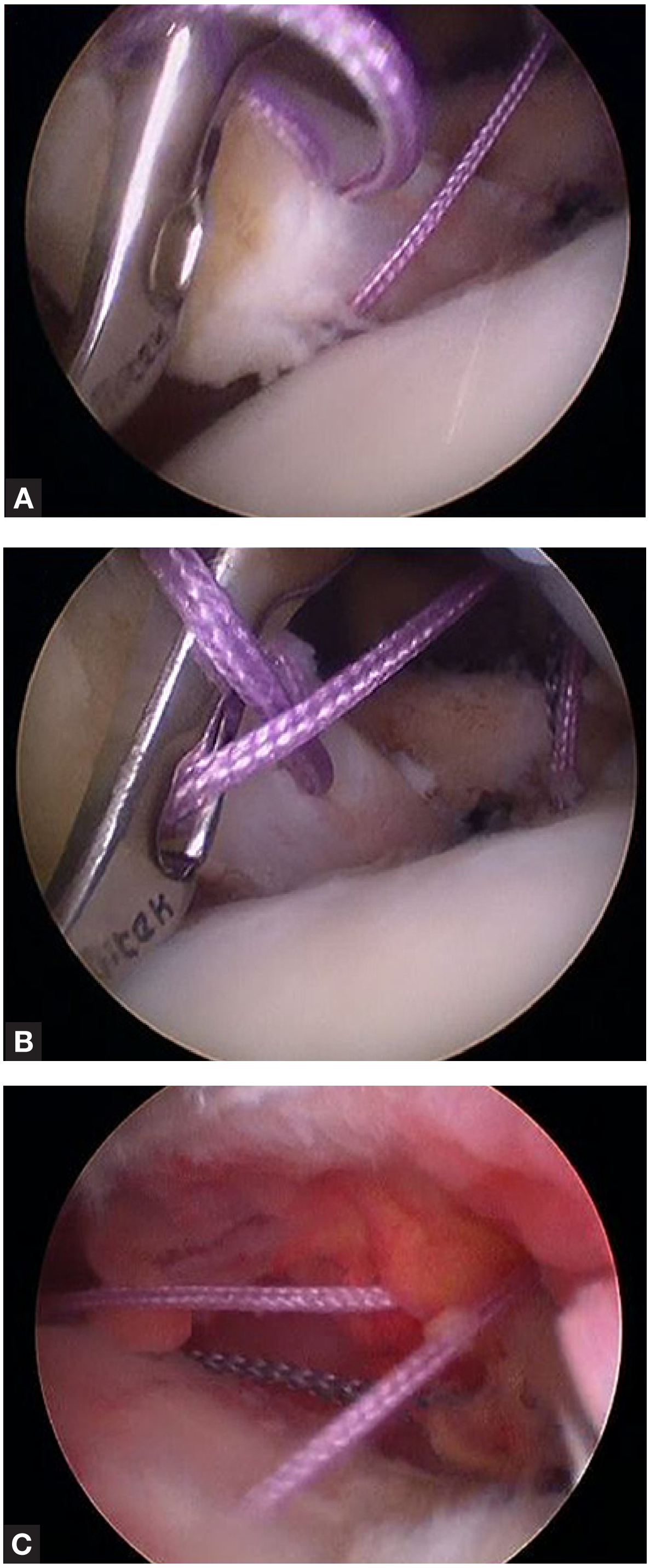

Figure 3. Creation of lasso loop through partially torn biceps: (A) Suture limb is passed through biceps distal to partial transection; (B) limb is pulled back through to form small lasso loop; (C) instrument is passed through lasso.

Once this is complete, the supraspinatus tendon is pierced, and the corresponding suture limb is grasped and pulled completely through the cuff tendon. The suture has now essentially locked the biceps and has been incorporated into the cuff tendon. The other suture limb is then passed in similar fashion through the supraspinatus and biceps tendon. The lasso loop can be switched so the supraspinatus tendon is locked when the sutures are tied. With the first set of sutures, one limb is lasso-looped through the biceps, and the other is passed through the rotator cuff (Figure 3C). Both sutures are then tied using a series of half-hitch knots creating a "pulver taft"–like tenodesis. When the sutures are being tied, the limb passing freely through both tendons is the post; when tension is placed on this limb, the tendons are secured to the bone. The sutures are cut with 5-mm

Figure 4. "Two hands grasping" represents opposing vectors of biceps and supraspinatus in "pulver taft"–like construct believed to be responsible for humeral head depression and compression.

tails. Then the biceps tendon is detached from the labrum using the lateral and anterolateral portals and is debrided to 1 cm of the tenodesis site. In the event of an absent rotator cuff tear, the suture anchor is placed in the biceps groove and attached to the anterior leading edge of the supraspinatus tendon.

Postoperative management consists of either the traditional rotator cuff protocol used at our institution (for rotator cuff tears) or the biceps tenodesis protocol. With cuff repairs, passive range of motion (ROM) is started immediately and continued for 4 to 6 weeks, followed by active and active-assist exercises for the next 6 weeks. Patients usually remain in a sling for 4 weeks. Strengthening begins between 6 and 8 weeks, depending on the integrity of the repair. The biceps tenodesis protocol consists of passive ROM initially, but patients are typically advanced quickly to active ROM. Generally, patients undergo a concomitant acromioplasty or distal clavicle excision. Resisted elbow flexion exercises are delayed until 6 weeks.

Discussion

The function of the long head of the biceps tendon has been debated.[9-11] Multiple biceps tenodesis techniques have been reported. The current method theoretically restores one of the possible functions of the biceps tendon as a glenohumeral joint stabilizer. It is believed that, when the biceps tendon is secured to the supraspinatus, opposing vectors of both muscle tendon units are responsible for humeral head depression and compression into the glenoid. Furthermore, the pulver taft–like construct (Figure 4) is a secure construct with no documented failures.

This technique provides anecdotal evidence that tenodesing the biceps tendon to the anterior edge of the supraspinatus muscle may help restore a possible static and dynamic stabilizer of the glenohumeral joint.

Authors' Disclosure Statement

The authors report no actual or potential conflict of interest in relation to this article.

References

1. Mazzocca AD, Rios CG, Romeo AA, Arciero RA. Subpectoral biceps tenodesis with interference screw fixation. *Arthroscopy.* 2005;21(7):896.
2. Ball C, Galatz L, Yamaguchi K. Tenodesis or tenotomy of the biceps tendon: why and when to do it. *Tech Shoulder Elbow Surg.* 2001;2:140-152.
3. Gartsman G, Hammerman SM. Arthroscopic biceps tenodesis: operative technique. *Arthroscopy.* 2000;16:550-552.
4. Boileau P, Krishnan SG, Coste JS, Walch G. Arthroscopic biceps tenodesis: a new technique using bioabsorbable interference screw fixation. *Arthroscopy.* 2002;18(9):1002-1012.
5. Romeo AA, Mazzocca AD, Tauro JC. Arthroscopic biceps tenodesis. *Arthroscopy*. 2004;20(2):206-213.
6. Checchia SL, Doneux PS, Miyazaki AN. Biceps tenodesis associated with arthroscopic repair of rotator cuff tears. *J Shoulder Elbow Surg.* 2005;14(2):138-144.
7. George MS. Arthroscopic biceps tenodesis incorporated into rotator cuff repair using suture anchors. *Orthopedics*. 2008;31(6):552-555.
8. Lafosse L, Van Raebroeckx A, Brzoska R. A new technique to improve tissue grip: "the lasso-loop stitch." *Arthroscopy.* 2006;22(11):1246.e1-e3.
9. Levy AS, Kelly BT, Lintner SA, Osbahr DC, Speer KP. Function of the long head of the biceps at the shoulder: electromyographic analysis. *J Shoulder Elbow Surg.* 2001;10(3):250-255.
10. Andrews JR, Carson WG Jr, McLeod WD. Glenoid labrum tears related to the long head of the biceps. *Am J Sports Med.* 1985;13(5):337-341.
11. Warner JJ, McMahon PJ. The role of the long head of the biceps brachii in superior stability of the glenohumeral joint. *J Bone Joint Surg Am.* 1995;77(3):366-372.