

# Pain Mapping for Common Shoulder Disorders

Levent Bayam, MBBS, MRCS, Mudussar A. Ahmad, MBBS, MRCS, Syed Z. Naqui, BSc, MSc, FRCS (Tr & Orth), Aroonkumar Chouhan, BSc (Hons), MBChB, and Lennard Funk, BSc, MBBCh, FRCS, MSc, FRCS (Tr & Orth)

## Abstract

We conducted a study to ascertain specific patterns of pain in patients with common shoulder disorders and to describe a comprehensive shoulder pain map. We prospectively studied 94 cases involving an upper limb pain map and correlated the maps with the final diagnoses made by 2 clinicians who were blinded to the pain map findings.

Pattern, severity, and type of pain were specific to each common shoulder disorder. In subacromial impingement, pain was predominantly sharp, occurred around the anterior aspect of the shoulder, radiated down the arm, and was associated with dull, aching pain radiating to the hand. A similar pain pattern was found in rotator cuff tears. In acromioclavicular joint pathology, pain was sharp, stabbing, and well localized to the antero-superior shoulder area. Glenohumeral joint arthritis was marked by the most severe pain, which occurred in a mixed pattern and affected the entire arm. Whereas the pain of instability was a mixture of sharp and dull pain, the pain of calcific tendonitis was severe and sharp. Both pains were limited to the upper arm and shoulder.

Pain mapping revealed definitive patterns for shoulder pathologies. We advocate using pain maps as useful diagnostic guides and research tools.

Conditions that cause shoulder pain are common and contribute substantially to the musculoskeletal morbidity of the community.<sup>1</sup> The incidence of shoulder disorders in the general population has been reported to range from 7% to 36%.<sup>2</sup> Shoulder pain is the third most common cause of musculoskeletal consultation in primary care, and approximately 1% of adults consult a general practitioner with new shoulder pain annually.<sup>3,4</sup>

Mapping for specific disorders has been described for back and hip pain, but not shoulder pain. Pain maps

have been found to be useful for diagnostic, therapeutic, prognostic, and research purposes. Modern pain mapping was introduced in 1949, when Palmer<sup>5</sup> provided outline diagrams of the human body and asked patients to mark on the charts wherever they experienced pain. Use of pain maps in clinical practice is now more widespread, and such maps are part of the McGill Pain Questionnaire.<sup>6</sup>

Although pain patterns for common shoulder disorders have been described in the literature, most reports have been anecdotal. No study has specifically compared and mapped the common shoulder pain pathologies.

We conducted a study to clarify the pain patterns of the common shoulder pathologies—subacromial impingement, rotator cuff tear, glenohumeral joint (GHJ) arthritis, and acromioclavicular joint (ACJ) pathology.

## MATERIALS AND METHODS

We prospectively studied 94 cases of shoulder pain. All patients were new referrals who attended the new patient clinic in an upper limb unit.

Excluded from the study were patients with neck pain symptoms, clinical features indicating neck pathology, previous or multiple shoulder problems, ipsilateral upper limb problems, suspected carpal or cubital tunnel syndrome, or nerve compression.

All patients completed an upper limb pain map before consultation with the clinician. They were given clear verbal, written, and illustrated instructions on how to complete the pain map. The patients who agreed to complete the map were included in the study.

Examining clinicians were blinded to pain map results.

All patients were assessed in an outpatient clinical setting. Assessment involved a detailed history, a physical examination, specific shoulder tests (apprehension test, Hawkins-Kennedy impingement test, Gerber lift-off test), radiography, and ultrasonography. Radiographs included anteroposterior, axillary, and supraspinatus outlet views of the affected shoulder. Ultrasound scans were performed vastly on patients suspected of having a rotator cuff tear, impingement, or calcific tendinitis. Some patients underwent magnetic resonance imaging (MRI), MR arthrography (MRA), and/or arthroscopy later, before their diagnoses were confirmed. Local diag-

Dr. Bayam is Research Fellow, Dr. Ahmad is Senior House Officer, Dr. Naqui is Upper Limb Fellow, Dr. Chouhan is Senior House Officer, and Prof. Funk is Consultant Orthopaedic Surgeon, Wrightington Hospital, Wigan, England.

Address correspondence to: Lennard Funk, BSc, MBBCh, FRCS, MSc, FRCS (Tr & Orth), 120 Princess Rd, Manchester, M15 5AT, England (tel, 0161-2270027; fax, 0161-2270028; e-mail, lenfunk@shoulderdoc.co.uk).

*Am J Orthop.* 2011;40(7):353-358. Copyright Quadrant HealthCom Inc. 2011. All rights reserved.

**Table I. Diagnoses, Mean Age, and Sex of Study Patients (N = 94)**

Diagnosis	No. of Patients	No. of Female Patients	No. of Male Patients	Mean Age, y
Impingement syndrome	28	13	15	57.6
Rotator cuff tear	22	7	15	66.0
Glenohumeral joint arthritis	6	6	0	69.8
Instability	18	5	13	34.4
Acromioclavicular joint pathology	14	5	9	58.6
Calcific tendinitis	6	3	3	46.5

**Table II. Pain Types and Radiation Areas, Both Anterior and Posterior, According to Patient Diagnosis**

Diagnosis	Predominant Pain Type <sup>a</sup>											
	Around Shoulder				Around Arm				Below Elbow			
	S	B	D	P	S	B	D	P	S	B	D	P
Impingement syndrome	18	4	6	—	8	2	16	1	3	—	9	7 <sup>b</sup>
Rotator cuff tear	15	—	7	—	3	—	11	1	3	—	8	1
Glenohumeral joint arthritis	3	1	2	—	3	1	2	—	3	—	2	—
Instability	8	1	9	—	4	—	4	1	—	—	—	—
Acromioclavicular joint pathology	12	1	1	—	—	—	5	—	—	—	2	—
Calcific tendinitis	5	—	1	—	4	1	—	—	—	—	—	—

<sup>a</sup>No. of patients with sharp, stabbing, or shooting pain (S), burning pain (B), dull, aching pain (D), or pins and needles and numbness (P).

<sup>b</sup>These patients, who described pins and needles mainly on the dorsum of their hands, were particularly assessed to exclude other distal upper limb problems (eg, carpal tunnel and nerve compression disorders).

nostic injections were made in several cases, particularly in those in which the clinical diagnosis suggested ACJ pathology, impingement, or calcific tendinitis.

The opinions of 2 clinicians were sought in conjunction with the other investigations to help increase the precision of the diagnoses. The definitive diagnoses were not coded to the questionnaire form until all the assessments were completed for each patient.

We used a custom-made upper limb pain map (Figure 1). This map illustrates pain type, severity, and areas of radiation, including the anterior and posterior parts of the arm, and the neck and shoulder. Each side of the arm was divided into 14 sections or cells, giving a total of 28 cells. The areas of the ACJ and the axilla were included among the cells. Patients were asked to indicate on the map which of 4 types of pain they were feeling and to illustrate each with a symbol: sharp, stabbing, or shooting pain (+), burning pain (o), dull, aching pain (•), and pins and needles and numbness (Δ). For analysis, the letters S, B, D, and P, respectively, were used (Figure 1).

Pain severity was assessed with a visual analogue scale (VAS) (Figure 1). Patients rated the intensity of pain on a continuum from “no pain” to “maximal, worst pain imaginable.” The VAS score is the distance from the lowest pain level to the mark made by the patient.<sup>7</sup>

Final diagnoses made by the clinicians, who were blinded to the map questionnaire, were then correlated with the results of the pain maps. Cells where the appropriate symbols had been marked were con-

sidered positive. Distribution of pain was correlated with clinical diagnosis to ascertain a relationship between pain site and particular shoulder pathology. These helped increase the strength of the internal validity of the study.

Date: \_\_\_\_\_ Salford Royal Hospitals NHS  
NHS Trust

**Shoulder Pain Radiation Form**  
Lead Investigators: A Chouhan & L Funk

**Patient Details** Name: \_\_\_\_\_  
Date of Birth: \_\_\_\_\_ Hospital Number: \_\_\_\_\_  
Sex: M / F

Please draw and shade in the area of your pain on the diagram using the guide below:  
(eg. draw an area of crosses where you have stabbing/sharp pain)

Indicate on this line how bad your pain is – at the end of the line means no pain at all, at the right end of the line means worst pain possible

No Pain \_\_\_\_\_ Worst Pain Possible

**Figure 1. Sample map to be marked by patients.**

**Table III. Shoulder/Upper Arm Disorders With Below-Elbow Pain Radiation**

Shoulder/Upper Arm Disorder	No. of Patients With Disorder	No. (%) of Patients With Below Elbow Pain
Impingement syndrome	28	13 (46.4%)
Rotator cuff tear	22	12 (54.5%)
Glenohumeral joint arthritis	6	5 (83.3%)

**Table IV. Shoulder/Upper Arm Disorders With Pain Predominantly in Shoulder**

Shoulder/Upper Arm Disorder	No. of Patients With Disorder	No. (%) of Patients With Below Elbow Pain
Instability, including SLAP/Bankart lesion	18	0 (0%)
Acromioclavicular joint pathology	14	2 (14.3%)
Calcific tendinitis	6	0 (0%)

Abbreviation: SLAP, superior labrum from anterior to posterior.

**Table V. Mean No. of Cells Marked by Patients With any Type of Pain,<sup>a</sup> and Pain Severity in Each Group**

Diagnosis	Mean No. of Cells (N = 28) <sup>a</sup>	Mean VAS score
Impingement syndrome	7.21	7.80
Rotator cuff tear	5.60	7.05
Glenohumeral joint arthritis	12.5	7.83
Instability	6.88	6.72
Acromioclavicular joint pathology	3.86	6.43
Calcific tendinitis	5.5	7.5

Abbreviation: VAS, Visual Analogue Scale.

<sup>a</sup>There were a total of 28 cells anterior and posterior on the map.

Ethical opinion was sought and obtained from the local Research and Development department for the study.

Statistical analysis, performed with SPSS 16.0 for Windows (SPSS, Chicago, Illinois), included probability-probability plot for distribution and Pearson correlation tests.

## RESULTS

In this study, subacromial impingement and rotator cuff tear were the most common shoulder conditions. Younger patients predominantly had shoulder instability, including superior labrum from anterior to posterior (SLAP) and Bankart lesions. Mean age was 34.4 years in the instability group, 46.5 years in the calcific tendonitis group, and 69.8 years in the GHJ arthritis group (Table I). The GHJ arthritis group was the oldest.

In subacromial impingement, rotator cuff tear, and GHJ arthritis, pain radiated to the forearm (Table II; Figures 2A–2C). In shoulder instability, calcific tendonitis, and ACJ pathology, pain was more localized around the shoulder and upper arm (Table II; Figures 2D–2F).

GHJ arthritis had a mixed pattern of pain that was described as sharp, shooting, burning, and dull aching that affected the entire arm from shoulder to hand

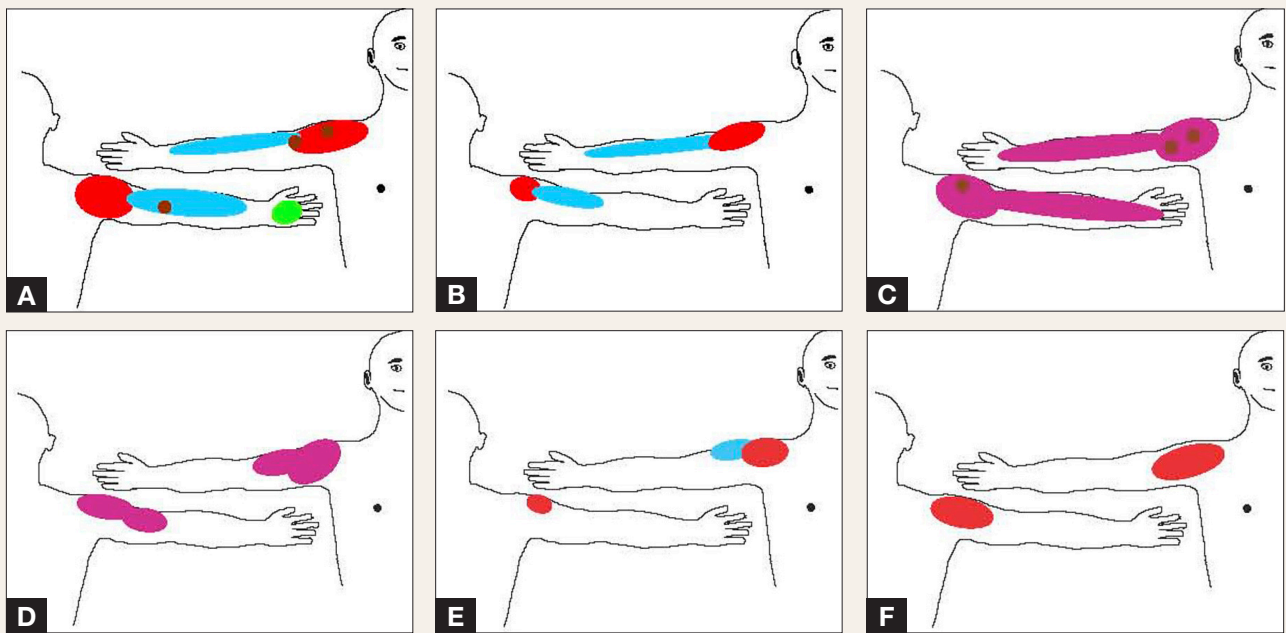
(Figure 2C). Patients with subacromial impingement had predominantly sharp pain around the front of the shoulder and dull, aching pain affecting the rest of the arm and forearm. In addition, 7 patients described pins and needles around the hand (Tables II, III; Figure 2A).

Pain from ACJ pathology was predominantly sharp and stabbing and localized to the anterior aspect of the shoulder, and it did not radiate down the forearm (Tables II, IV, V; Figure 2E).

The pain pattern for patients with rotator cuff tears was very similar to that for patients with impingement syndrome (Figure 2B). Patients with calcific tendonitis described a shooting pain in the area of the shoulder with no radiation to elbow or hand, whereas patients with instability described a mixture of sharp and dull pain without radiation to forearm (Tables II–IV; Figures 2D, 2F).

Pins and needles and numbness in the hands were described only in subacromial impingement (7/28 cells). Burning sensations were rare and described mainly in impingement and GHJ arthritis (Table II; Figures 2A, 2C).

The probability-probability plot for distribution showed that both pain severity and number of areas



**Figure 2.** Type and distribution of pain for: impingement syndrome (A), rotator cuff tear (B), glenohumeral joint arthritis (C), instability (D), acromioclavicular joint pathology (E), and calcific tendonitis (F).

#### Color coding of pain

- Sharp/shooting/stabbing pain
- Dull and/or aching pain
- Numbness and/or pins & needles
- Mixture of dull and sharp pain
- Burning pain

were normally distributed. Analysis of VAS scores showed that patients with GHJ arthritis had the most severe pain (mean score, 7.83/10), followed closely by patients with impingement (mean score, 7.80). The least severe pain (mean score, 6.43) was described by patients with ACJ pathology. Similarly, patients with instability had a mean score of 6.72. The other mean scores were 7.05 for rotator cuff tears and 7.50 for calcific tendinitis (Table V). There was no statistically significant difference in range of pain between the diagnoses ( $F_{5,87} = 1.138$ ;  $P = .347$ ).

The pain map consisted of a total of 28 marked sections or cells, 14 on each side of the arm (Figure 1). Analysis showed how well the pain was localized for each particular shoulder condition (Table V). The mean pain score ranged from 3.86 for ACJ pathology to 12.5 for GHJ arthritis, indicating the diffuse nature of pain from GHJ arthritis and the pinpoint nature of pain from ACJ pathology.

Pearson correlation tests demonstrated statistically weak correlation between number of areas and pain severity ( $r = 0.194$ ,  $P = .64$ ), but 1-way analysis of variance showed a meaningful difference in number of areas marked by patients between groups ( $F_{5,87} = 3.550$ ;  $P = .006$ ). Post hoc multiple comparisons showed meaningful differences, particularly between GHJ arthritis and rotator cuff tears ( $P = .014$ ) and between GHJ arthritis and ACJ pathology ( $P = .002$ ).

## DISCUSSION

Pain is the most common symptom in orthopedics, and a variety of terms are used to describe it. There are clear differences between the throbbing pain of an abscess, the aching pain of chronic arthritis, the burning pain of neuralgia, and the stabbing pain of a ruptured tendon. The precise location of pain is important in orthopedics but does not always correlate with the site of pathology. Pain arising in or near the skin is usually localized accurately, as is pain from intrinsic shoulder pathology.<sup>8</sup> Pain arising in deeper structures is more diffuse, and in some cases, it has an unexpected distribution.<sup>9</sup> One explanation for the unexpected pain distribution in the shoulder is the proximal location in the sclerotome and the extensive convergence of afferent signals from this area to the dorsal horn of the spinal cord. The sclerotome is defined as pain arising within the periosteum and muscle innervated by a spinal segment.<sup>10</sup>

Pain patterns can be broadly distributed to the deltoid, the trapezius, and the posterior scapular area. Location of symptoms may or may not correspond to proximity of pain generator.<sup>11</sup> Cervical disk disease commonly presents with pain referred to the shoulder. This pain is most often referred to the posterior aspect of the shoulder and the trapezius and occasionally to the forearm or the hand.<sup>8</sup> Other examples of referred pain involving the shoulder

include pain caused by stimulation of the diaphragmatic tendon center.<sup>12</sup>

Likewise, shoulder pain with radiation to arm and hand in an ulna nerve distribution could be an indicator of the existence of a Pancoast tumor.<sup>13</sup> Pain from the sternoclavicular joint can be referred to areas distant from the joint.<sup>14</sup> Many different shoulder disorders cause similar symptoms and pain patterns.<sup>15</sup> The results from our pain-mapping study correlate with this for certain shoulder conditions, such as instability, calcific tendonitis, and ACJ pathology. Pain was radiated much farther in subacromial impingement, torn rotator cuffs, and GHJ arthritis.

Although the diagnosis of shoulder disorders should not be based on clinical examination alone, some of the tests performed with suggested standardizations are highly reproducible and therefore reliable to use in clinical practice.<sup>16-18</sup> The Neer impingement sign, the Hawkins-Kennedy impingement test, and the Jobe supraspinatus test are well described. The O'Brien sign is helpful in diagnosing superior labral detachment.<sup>19</sup>

One of the major groups of patients in our study was diagnosed with impingement syndrome. The combination of the Hawkins-Kennedy impingement sign, the painful arc sign, and the infraspinatus muscle test yielded the best posttest probability, up to 95%, for any degree of impingement syndrome.<sup>20</sup> Steroid injection is used for both diagnostic and treatment purposes in impingement syndrome.<sup>21</sup> In our study, all physical tests were extensively used by clinicians, and injection helped to diagnose mainly impingement syndrome and ACJ pathology.

On the other hand, shoulder pain associated with rotator cuff disorders and glenohumeral osteoarthritis can be diagnosed in the majority of patients on the basis of medical history, focused physical examination, and plain radiographs.<sup>22</sup> Anteroposterior, axillary, and supraspinatus outlet plain radiographs of the affected shoulder were part of our assessment for each patient and were specifically more helpful in diagnosing ACJ pathology and GHJ arthritis. In addition, positive results of radiographs can be helpful in diagnosing calcific tendinitis.<sup>23</sup>

Advanced investigations to diagnose shoulder disorders include MRI, MRA, ultrasound, and computed tomography (CT). Whereas the preferred test for diagnosing rotator cuff disorders is MRI,<sup>24</sup> MRA has become the preferred test for the imaging of suspected labral pathology.<sup>23,25</sup> Ultrasound also could be more cost-effective in a specialist hospital setting for identification of full-thickness tears.<sup>24</sup> In our series, ultrasound was used in addition to MRI or MRA for each patient when rotator cuff tears, calcific tendinitis, or impingement was suspected in the outpatient setting. No patient underwent CT for pain mapping. In addition, all diagnostic coding was done before arthroscopic procedures.

For accurate clinical diagnosis, overall evaluation by an experienced clinician is necessary.<sup>9</sup> In our clinical set-

ting, all initial assessments are performed by experienced specialist clinicians and with baseline investigations.

Gerber and colleagues<sup>26</sup> tried to ascertain the distribution of ACJ and subacromial impingement pain by injecting hypertonic saline into the ACJ and subacromial spaces of normal patients. ACJ irritation resulted in burning pain felt over the joint, deep in the supraspinatus fossa, and in the upper trapezius. This is similar to our findings in the mapping of ACJ pain, where pain was mainly localized to the anterior and dorsal aspects of the shoulder, but differs in the distribution of pain down the posterior aspect of the arm. The pain was mainly the stabbing type but also had dull and burning components. Subacromial irritation in the article by Gerber and colleagues<sup>26</sup> resulted in an intense pain, mainly in the lateral border of the acromion and the lateral portion of the deltoid muscle. Pain mapping of subacromial impingement has similar features, with predominantly sharp pain around the front of the shoulder and down the posterior aspect of the arm with additional features of a dull, aching, and burning pain anteriorly that radiates to the hand. Toomingas<sup>27</sup> examined chronic and severe pain and correlated it with patients' pain drawings. The drawings made by patients with more chronic or severe pain symptoms occupied a larger area. As suggested, our study also showed the same correlation between pain severity and radiation area. The most severe pain occurred in GHJ arthritis patients, who marked a mean of 12.5 of 28 cells on the pain map (the most cells marked by any of the groups). Moreover, pain from ACJ pathology was the most pinpointed. Patients with ACJ pathology marked a mean of only 3.9 areas, and their pain (mean VAS score, 6.43) was the least severe.

The primary types of self-reported pain measures are the VAS, the verbal rating scale, the numerical rating scale, and pain drawings. Each method has its advantages and disadvantages.<sup>28</sup> The VAS and the numerical rating scale create ratio-level data that are more easily comparable. In our study, we used VAS to compare pain severity.

The medical literature describes pain maps for neck, face, back, and hip pain,<sup>27,29,30</sup> but not for shoulder disorders. This is the first study to describe use of shoulder pain maps. A definitive pattern of pain distribution and specific types of pain in common shoulder pathologies has been demonstrated. We advocate using pain maps as diagnostic tools in shoulder clinics. Pain maps can be further expanded as diagnostic aids in combined neck-and-shoulder pathology and in multiple shoulder pathologies.

After interventions such as subacromial injection, ACJ injection, physiotherapy, and arthroscopic shoulder surgery, pain maps can provide a more objective indicator of improvement in pain symptoms. Our study can be expanded by surgeons who complete pain maps after taking patients' histories to find out whether a correla-

tion exists between pain maps drawn by surgeons and those drawn by patients.

### AUTHORS' DISCLOSURE STATEMENT

The authors report no actual or potential conflict of interest in relation to this article.

### REFERENCES

1. Bjelle A. Epidemiology of shoulder problems. *Baillieres Clin Rheumatol*. 1989;3(3):437-451.
2. Lundberg B. The frozen shoulder. Clinical and radiographical observations. The effect of manipulation under general anesthesia. Structure and glycosaminoglycan content of the joint capsule. Local bone metabolism. *Acta Orthop Scand Suppl*. 1969;119:1-59.
3. Mitchell C, Adebajo A, Hay E, Carr A. Shoulder pain: diagnosis and management in primary care. *BMJ*. 2005;331(7525):1124-1128.
4. Urwin M, Symmons D, Allison T, et al. Estimating the burden of musculoskeletal disorders in the community: the comparative prevalence of symptoms at different anatomical sites, and the relation to social deprivation. *Ann Rheum Dis*. 1998;57(11):649-655.
5. Palmer H. Pain charts; a description of a technique whereby functional pain may be distinguished from organic pain. *N Z Med J*. 1949;48(264):187-213.
6. Rankine JJ, Fortune DG, Hutchinson CE, Hughes DG, Main CJ. Pain drawings in the assessment of nerve root compression: a comparative study with lumbar spine magnetic resonance imaging. *Spine*. 1998;23(15):1668-1676.
7. Jensen MP, Karoly P. Pain-specific beliefs, perceived symptom severity, and adjustment to chronic pain. *Clin J Pain*. 1991;8(2):123-130.
8. Dee R, Hurst LC, Gruber MA, Kottmeier SA. Principles of orthopaedic practice. In: Rodowsky MW, Bigliani LU. *The Shoulder and the Shoulder Girdle*. 2nd ed. New York, NY: McGraw-Hill; 1997:1063.
9. Apley AG, Solomon L. *Apley's System of Orthopaedics and Fractures*. 7th ed. Oxford, England: Butterworth-Heinemann; 1993.
10. Inman VT, Saunders JB. Referred pain from skeletal structures. *J Nerv Ment Dis*. 1944;99(5):660-667.
11. Sizer-Phillip S Jr, Phelps V, Gilbert K. Diagnosis and management of the painful shoulder. Part 2: examination, interpretation, and management. *Pain Pract*. 2003;3(2):152-185.
12. Di Massa A, Avella R, Gentili C. Respiratory dysfunction related to diaphragmatic shoulder pain after abdominal and pelvic laparoscopy. *Minerva Anestesiol*. 1996;62(5):171-176.
13. Kovach SG, Huslig EL. Shoulder pain and Pancoast tumor: a diagnostic dilemma. *J Manipulative Physiol Ther*. 1984;7(1):25-31.
14. Hassett G, Barnsley L. Pain referral from the sternoclavicular joint: a study in normal volunteers. *Rheumatology (Oxford)*. 2001;40(8):859-862.
15. Larson HM, O'Connor FG, Nirschl RP. Shoulder pain: the role of diagnostic injections. *Am Fam Physician*. 1996;53(5):1637-1647.
16. Johansson K, Ivarson S. Intra- and interexaminer reliability of four manual shoulder maneuvers used to identify subacromial pain. *Man Ther*. 2009;14(2):231-239.
17. Guanche CA, Jones DC. Clinical testing for tears of the glenoid labrum. *Arthroscopy*. 2003;19(5):517-523.
18. Ure BM, Tiling T, Kirchner R, Rixen D. Reliability of clinical examination of the shoulder in comparison with arthroscopy [in German]. *Unfallchirurg*. 1993;96(7):382-386.
19. Tzannes A, Murrell GA. Clinical examination of the unstable shoulder. *Sports Med*. 2002;32(7):447-457.
20. Park HB, Yokota A, Gill HS, El Rassi G, McFarland EG. Diagnostic accuracy of clinical tests for the different degrees of subacromial impingement syndrome. *J Bone Joint Surg Am*. 2005;87(7):1446-1456.
21. Fraser-Moodie JA, Shortt NL, Robinson CM. Injuries to the acromioclavicular joint. *J Bone Joint Surg Br*. 2008;90(6):697-708.
22. Meislin RJ, Sperling JW, Stitik TP. Persistent shoulder pain: epidemiology, pathophysiology, and diagnosis. *Am J Orthop*. 2005;34(12 suppl):5-9.
23. Burbank KM, Stevenson JH, Czarniecki GR, Dorfman J. Chronic shoulder pain: part I. Evaluation and diagnosis. *Am Fam Physician*. 2008;77(4):453-460.
24. Dinnes J, Loveman E, McIntyre L, Waugh N. The effectiveness of diagnostic tests for the assessment of shoulder pain due to soft tissue disorders: a systematic review. *Health Technol Assess*. 2003;7(29):iii, 1-166.
25. Van der Woude HJ, Vanhoenacker FM. MR arthrography in glenohumeral instability. *JBR-BTR*. 2007;90(5):377-383.
26. Gerber C, Galantay RV, Hersche O. The pattern of pain produced by irritation of the acromioclavicular joint and the subacromial space. *J Shoulder Elbow Surg*. 1998;7(4):352-355.
27. Toomingas A. Characteristics of pain drawings in the neck-shoulder region among the working population. *Int Arch Occup Environ Health*. 1999;72(2):98-106.
28. Disorbio JM, Bruns D. Diagnosis specific norms for the 0-10 pain scale. Paper presented at: World Congress on Pain; Vienna, Austria; 1999.
29. Machacek P, Friedrich M. Pain patterns of disc lesions of the lumbar spine. *Z Orthop Ihre Grenzgeb*. 2006;144(1):19-26.
30. Turp JC, Kowalski CJ, O'Leary N, Stohler CS. Pain maps from facial pain patients indicate a broad pain geography. *J Dent Res*. 1998;77(6):1465-1473.

## CALL FOR PAPERS

## TIPS OF THE TRADE

We invite you to use the journal as a forum for sharing your tips with your colleagues.

All submitted manuscripts will be subject to the journal's standard peer-review process.

Manuscripts should be submitted via Editorial Manager® ([www.editorialmanager.com/amjorthop](http://www.editorialmanager.com/amjorthop))

Please follow the guidelines listed in Guidelines for Authors found on our Web site, [www.amjorthopedics.com](http://www.amjorthopedics.com)

