

Hypothenar Hammer Syndrome

David Dreizin, MD, and Jean Jose, DO

Abstract

Hypothenar hammer syndrome is a rare, but likely underdiagnosed occupational or recreational malady, resulting from repetitive microtrauma to the ulnar artery at the level of Guyon's canal. Significant diagnostic and treatment delays are associated with high morbidity, therefore early recognition is of the utmost importance. We discuss specific imaging features, emphasizing findings at ultrasound, computed tomography, and magnetic resonance imaging, that favor the diagnosis in the appropriate clinical context. Definitive evaluation is made with catheter directed angiography, which remains the gold standard for diagnosis. The range of management options, which depend on the degree of severity and the presence or absence of ulnar artery aneurysm, are also presented.

Hypothenar hammer syndrome (HHS) is a rare but potentially curable occupational or recreational disease, which is caused by chronic repetitive or acute severe blunt trauma to the hypothenar eminence of the hand.^{1,2} Although it was first recognized by von Rosen in 1934,³ a long time elapsed until a traumatic cause was described.⁴ The term was coined by Conn and colleagues in 1970,⁵ as it is classically seen in industrial workers who repeatedly use the hypothenar eminence as a substitute for a hammer.⁶ A number of case reports have subsequently documented the condition in athletes, and it has also been linked to vibration exposure from jack hammers and power tools.^{4,7} In a retrospective study of 47 patients with HHS, Marie and colleagues⁸ found an occupational exposure to repetitive palmar trauma in 43 of 47 patients (91.5%). The activity associated with this mechanism of injury is commonplace, yet the occurrence of HHS is surprisingly low. In a large prospective study, Ferris and colleagues⁹ enrolled 1300 patients with hand ischemia and found an incidence of HHS in 1.6% of patients.

Dr. Jose is Assistant Professor, Musculoskeletal Imaging Section, and Dr. Dreizin is Resident, Department of Radiology, University of Miami Miller School of Medicine, Miami, Florida.

Address correspondence to: Jean Jose, DO University of Miami Miller School of Medicine, Jackson Memorial Hospital, Department of Radiology (R-109), 1611 N.W. 12th Avenue, West Wing 279, Miami, FL 33136 (tel, 305-585-8182; e-mail; jjose@med.miami.edu).

Am J Orthop. 2012;41(8):380-382. Copyright Quadrant HealthCom Inc. 2012. All rights reserved.

PATHOPHYSIOLOGY

The pathogenesis of HHS is attributable to the unique anatomy of Guyon's canal. At the distal end of the canal, the terminal segment of the ulnar artery and proximal portion of the superficial palmar arch are vulnerable to injury as they pass between the hook of the hamate and the pisiform. Their only protection is afforded by the palmar aponeurosis, palmaris brevis muscle, subcutaneous tissues, and the overlying skin.^{2,6,8,10} Blunt impact over the distal aspect of Guyon's canal can compress the poorly protected ulnar artery against the hook of the hamate. Damage to the intima causes loss of endothelial antithrombogenicity leading to thrombosis and segmental occlusion.^{2,11} Injury to the media causes aneurysm and distal embolization. Marie and colleagues⁸ describe angiographic evidence of ulnar artery occlusion in 59.6%, aneurysm in 40.4%, and embolic occlusions of the digital arteries in 57.4%. Segmental occlusion and microemboli to the digital arteries may result in vascular insufficiency of the hand and secondary Raynaud's phenomenon.⁶ A link to fibromuscular dysplasia has also been reported, however this remains controversial.⁹

CLINICAL FEATURES

The differential diagnosis for upper extremity digital ischemia includes primary Raynaud's disease, connective tissue disease, thromboangiitis obliterans (Buerger's disease), thoracic outlet obstruction, cardiac emboli, and atherosclerotic disease.^{2,11} Systemic causes of Raynaud's phenomenon including scleroderma, systemic lupus erythematosus, and rheumatic disease, can be excluded with laboratory testing for appropriate serologic markers, and an echocardiogram should be performed to rule out a cardiac source of emboli. Important clues distinguishing HHS from other causes of upper extremity ischemia include male predominance (mean age, 42 years), occupational history, asymmetric distribution typically involving the dominant hand, and digital ulcers in the distribution of the ulnar artery. While HHS is one of the less common causes of upper extremity ischemia, a high index of suspicion should be maintained, as delayed diagnosis may have irreversible consequences.^{2,8,12}

The clinical manifestations of HHS often consist of pain over the hook of the hamate, digit ischemia, and paresthesias. Severity of symptoms depends on the extent of vessel occlusion and the presence of collaterals between the deep and superficial palmar arches.⁶ Although presentation may be acute in cases of severe blunt trauma, more commonly, onset is prolonged with intermittent signs and symptoms persisting for years. The inciting injury may not be volunteered by

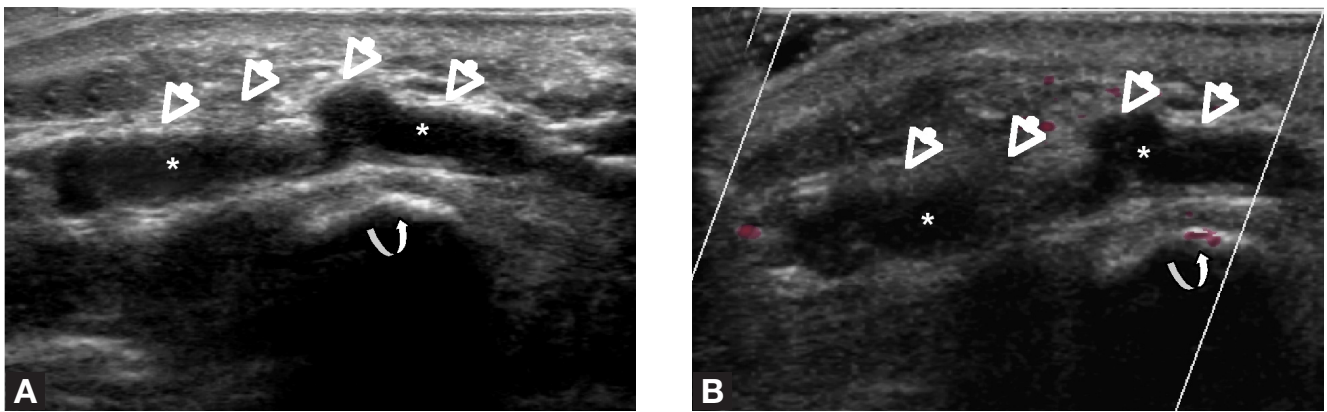


Figure 1. (A) Longitudinal gray scale sonographic image demonstrates echogenic thrombus (asterisks) and aneurysmal “corkscrew” dilatation of the ulnar artery (straight arrows) just distal to the hook of the hamate (curved arrow), reflecting hypothenar hammer syndrome. (B) Longitudinal color Doppler sonographic image shows no flow in the ulnar artery (asterisks) and fusiform “corkscrew” aneurysmal dilatation of the artery (straight arrows) at the hook of the hamate (curved arrow).

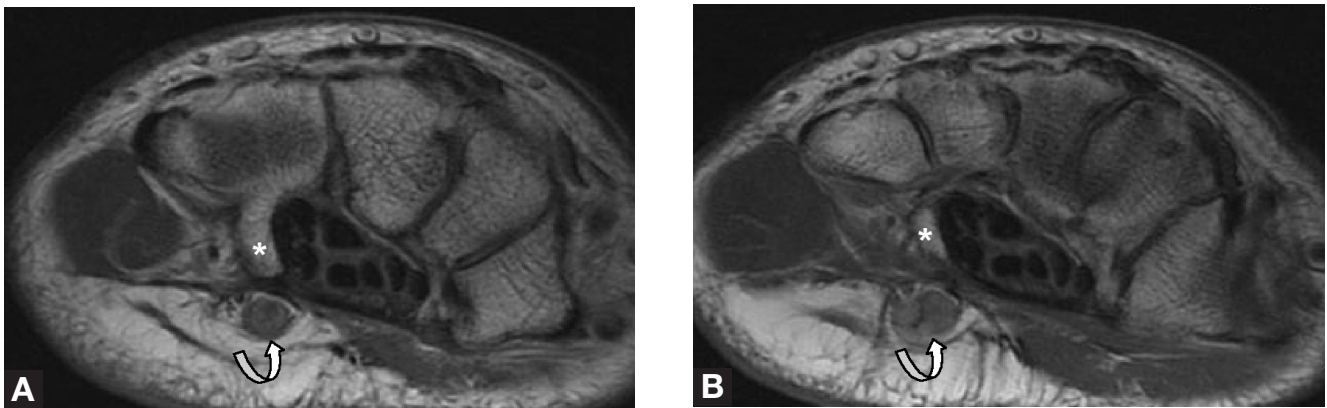


Figure 2. (A, B) Consecutive axial proton density MRIs demonstrate aneurysmal dilatation of the ulnar artery (curved arrows) just distal to the hook of the hamate (asterisks), in a patient with hypothenar hammer syndrome.

the patient or may seem trivial and be overlooked. The medial 3 fingers are typically affected and the thumb and index finger spared.^{2,13} Patients may present with finger claudication, phasic blanching, pain, cyanosis, and paresthesia. Aneurysm may manifest as a pulsatile swelling in the hypothenar region. Ulceration and gangrene of the fingertips is seen in severe cases of ischemia.^{6,7,14}

Physical examination may reveal decreased capillary refill of the ulnar digits. A positive Allen’s test (ie, change in hand color with compression of the radial artery) is suggestive, although a negative result is seen in up to 17% of cases.² The hyperemic flush of Raynaud’s is typically absent.⁷

IMAGING FEATURES

Characteristic cross-sectional imaging features include a “corkscrew” appearance of the diseased ulnar artery segment (resulting from alternating stenosis and ectasia), thrombosis with or without aneurysm, and embolic occlusions of the digital arteries (Figures 1-3).^{4,8} Imaging accurately determines location, morphology, and extent of vascular injury, as well as presence of collaterals.⁶

Conventional angiography is considered the reference standard in distinguishing HHS from other vascular pathologies, but it is not employed as a screening test due to the radiation exposure, as well as the increased risk of vascular injury, bleeding, and iodine allergy.^{2,6} In cases of complete vessel occlusion, angiography cannot distinguish between systemic (ie, cardiac) embolization versus local thrombosis, and cannot visualize ulnar artery aneurysm or corkscrew pattern of HHS.

Gray scale and color Doppler sonography is a useful noninvasive test to evaluate for flow abnormalities, wall irregularity, and aneurysm. It also provides information about the brachial artery for exclusion of thoracic outlet syndrome.^{6,15} Ultrasound can accurately determine the presence, size, and extent of HHS, and identify collateral vessels. At our institution, we use high-frequency transducers (12–15 MHz), which allow for increased resolution and better anatomic detail. The ultrasound probe is placed along Guyon’s canal and the course of the ulnar artery is interrogated using gray scale and color sonography, looking for alterations in intraluminal flow, echogenic intraluminal thrombus, dilatation, and wall irregularity (Figure 1).

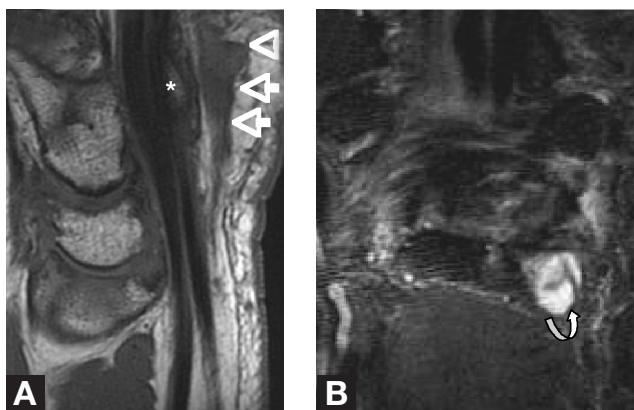


Figure 3. Sagittal proton density (A) and coronal STIR (B) MRI images demonstrate aneurysmal “corkscrew” dilatation of the ulnar artery (straight arrows) just distal to the hook of the hamate (asterisk). On fluid sensitive sequences (B), the aneurysm may be mistake for a complex ganglion cyst (curved arrow).

Computed tomography angiography and magnetic resonance angiography (MRA) are also useful in the evaluation of ulnar artery trauma and have the benefit of being able to identify accessory muscle fibers and ossicles, which may predispose to the condition.⁴ Simultaneous evaluation of both hands with these modalities allows improved assessment of vascular architecture.⁶ MRA alone is unlikely to replace conventional angiography as a stand-alone test since it does not provide comprehensive flow data. However, a complete vascular assessment can be made in conjunction with duplex sonography. Winterer and colleagues¹⁶ evaluated MRA and duplex ultrasound in 5 patients with HHS, concluding that these modalities were sufficient to make the diagnosis in all cases.

MANAGEMENT

HHS can be treated conservatively with avoidance of precipitating activities, smoking cessation, pain control, oral vasodilators, and platelet aggregation inhibitors. In patients with digital necrosis who demonstrate partial response to these agents, intravenous prostacyclin analog therapy has been shown to result in complete healing.^{8,11} When conservative management fails, invasive treatment options include catheter directed thrombolysis, digital, cervical, or thoracic sympathectomy, interposition grafting, and ulnar artery ligation.¹⁷ Catheter directed thrombolysis without subsequent surgery can be performed in cases where the artery is thrombosed but not aneurysmal.¹⁷ Sympathectomy reduces sympathetic tone, promoting the opening of thermoregulatory arteriovenous shunts and collateral circulation, which collectively improve blood flow in the hand. It is not routinely done

at our institution because it has increased postoperative side effects, including dry hand and reflex sweating.¹⁷ Reconstructive surgery with segmental ulnar artery excision and vein grafting is often favored in cases of ulnar artery aneurysm, for fear of recurrent thrombosis and distal embolization.^{1,17}

CONCLUSION

While HHS is a rare condition, it is potentially curable and should be suspected in patients with hand pain and a history of acute or chronic repetitive trauma to the hypothenar eminence.

AUTHORS' DISCLOSURE STATEMENT

The authors report no actual or potential conflict of interest in relation to this article.

REFERENCES

- Nitecki S, Anekstein Y, Karram T, Peer A, Bass A. Hypothenar hammer syndrome: apropos of six cases and review of the literature. *Vascular*. 2008;16(5):279-282.
- Abudakka M, Pillai A, Al-Khaffaf H. Hypothenar hammer syndrome: rare or underdiagnosed? *Eur J Vasc Endovasc Surg*. 2006;32(3):257-260.
- Von Rosen S. Ein Fall von thrombose in der Arteria Ulnaris nach einwirkung von stumpfer gewalt. *Acta Chir Scand*. 1934;73:500-506.
- Müller LP, Rudig L, Kreitner KF, Degreif J. Hypothenar hammer syndrome in sports. *Knee Surg Sports Traumatol Arthrosc*. 1996;4(3):167-170.
- Conn J Jr, Bergan JJ, Bell JL. Hypothenar hammer syndrome: posttraumatic digital ischemia. *Surgery*. 1970;68(6):1122-1128.
- McCready R, Bryant MA, Divilbiss, JL. Combined thenar and hypothenar hammer syndromes: Case report and review of the literature. *J Vasc Surg*. 2008;48(3):741-744.
- Birrer M, Baumgartner I. Images in Clinical Medicine. work-related vascular injuries of the hand—hypothenar hammer syndrome. *N Engl J Med*. 2002;347(5):339.
- Marie I, Hervé F, Primard E, Cailleux N, Levesque H. Long-term follow-up of hypothenar hammer syndrome: a series of 47 patients. *Medicine*. 2007;86(6):334-343.
- Ferris BL, Taylor LM, Oyama K, et al. Hypothenar hammer syndrome: proposed etiology. *J Vasc Surg*. 2000;31(1 pt. 1):104-113.
- Pineda CJ, Weisman MH, Bookstein JJ, Saltzstein SL. Hypothenar hammer syndrome. Form of reversible Raynaud's phenomenon. *Am J Med*. 1985;79(5):561-570.
- Abdel-Gawad EA, Bonatti H, Housseini AM, Maged IM, Morgan RF, Hagspiel KD. Hypothenar hammer syndrome in a computer programmer: CTA diagnosis and surgical and endovascular treatment. *Vasc Endovascular Surg*. 2009;43(5):509-512.
- Modarai B, McIrvine A. The hypothenar hammer syndrome. *J Vasc Surg*. 2008;47(6):1350.
- Sharma R, Ladd W, Chaisson G, Abben R. Images in cardiovascular medicine: Hypothenar hammer syndrome. *Circulation*. 2002;105(13):1615-1616.
- Rankin E, Smith S, Duddy MJ. Hypothenar hammer syndrome in a patient with rheumatoid arthritis: a mimic of vasculitis. *Rheumatology (Oxford)*. 2006;45(2):200.
- Taute BM, Behrmann C, Cappeller WA, Podhaisky H. Ultrasound image of the hypothenar hammer syndrome [in German]. *Ultraschall Med*. 1998;19(5):220-224.
- Winterer J, Ghanem N, Roth M, et al. Diagnosis of the hypothenar hammer syndrome by high-resolution contrast-enhanced MR angiography. *Eur Radiol*. 2002;12(10):2457-2462.
- Dethmers RS, Houpt P. Surgical management of hypothenar and thenar hammer syndromes: A retrospective study of 31 instances in 28 patients. *J Hand Surg Br*. 2005;30(4):419-423.