

# Open Repair of Retracted Latissimus Dorsi Tendon Avulsion

Michael B. Ellman, MD, Adam Yanke, MD, Tristan Juhan, MA, Nikhil N. Verma, MD, Gregory P. Nicholson, MD, Charles Bush-Joseph, MD, and Anthony A. Romeo, MD

## Abstract

Latissimus dorsi avulsion injuries are rarely reported in the literature and are managed with a variety of strategies. Primary anatomical repair of tendon to bone may offer athletes the best chance for successful return to sports.

In this article, we describe a surgical technique for safely repairing an acute or chronic, retracted, avulsed latissimus tendon back to its insertion on the medial aspect of the bicipital groove of the proximal humerus. Using 1 low anterior axillary incision and 1 posterior axillary incision for tendon retrieval when retraction is more than 5 cm, this technique allows for direct anatomical repair of a retracted tendon to bone using 3 points of bony fixation supplemented by soft-tissue repair. The technique also minimizes the risks for neurovascular compromise and cosmetic deformity, while decreasing the risk for postinjury strength deficits.

Latissimus dorsi avulsion injuries from the proximal humerus are rare and occur most often in competitive athletes. The standard of care for this injury is yet to be established. The literature includes only case reports and case series; evidence-based guidelines for appropriate management of this injury are lacking. Most reported cases have occurred in high-level athletes, from water skiers<sup>1,2</sup> and steer wrestlers,<sup>3</sup> to rock climbers<sup>4</sup> and professional baseball pitchers.<sup>5,6</sup> There is no consistency in how these cases were managed. Many authors have suggested that nonoperative treatment is the preferred strategy, even in high-level athletes.<sup>5,6</sup> Other authors have suggested that operative intervention better preserves anatomy, strength, function in high-level athletes, and with unsuccessful

nonoperative treatment, may lead to delayed or limited ability to return to sports.<sup>4,7,8</sup>

For recreational or noncompetitive athletes, nonoperative management of latissimus tears is likely to produce satisfactory outcomes, as the shoulder compensates for loss of latissimus strength and function through the activity of surrounding synergistic muscles. For competitive athletes, however, primary surgical repair may offer the best chance for successful return to sports at a high functional capacity and with few postsurgical strength deficits.

In 2011, Gregory and colleagues<sup>9</sup> examined the surgical repair of subacute latissimus dorsi tendon ruptures using 1 low deltopectoral incision. We subsequently modified and expanded that technique by adding a second, posterior axillary incision to help mobilize and retrieve a retracted tendon (>5 cm retraction), allowing for direct repair of tendon to bone in cases in which the tendon cannot be retrieved through 1 anterior incision. Using 1 low axillary incision and 1 posterior axillary incision for tendon retrieval, this technique allows for anatomical repair of tendon to its insertion on the proximal humerus using 3 points of bony fixation supplemented by soft-tissue repair. Further, the approach minimizes the risks for neurovascular compromise and cosmetic deformity, and decreases the risk for postinjury strength deficits that may occur in nonoperatively treated patients.

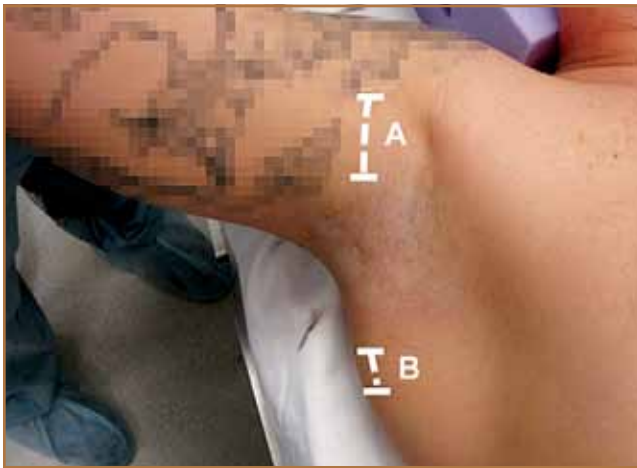## Operative Technique

### Patient Positioning

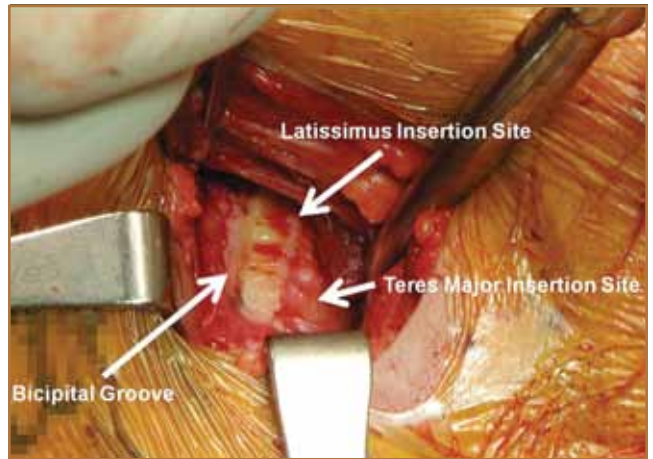
The patient is positioned supine in the semimodified beach-chair position. Care is taken to pad all bony prominences. The patient is brought to the edge of the table on the ipsilateral side of the injury to allow for full shoulder range of motion (ROM) during surgery. Care is taken to include the anterior and posterior aspects of the shoulder within the surgical field to allow for access in the event that a second, posterior axillary incision is required for tendon retrieval. The arm is then

---

**Authors' Disclosure Statement:** Dr. Verma wishes to report board membership with Smith & Nephew, Shoulder Advisory Board, and Vindico Medical Education; consultancy with Smith & Nephew; grant/research support from Arthroscopy Association of North America and Major League Baseball; royalties from Smith & Nephew; stock/stock options from Omeros Corp; and fellowship/research support from Arthrex Inc, Smith & Nephew, Össur, and Linvatec. Dr. Nicholson wishes to report consultation fees from Tornier Inc; and royalty payments from Zimmer Inc. Dr. Bush-Joseph wishes to report institutional support from Smith & Nephew, Arthrex Inc, and DJO LLC; and editorial board membership with the *American Journal of Sports Medicine*. Dr. Romeo wishes to report board membership with *Orthopedics Today*; consultancy with Arthrex Inc; grants/report support with Arthroscopy Association of North America and Major League Baseball; royalties from Arthrex Inc; and institutional research support from DJO Surgical, Össur, Smith & Nephew, and Arthrex Inc. Dr. Ellman, Dr. Yanke, and Mr. Juhan report no actual or potential conflict of interest in relation to this article.



**Figure 1.** Right shoulder of patient in semi-modified beach-chair position with arm abducted and externally rotated. Line A represents primary anterior axillary incision for dissection down to latissimus insertion site on proximal humerus; line B represents secondary incision, if necessary, made directly overlying palpable tendon edge along posterior axillary fold to identify retracted latissimus tendon.



**Figure 2.** View of proximal humerus via anterior axillary incision reveals bare area of latissimus tendon avulsion site.

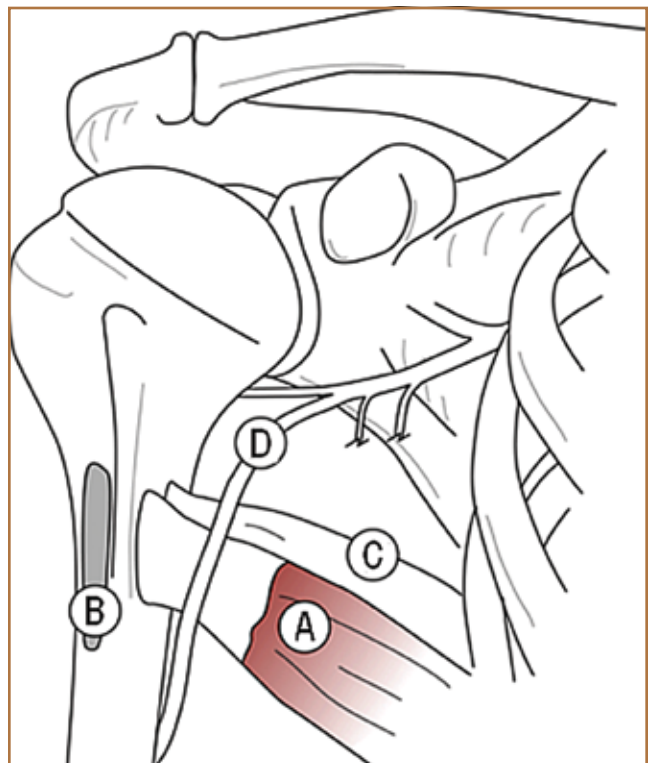
brought into 90° abduction and full external rotation and held by an assistant in preparation for the approach.

### Approach

A 5-cm anterior low axillary incision is made obliquely along Langer's lines in the subpectoral area about 1 cm medial to the bicipital groove and parallel with the axillary fold to avoid scarring and minimize cosmetic deformity (Figure 1, line A). Skin and subcutaneous tissue are incised sharply down to the interval between the pectoralis major and the short head of the biceps. The arm is adducted and externally rotated to allow superior retraction of the pectoralis major using 2 baby Hohmann retractors, maintaining its normal tendinous insertion. The short head of the biceps is then bluntly elevated off the humerus to allow for visualization of the normal latissimus insertion site along the medial border of the bicipital groove, taking care to avoid damage to the radial nerve. The radial nerve need not be identified if it is not encountered during the approach. In clean tendinous avulsion injuries, the insertion site is often bare, with no tendinous tissue remaining (Figure 2).

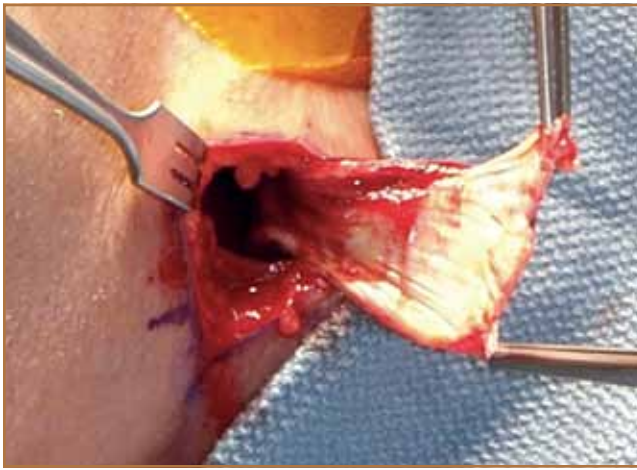
### Tendon Retrieval

The retracted edge of the latissimus tendon is found by identifying the teres major tendon deep to the latissimus insertion site on the medial aspect of the humerus. The surgeon slips a finger over the teres major tendon and traces it proximally and posteriorly in an attempt to retrieve the latissimus tendon from within the axilla. The latissimus tendon should be meticulously exposed from the axilla, as the brachial plexus can be inadvertently injured while pulling on the retracted tendon. The posterior circumflex humeral artery and the axillary

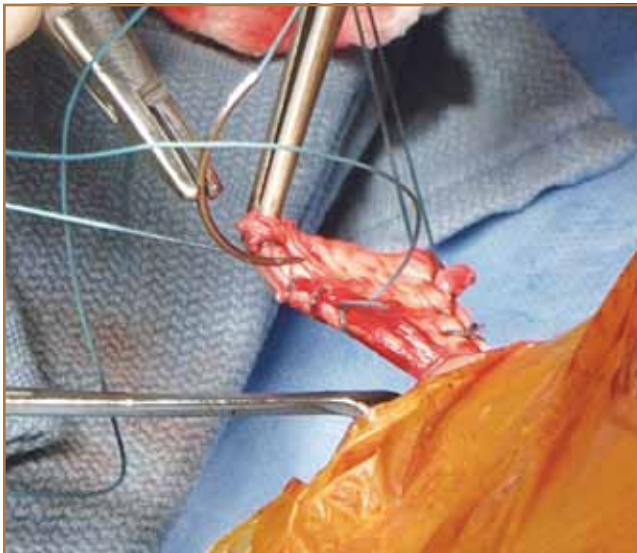


**Figure 3.** Relevant anatomy of proximal humerus: (A) latissimus dorsi muscle inserting onto medial aspect of bicipital groove, (B) pectoralis major insertion footprint, (C) teres major muscle, and (D) radial nerve.

nerve should not be encountered, as they course proximally and posteriorly through the quadrangular space between teres major and minor. If the radial nerve is encountered, care must now be taken to identify and protect it. This nerve, encased in fatty tissue, courses 2- to 3-cm medial to the humerus along the length of the normal latissimus tendon insertion site (Figure 3). An avulsed tendon may allow for visualization of the



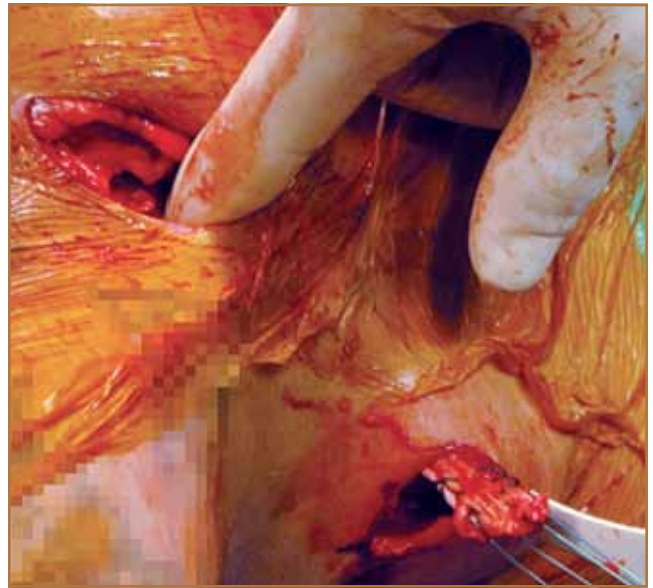
**Figure 4.** Retracted latissimus tendon retrieval from posterior axillary incision status after acute avulsion injury demonstrates clean, smooth tendon edge with minimal fraying.



**Figure 5.** Tendon secured with 2 nonabsorbable sutures running Krackow fashion that are to be used as passing suture.

radial nerve anterior to the teres major. In cases in which the latissimus tendon has retracted only minimally or within 4- to 5-cm of its insertion, and in which the tendon edge is both palpated and visualized, the tendon may be clamped under direct visualization and brought up to the humerus, taking care to avoid incidental clamping of the radial nerve.<sup>9</sup> Bringing the arm into adduction and internal rotation helps decrease the distance between the humerus and the retracted latissimus tendon.

In cases of acute, subacute, or chronic tears with significant retraction (>5 cm), direct visualization of the retracted latissimus tendon is often difficult despite there being a palpable tendon edge. In this scenario, there is concern that blindly clamping the tendon will place at risk the surrounding neurovascular structures, most notably the radial nerve



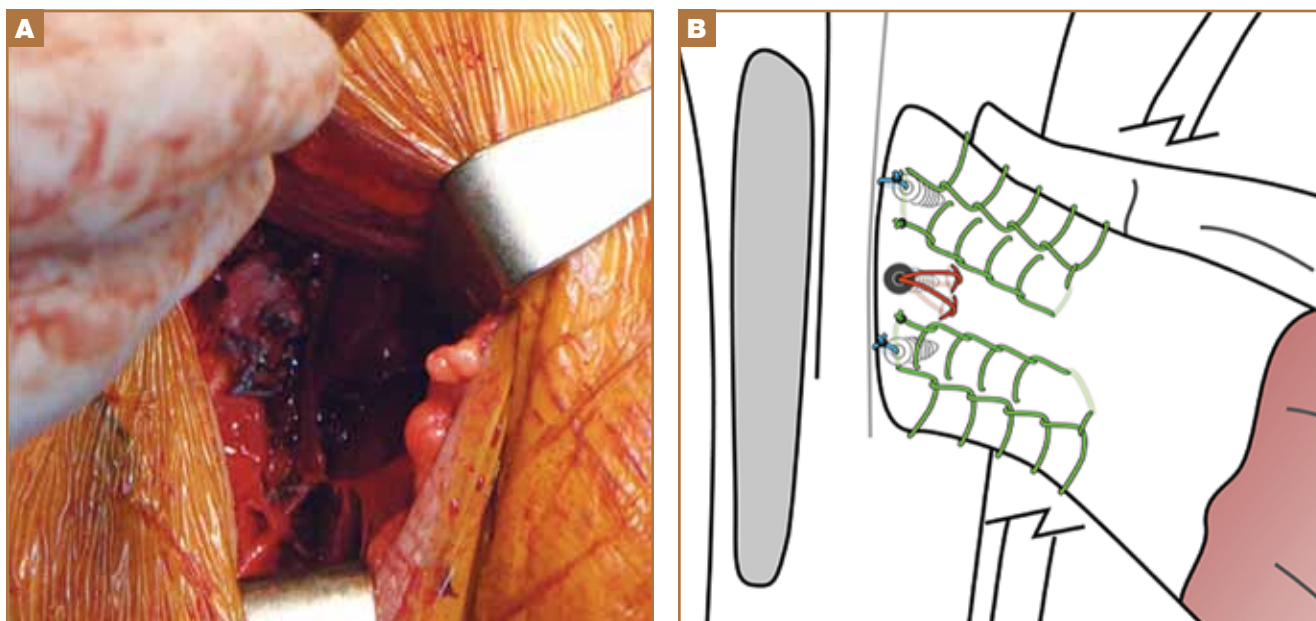
**Figure 6.** Finger is used to create tract between anterior and posterior incisions to facilitate passing of tendon to anterior wound.

as it passes anterior to the teres major tendon medial to the humerus and courses into the triangular interval. Therefore, it is necessary to make a second, posterior axillary incision for tendon retrieval. The arm is brought into an abducted overhead position by an assistant, and the edge of the latissimus tendon is palpated over the skin in the posterior axillary fold. A small, 2- to 3-cm incision is made directly overlying the palpable edge of the latissimus tendon and sharply dissected through the underlying subcutaneous tissue (**Figure 1**, line B). This allows for immediate identification of the latissimus tendon. In cases of acute avulsions, the tendon edge is often in excellent overall condition and has a clean, smooth edge with no fraying (**Figure 4**). In more chronic cases, the tendon may need to be carefully dissected from scar tissue to identify the tendon edge.

The tendon is then secured with 2 strong, nonabsorbable sutures in a running Krackow fashion, that are to be used as a passing suture (**Figure 5**). A finger is used to create a subcutaneous tract between the anterior and posterior axillary incisions (**Figure 6**). A clamp is passed from the anterior incision posteriorly, and the sutures are retrieved, bringing the latissimus tendon into view through the anterior wound.

### Tendon-to-Bone Repair

After the tendon is brought into the anterior axillary wound, the arm is positioned at approximately 10° of abduction and 30° of external rotation, allowing for visualization of the repair site. This position also allows for maintaining minimal tension of the latissimus after reapproximation to its footprint. Before repair, a burr is used to decorticate the bony insertion site to create a bleeding bed for healing. In the present case, we elected to repair the tendon to bone using 3 points of bony fixation with supplemental soft-tissue fixation.



**Figure 7.** Final construct: (A) intraoperative appearance of latissimus tendon repair to insertion site on medial aspect of bicipital groove and (B) anatomical illustration of primary repair with 3-point bony fixation.

Three suture anchors are placed from superior to inferior on the humeral insertion site. Two double-loaded suture anchors are placed, 1 at the superior border of the repair site and 1 at the inferior border. Centrally, a metallic corkscrew anchor is placed. The superior and inferior sutures from the anchors are placed in a running Krackow fashion along the superior and inferior border of the tendon, respectively, and the secondary sutures from each anchor are placed in a simple fashion. The central suture from the corkscrew anchor is placed in a Mason-Allen-type configuration through the central aspect of the latissimus tendon. The superior and inferior sutures are tied to their respective tendinous ends using a tension slide technique, reducing the tendon to bone and maintaining the appropriate insertional anatomy (Figure 7). The middle corkscrew suture is then tied, followed by the teres major horizontal mattress nonabsorbable sutures, to provide excellent apposition of tendon to bone and normal re-creation of the insertion site of the latissimus tendon.

### Closure

The arm is taken through gentle ROM to confirm that the repair is adequate. If the repair is found to be anatomical with appropriate fixation, the wounds are copiously irrigated and closed. For deep closure of the anterior wound, interrupted sutures are placed in the interval between the biceps and the pectoralis major. The subcutaneous layer and skin are closed in the usual fashion. The posterior wound is closed in a similar fashion. The arm is placed in a sling with an abduction pillow.

After surgery, the patient maintains the brace for 4 to 6 weeks. Active and active-assist elbow/hand/wrist ROM exercises begin immediately after surgery. Passive shoulder ROM exercises begin 2 weeks after surgery, while active ROM ex-

ercises begin 5 to 6 weeks after surgery, depending on pain level and progression with physical therapy.

### Discussion

There are few reports of avulsion injuries of the latissimus dorsi tendon. In athletes, these injuries typically present acutely with sudden, severe onset of pain in the upper arm and posterior axilla, often secondary to a hyperabduction injury of the shoulder. In chronic cases, patients may report several months or years of shoulder and/or upper limb discomfort and may present with a visible mass in the axilla.<sup>10</sup>

The management of latissimus avulsion injuries is controversial. Some studies have found successful short-term outcomes with nonoperative management in recreational or non-throwing athletes,<sup>10-12</sup> and other studies have found successful outcomes with operative repair in competitive water skiers,<sup>1,2</sup> professional wrestlers,<sup>13</sup> steer wrestlers,<sup>14</sup> and rock climbers.<sup>4</sup> Schickendantz and colleagues<sup>5</sup> were the first to report 5 cases of nonoperatively treated acute latissimus avulsion injuries in professional baseball pitchers. These athletes returned to pitching within 1 year, and there was 1 re-rupture of the latissimus tendon after 6 months. Recently, Nagda and colleagues<sup>6</sup> retrospectively reviewed 16 cases of professional baseball pitchers with latissimus or teres major injuries diagnosed and nonoperatively treated over a 6-year period. Fifteen of these 16 pitchers (94%) successfully returned to play, with a mean time to throwing of 35.6 days, suggesting that nonoperative treatment of latissimus and teres major injuries is successful in allowing professional pitchers to return to high-level activity. However, only 2 of the 16 cases (13%) involved isolated latissimus avulsion injuries—the other 14 were isolated teres major injuries, combination injuries, or muscle strains—and

1 of the 2 athletes sustained another injury, a teres major avulsion, 13 months after the primary latissimus rupture. Further, return-to-throwing outcomes were worse for these 2 patients than for those with isolated teres major tears or muscle strains. Therefore, for pitchers with isolated, acute latissimus avulsions, outcomes may be less satisfactory with nonoperative treatment than with operative management.

One potential reason for less than optimal outcomes after nonoperative management of latissimus avulsions may be a significant strength deficit after injury, most notably with shoulder extension and adduction. The literature is replete with studies documenting loss of latissimus muscle strength after takedown for use as a free or pedicle flap in reconstructive surgery.<sup>15-17</sup> Muscle strength deficits of up to 20% compared with the contralateral side, along with significant isokinetic weakness of shoulder extension, adduction, and peak torque values, have been reported after latissimus takedown.<sup>15-17</sup> While functional deficits after latissimus avulsions may go unnoticed in noncompetitive or recreational athletes, these deficits may be more pronounced in competitive athletes with high functional shoulder demands.

Another disadvantage of nonoperative repair of latissimus avulsion injuries is the potential for precluding anatomical restoration of the tendon at a later date, if, for example, the patient has become dissatisfied with nonoperative treatment. Cox and colleagues<sup>18</sup> reported good outcomes with surgical repair of 2 subacute (>6 weeks) latissimus dorsi tendon ruptures through a 1-incision posterior axillary approach, but they suggested that surgical intervention beyond 2 months after injury could preclude anatomical restoration of the tendon,<sup>18</sup> most likely because of tendon retraction and subsequent scar tissue buildup. As a result, some authors have advocated for early anatomical repair,<sup>7-9,13</sup> whereas others may choose to manage latissimus ruptures in a conservative manner initially and, if that fails, proceed to delayed repair or reconstruction. To date, however, the standard of care for this injury remains controversial.

Previous case reports have described a variety of approaches and techniques for surgical repair of latissimus tendon avulsions. Henry and Scerpella<sup>1</sup> reported the case of a water skier with an acutely avulsed latissimus dorsi muscle surgically repaired with use of 1 axillary incision and then drilling of transosseous humeral tunnels to secure tendon to bone. Livesey and colleagues<sup>4</sup> reported the case of a rock climber with a chronic latissimus tear (>2 years after injury) managed with use of 2 incisions (anterior deltopectoral, posterior axillary) facilitating repair with transosseous tunnels. Hapa and colleagues<sup>13</sup> described using 2 anterior axillary incisions (with patient in semi-beach-chair position) for fixation of tendon to bone using suture anchors. Hiemstra and colleagues<sup>3</sup> and Lim and colleagues<sup>2</sup> used 1 posterior axillary incision (patients in lateral decubitus position) and repaired the tendon with suture anchors. Although suture anchors have demonstrated superior failure strength to bone tunnel fixation in a cadaveric model for repair of distal biceps tendons,<sup>19</sup> and are routinely used in the clinical repair of pectoralis major,<sup>20</sup> distal biceps,<sup>21</sup> and

proximal hamstring muscle avulsions,<sup>22</sup> no study to date has directly compared suture anchors with bone tunnel fixation for latissimus tendon repair.

In acute, subacute, and chronic avulsions in high-level athletes with retraction of less than 4 cm, we attempt to primarily repair tendon to bone using 1 low anterior deltopectoral approach.<sup>9</sup> In cases with significant tendon retraction (>4-5 cm), however, a second posterior axillary incision is often needed to mobilize and retrieve the tendon. In the present article, we have provided a detailed technique guide that can be an aid in direct primary repair of retracted latissimus avulsion injuries. Use of 1 low anterior axillary incision—and, if needed, 1 small posterior axillary incision for tendon retrieval—is a cosmetically acceptable approach with minimal risk for axillary irritation from any scar/keloid formation that might develop.

From a technical standpoint, direct anatomical repair of the latissimus tendon to bone requires a thorough understanding of the anatomy (Figure 3). According to cadaveric studies, the radial nerve lies about 2 to 3 cm medial to the humerus along the length of the latissimus tendon.<sup>23</sup> Internal rotation and adduction of the humerus bring an avulsed latissimus dorsi tendon closer to the humerus, but the radial nerve may become visible in the field as well, placing it at highest risk for injury during the approach. If the radial nerve is visualized, it should be protected and retracted. However, if the nerve is not directly visualized, the surgeon need not explore or search for it, in our opinion. In contrast, the axillary nerve is proximal to the latissimus tendon as it courses through the quadrangular space a mean of 1.4 cm proximal to the superior edge of the teres major,<sup>23</sup> which is superior to the latissimus dorsi tendon at this level and should not enter the operative field during surgery. The thoracodorsal neurovascular bundle inserts on the anterior muscle belly of the latissimus dorsi at a mean of 13.1 cm medial to its humeral insertion<sup>23</sup> and, similar to the axillary nerve, should not be in danger during our approach.

This technique is a safe and reproducible method for retrieving an avulsed, retracted latissimus tendon. Use of 3 suture anchors allows for anatomical reconstruction of tendon to bone with excellent cortical fixation and normal re-creation of the insertion site of the latissimus tendon. For competitive athletes who have high functional shoulder demands and sustain acute, subacute, or chronic retracted latissimus avulsion tears that cannot be retrieved through 1 incision, this technique allows for direct anatomical repair of the avulsed tendon to bone, facilitates direct bone-to-tendon healing, minimizes the risk for neurovascular compromise and cosmetic deformity, and decreases the risk for the postinjury strength deficits that may occur in nonoperatively treated patients.

## Conclusion

Given the vital function of the latissimus dorsi muscle in competitive throwers, anatomical reconstruction theoretically offers the highest chance of return to preinjury functional levels

while minimizing risk for strength deficits. In this article, we have described a surgical technique for safely repairing an acute or chronic, retracted (>4-5 cm), avulsed latissimus tendon back to its insertion on the medial aspect of the bicipital groove of the proximal humerus. With use of 1 low axillary incision and 1 posterior axillary incision for tendon mobilization and retrieval, the latissimus tendon can be mobilized, retrieved, and repaired to bone using 3 points of bony fixation supplemented by soft-tissue repair, while minimizing the risk for neurovascular compromise and cosmetic deformity and decreasing the risk for the postinjury strength deficits that may occur in nonoperatively treated patients.

Dr. Ellman and Dr. Yanke are Residents, Department of Orthopaedic Surgery, Rush University Medical Center, Chicago, Illinois. Mr. Juhan is Research Coordinator, Midwest Orthopaedics at Rush, Chicago, Illinois. Dr. Verma and Dr. Nicholson are Assistant Professors, Department of Orthopaedic Surgery, Rush University Medical Center, Chicago, Illinois. Dr. Bush-Joseph is Professor, Department of Orthopaedic Surgery, Rush University Medical Center, Chicago, Illinois; Head Team Physician, Chicago White Sox; and Associate Team Physician, Chicago Bulls. Dr. Romeo is Professor and Section Chairman of Shoulder and Elbow Surgery, Division of Sports Medicine, Department of Orthopaedic Surgery, Rush University Medical Center, Chicago, Illinois; and Team Physician, Chicago White Sox.

Address correspondence to: Michael B. Ellman, MD, Department of Orthopedic Surgery, Rush University Medical Center, Chicago, IL 60612 (tel, 734-604-4151; fax, 708-492-5452; e-mail, mikeellman@gmail.com).

*Am J Orthop.* 2013;42(6):280-285. Copyright Frontline Medical Communications Inc. 2013. All rights reserved.

## References

- Henry JC, Scerpella TA. Acute traumatic tear of the latissimus dorsi tendon from its insertion. A case report. *Am J Sports Med.* 2000;28(4):577-579.
- Lim JK, Tilford ME, Hamersly SF, Sallay PI. Surgical repair of an acute latissimus dorsi tendon avulsion using suture anchors through a single incision. *Am J Sports Med.* 2006;34(8):1351-1355.
- Hiemstra LA, Butterwick D, Cooke M, Walker RE. Surgical management of latissimus dorsi rupture in a steer wrestler. *Clin J Sport Med.* 2007;17(4):316-318.
- Livesey JP, Brownson P, Wallace WA. Traumatic latissimus dorsi tendon rupture. *J Shoulder Elbow Surg.* 2002;11(6):642-644.
- Schickendantz MS, Kaar SG, Meister K, Lund P, Beverley L. Latissimus dorsi and teres major tears in professional baseball pitchers: a case series. *Am J Sports Med.* 2009;37(10):2016-2020.
- Nagda SH, Cohen SB, Noonan TJ, Raasch WG, Ciccotti MG, Yocum LA. Management and outcomes of latissimus dorsi and teres major injuries in professional baseball pitchers. *Am J Sports Med.* 2011;39(10):2181-2186.
- Levine JW, Savoie FH 3rd. Traumatic rupture of the latissimus dorsi. *Orthopedics.* 2008;31(8):799-801.
- Park JY, Lhee SH, Keum JS. Rupture of latissimus dorsi muscle in a tennis player. *Orthopedics.* 2008;31(10).
- Gregory JM, Harwood DP, Sherman SL, Romeo AA. Surgical repair of a subacute latissimus dorsi tendon rupture. *Techniques Shoulder Elbow Surg.* 2011;12(4):77-79.
- Anderson SE, Hertel R, Johnston JO, Stauffer E, Leinweber E, Steinbach LS. Latissimus dorsi tendinosis and tear: imaging features of a pseudotumor of the upper limb in five patients. *AJR Am J Roentgenol.* 2005;185(5):1145-1151.
- Butterwick DJ, Mohtadi NG, Meeuwisse WH, Frizzell JB. Rupture of latissimus dorsi in an athlete. *Clin J Sport Med.* 2003;13(3):189-191.
- Spinner RJ, Speer KP, Mallon WJ. Avulsion injury to the conjoined tendons of the latissimus dorsi and teres major muscles. *Am J Sports Med.* 1998;26(6):847-849.
- Hapa O, Wijdicks CA, LaPrade RF, Braman JP. Out of the ring and into a sling: acute latissimus dorsi avulsion in a professional wrestler: a case report and review of the literature. *Knee Surg Sports Traumatol Arthrosc.* 2008;16(12):1146-1150.
- Gowan ID, Jobe FW, Tibone JE, Perry J, Moynes DR. A comparative electromyographic analysis of the shoulder during pitching. Professional versus amateur pitchers. *Am J Sports Med.* 1987;15(6):586-590.
- Brumback RJ, McBride MS, Ortolani NC. Functional evaluation of the shoulder after transfer of the vascularized latissimus dorsi muscle. *J Bone Joint Surg Am.* 1992;74(3):377-382.
- Fraulin FO, Louie G, Zorrilla L, Tilley W. Functional evaluation of the shoulder following latissimus dorsi muscle transfer. *Ann Plast Surg.* 1995;35(4):349-355.
- Russell RC, Pribaz J, Zook EG, Leighton WD, Eriksson E, Smith CJ. Functional evaluation of latissimus dorsi donor site. *Plast Reconstr Surg.* 1986;78(3):336-344.
- Cox EM, McKay SD, Wolf BR. Subacute repair of latissimus dorsi tendon avulsion in the recreational athlete: two-year outcomes of 2 cases. *J Shoulder Elbow Surg.* 2010;19(6):e16-e19.
- Lemoms SE, Ebramzadeh E, Kvitne RS. A new technique: in vitro suture anchor fixation has superior yield strength to bone tunnel fixation for distal biceps tendon repair. *Am J Sports Med.* 2004;32(2):406-410.
- Miller MD, Johnson DL, Fu FH, Thaete FL, Blanc RO. Rupture of the pectoralis major muscle in a collegiate football player. Use of magnetic resonance imaging in early diagnosis. *Am J Sports Med.* 1993;21(3):475-477.
- Lintner S, Fischer T. Repair of the distal biceps tendon using suture anchors and an anterior approach. *Clin Orthop.* 1996;(322):116-119.
- Klinge KE, Sallay PI. Surgical repair of complete proximal hamstring tendon rupture. *Am J Sports Med.* 2002;30(5):742-747.
- Pearle AD, Kelly BT, Voos JE, Chehab EL, Warren RF. Surgical technique and anatomic study of latissimus dorsi and teres major transfers. *J Bone Joint Surg Am.* 2006;88(7):1524-1531.

---

*This paper will be judged for the Resident Writer's Award.*

---