

A Simple Wrist Arthroscopy Tower: The Wrist Triangle

Shafic A. Sraj, MD

Abstract

Several wrist arthroscopy towers are commercially available. In this report, the use of a triangular holder as a cheap, mobile, radiolucent tower for wrist arthroscopy is described, which can be useful in a cost-conscious surgical practice.

assist in leg positioning for intramedullary nailing, to provide a stable support of the forearm, fits easily on the arm table, requires no or minimal assistance to hold in place, and allows intraoperative fluoroscopy (Figure 1A). It allows access to all standard dorsal radiocarpal and midcarpal portals. It is frequently available in the general orthopedic operating suite, and, if not, it is cheap, priced in the range of a few hundred dollars for a set of 3 sizes. It is a reusable instrument, and sterilized similar to other surgical instruments.

Surgical Technique

The patient is placed supine on the operating table and a tourniquet is placed on the operative upper arm for later use as needed.

The arm is secured to the hand table. The forearm, wrist, and hand are prepared from the elbow distally. Finger traps are placed on the fingers to the surgeon's choice. An appropriate-size triangle, which has been previously sterilized in a standard fashion, is introduced into the field. It should be longer than the forearm. A medium size triangle usually fits almost all forearms.

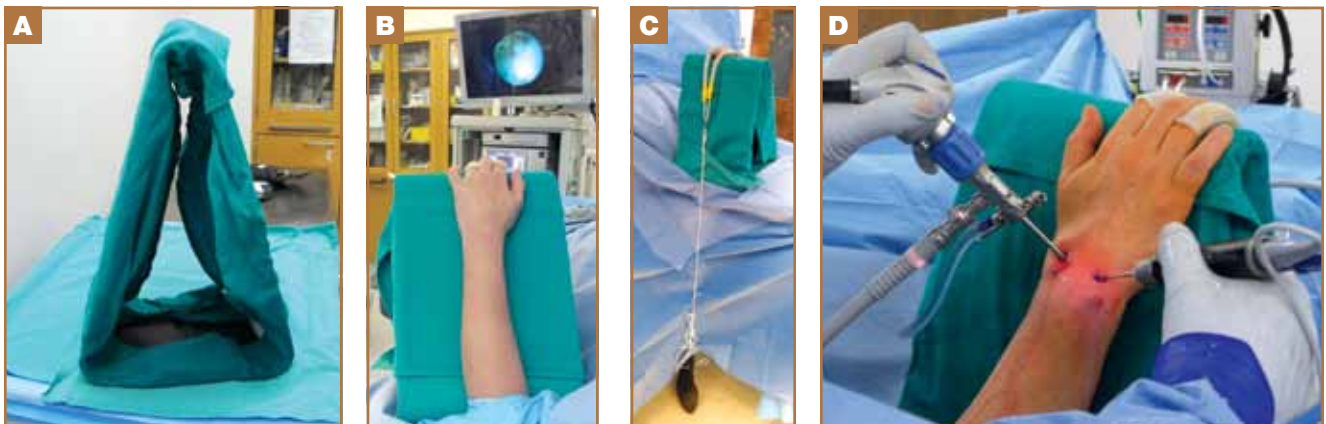
A towel is wrapped around the triangle to help steady the wrist and maintain its position. The fingers are allowed to curve over the top of the triangle. The traps are pulled towards the floor via rope attached to appropriate weight, typically 2

Wrist arthroscopy is a common procedure. It requires forearm and wrist support and is frequently combined with traction. For the advanced arthroscopist, the use of intraoperative fluoroscopy may be required as well. When first described, the hand was suspended from an intravenous pole using finger traps. Later, dedicated wrist traction towers were developed.¹⁻³

In an orthopedic practice not dedicated to hand and wrist surgery, less expensive alternatives are always welcome. Current wrist arthroscopy towers allow forearm support, circumferential access, and fluoroscopy. Less expensive alternatives include the use of a shoulder traction boom, when already available in operating suites.⁴

The use of a triangular leg holder, frequently used to as-

Figure 1. A medium radiolucent leg holder, covered with sterile towels (A). Dorsal (B) and palmar (C) views showing the forearm positioned and suspension applied; commencement of arthroscopy (D).



Author's Disclosure Statement: The author reports no actual or potential conflict of interest in relation to this article.

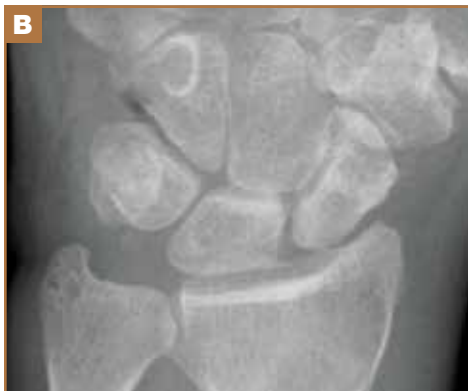
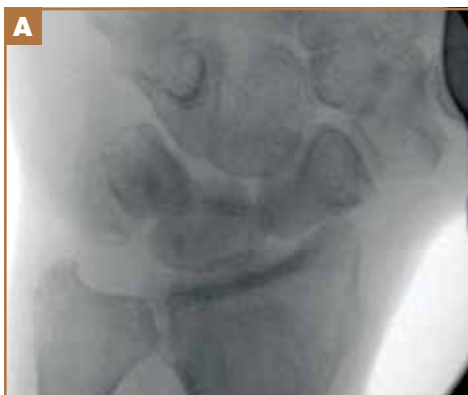
Figure 2. Intraoperative fluoroscopic image (A) taken through the triangle, compared with standard intraoperative plain radiograph (B) taken in the same position.

kg-4 kg. The weights are allowed to hang just above ground level (Figure 1B-1D). Once the setup is complete, the wrist can be positioned in neutral, ulnar, or radial deviation.

Discussion

I have used this technique for the past 2 years with no difficulty. I prefer a solid surface to lay the forearm to minimize motion during arthroscopy over suspending the forearm in space. With this setup, both plain radiography and fluoroscopy are possible (Figure 2A, 2B).

To obtain standard anteroposterior view, the C-arm should be tilted to match the inclined surface of the triangle. Should the position of the triangle or the desired traction need to be adjusted, it can easily be done by lifting the fingers off the top of the triangle. The wrist maintains its position well in neutral, ulnar, and radial deviation.

I have not encountered any complications related to the use of the triangle. To my knowledge, no similar technique has previously been described.

Dr. Sraj is Hand Surgeon, Stonewall Jackson Memorial Hospital, Weston Medicine Center, West Virginia.

Address correspondence to: Shafic A. Sraj, MD, Weston Orthopedic and Sports Medicine Center, 29 hospital plaza Suite C, Weston, WV 26452 (tel, 304-269-4431; fax, 304-269-9803; e-mail, shaficsrajmd@gmail.com).

References

1. Palmer AK, Poehling GG, Viegas SF, Whipple TL. Wrist arthroscopy. *Contemp Orthop.* 1991;22(5):565-601.
2. Easterling KJ, Wolfe SW. Wrist arthroscopy: an overview. *Contemp Orthop.* 1992;24(1):21-30.
3. Van Heest AE: Wrist arthroscopy. *Scand J Med Sci Sports.* 1995;5(1):2-6.
4. Budoff JE, Gordon L. Wrist arthroscopy using a shoulder traction boom. *Am J Orthop (Belle Mead NJ).* 2008;37(12):614-615.

Erratum

In the original study, “Synergistic Effect of Using a Transcutaneous Electrical Joint Stimulator and an Unloading Brace in Treating Osteoarthritis of the Knee,” (*Am J Orthop.* 2013;42(10):456-460) an error occurred in the legend of Figure 8. The legend should have shown: BioniCare in green and Control Group in blue.

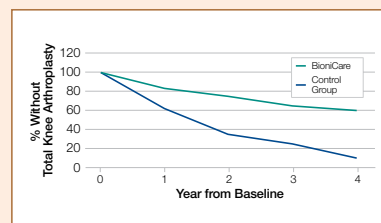


Figure 8. Percentage of 103 patients who were treated with BioniCare stimulator for 11 months (vs 42 matched controls) and who deferred total knee arthroplasty by year.