

# Pregnant and catatonic

Dante Durand, MD, FAPA, Vasthie Prudent, MD, Aliye Runyan, MD, and Jorge Luis Sotelo, MD, FAPM, FAPA



## How would you handle this case?

Visit [CurrentPsychiatry.com](http://CurrentPsychiatry.com) to input your answers and see how your colleagues responded

Mrs. K, age 42 and 31 weeks pregnant, presents with progressive mutism and psychomotor retardation. How would you treat her?

### **CASE** Mute and unresponsive

Mrs. K, a 42-year-old Haitian who is 31 weeks pregnant, presents with a 4-week history of progressive mutism and psychomotor retardation. At inpatient admission, she is awake and alert but does not speak and resists the treatment team's attempts to engage her. Mrs. K's eyes are open, but she has a vacant stare and avoids eye contact. Her affect is flat and nonreactive and she appears internally preoccupied. Mrs. K exhibits motoric immobility, displays a rigid posture, and resists attempts to get her to move. Features of catatonic excitement, echo phenomena, posturing, stereotypies, and mannerisms are absent during the initial evaluation.

Mrs. K's husband reports that they had been on vacation for 6 days before he brought her for psychiatric evaluation. He denies any recent evidence of psychosis or mood disturbance, stating that his wife was excited when she learned of the pregnancy, and attended all prenatal appointments. He reports that when this episode began, Mrs. K stopped talking to her 3-year-old daughter, did not respond to her name, and did not pay attention to those around her.

According to her husband, a similar episode occurred 2 years earlier, during which Mrs. K was selectively mute for approximately 1 month. She did not eat for 5 days and neglected the care of her daughter. There were 2 additional

brief periods of prominent psychomotor retardation for which she was hospitalized in Haiti. According to the patient's aunt, Mrs. K complained that her husband had cast a "voodoo spell" on her because he wanted sole custody of their daughter. Her husband recounted an episode, when they lived in Haiti, during which his wife became paranoid, left the house, and wandered the streets for 2 days.

The medical history is significant for a cervical polyp that was removed 2 years ago. Mrs. K has no history of substance abuse. She was born and raised in Haiti where she studied medicine. Her family reports that Mrs. K's husband is "controlling," which causes her distress.

### Which is the most likely diagnosis for Mrs. K?

- a) major depressive disorder, severe with psychosis, with catatonia
- b) schizophrenia, with catatonia
- c) conversion disorder, with catatonia
- d) bipolar I disorder, with psychosis and catatonia

Dr. Durand is Assistant Professor of Psychiatry, Dr. Prudent is a Third-Year Psychiatry Resident, Dr. Runyan is Education and Research Fellow for the American Medical Student Association, and Dr. Sotelo is Assistant Professor of Psychiatry, University of Miami Miller School of Medicine, Miami, Florida.

### Disclosures

Dr. Runyan receives grant support from Lippincott, Williams, & Wilkins. Drs. Durant, Prudent, and Sotelo report no financial relationships with any company whose products are mentioned in this article or with manufacturers of competing products.

Table 1

## DSM-5 diagnostic criteria for catatonia

The clinical picture is dominated by 3 (or more) of the following symptoms:

1. Stupor (ie, no psychomotor activity; not actively relating to environment)
2. Catalepsy (ie, passive induction of a posture held against gravity)
3. Waxy flexibility (ie, slight, even resistance to positioning by examiner)
4. Mutism (ie, no, or very little, verbal response [exclude if known aphasia])
5. Negativism (ie, opposition or no response to instructions or external stimuli)
6. Posturing (ie, spontaneous and active maintenance of a posture against gravity)
7. Mannerism (ie, odd, circumstantial caricature of normal actions)
8. Stereotypy (ie, repetitive, abnormally frequent, non-goal-directed movements)
9. Agitation, not influenced by external stimuli
10. Grimacing
11. Echolalia (ie, mimicking another's speech)
12. Echopraxia (ie, mimicking another's movements)

Source: Reference 2

### The authors' observations

Catatonia is a neuropsychiatric syndrome that can occur in schizophrenia, mood disorders, mental retardation, neurologic disease, metabolic conditions, and drug intoxication.<sup>1</sup> Catatonia can present in several ways, from catatonic stupor to extreme purposeless agitation; more than 60 catatonic signs and symptoms have been described.<sup>1</sup> According to DSM-5<sup>2</sup> catatonia is characterized by 3 or more of the following symptoms:

- stupor
- catalepsy
- waxy flexibility
- mutism
- negativism
- posturing
- mannerism
- stereotypy
- agitation, not influenced by external stimuli
- grimacing
- echolalia
- echopraxia.

Mrs. K exhibited stupor, mutism, posturing, and grimacing (*Table 1*).<sup>2</sup> We thought that her catatonic features were secondary to schizophrenia because she

had paranoid delusions and displayed disorganized behavior while in Haiti. There was no evidence of past or current mood disorder, metabolic condition, neurologic illness, or substance abuse.

### Catatonia and pregnancy

There is little available information to guide clinicians who are treating a pregnant woman who has a catatonic syndrome. Espinola-Nadurille and co-workers described a 22-year-old pregnant (21 weeks) woman from rural Mexico who was hospitalized with agitation, disorganized speech, restlessness, and hallucinations after several weeks of alternating agitation and withdrawal with mutism and refusal to eat or drink.<sup>3</sup> This patient developed malignant catatonia with creatine phosphokinase elevation and leukocytosis and eventually responded to treatment with lorazepam and electroconvulsive therapy (ECT). She was given a diagnosis of schizophreniform disorder. Treating her catatonic symptoms did not result in any adverse effects on the pregnancy or the fetus.

Exacerbation of schizophrenia during pregnancy can lead to neglect of preg-

### Clinical Point

Catatonia can occur in schizophrenia, mood disorders, mental retardation, neurologic disease, metabolic conditions, and drug intoxication



Discuss this article at  
[www.facebook.com/CurrentPsychiatry](http://www.facebook.com/CurrentPsychiatry)

### Clinical Point

Exacerbation of schizophrenia can lead to neglect of pregnancy and prenatal care, harm to the fetus, and risk of preterm delivery

**Table 2**

## Medical complications of catatonia

### Venous thromboembolism

Study	Study design (N)	Outcome
Larsen et al 2011 <sup>6</sup>	Case report (1)	Pulmonary embolism/death
Lachner et al 2003 <sup>7</sup>	Case report (1)	Deep venous thrombosis
Morioka et al 1997 <sup>8</sup>	Case report (2)	Deep venous thrombosis

### Nutritional deficiency

Study	Study design (N)	Outcome
Nomoto et al 2011 <sup>9</sup>	Case report (1)	Vitamin K deficiency
Gross et al 2008 <sup>5</sup>	Case report/review (1)	Hypoalbuminemia

### Pressure ulcers

Study	Study design (N)	Outcome
Srivastava et al 2009 <sup>10</sup>	Case report (1)	Decubitus ulcers
Gross et al 2008 <sup>5</sup>	Case report/review (1)	Decubitus ulcers

nancy and prenatal care,<sup>4</sup> imminent harm to the fetus because of malnutrition and dehydration, and risk of preterm delivery and low weight at birth. Prolonged catatonia can cause medical complications such as decubitus ulcers, incontinence, recurrent urinary tract infections, aspiration pneumonia, increased risk of deep venous thrombosis, malnutrition, and ocular complications because of prolonged staring and reduced blinking (*Table 2*<sup>5-10</sup>). For these reasons, it is important to treat this condition early and aggressively to improve pregnancy outcome and infant well-being.

### Which rating scale would you use to monitor the severity of Mrs. K's symptoms?

- Positive and Negative Symptom Scale
- The Northoff Catatonia Rating Scale
- The Bush-Francis Catatonia Rating Scale (BFCRS)
- The Rogers Catatonia Scale

### EVALUATION Flat affect

The mental status examination on admission describes a tall, black, Haitian woman with unkempt hair and fair hygiene. Mrs. K has a

prominent abdomen, consistent with a 31-week pregnancy. She exhibits a blank stare without direct eye contact; she is mute, and exhibits flat affect. We cannot evaluate her thought processes and content because Mrs. K is mute, although she does appear internally preoccupied.

Physical examination on admission is unremarkable; vital signs are stable and within normal limits. Laboratory work-up reveals a urinary tract infection, which is treated with ceftriaxone. Mrs. K also has macrocytic anemia (hemoglobin, 11.7 g/dL; hematocrit, 34.7%; mean corpuscular volume, 99.2  $\mu\text{m}^3$ ). Albumin is low at 2.6 g/dL. Urine drug toxicology screen is negative. Fingertick glucose reading is 139 mg/dL. Mrs. K is given a presumptive diagnosis of schizophrenia with catatonia.

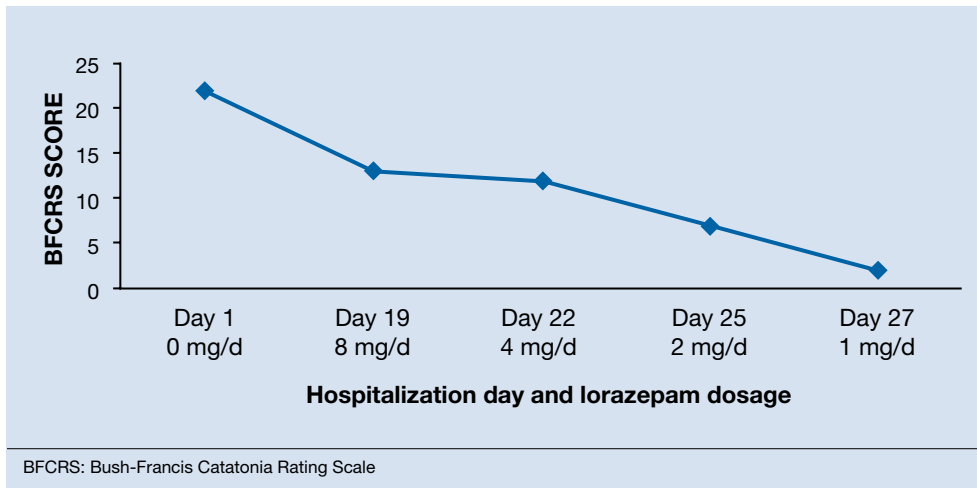
Mrs. K's BFCRS<sup>11</sup> score is 22 at admission. She is mute, holds postures for longer than a minute, and is resistant to repositioning. She also has extreme hypoactivity and does not interact with others. She has a fixed, blank stare, and exhibits mild grimacing.

### The authors' observations

BFCRS defines each catatonic sign, rates its severity, and provides a standardized

## Figure

## Correlation of Mrs. K's BFCRS score and lorazepam dosage



schema for clinical examination.<sup>11</sup> The BFCRS is preferred for routine use because of its validity, reliability, and ease of administration.<sup>12</sup> The treatment team rated Mrs. K at admission, during the course of treatment, and at discharge, showing a substantial improvement at the end of the hospitalization (*Figure*).

#### How would you manage Mrs. K's catatonic symptoms?

- ECT
- lorazepam
- haloperidol
- olanzapine

#### The authors' observations

Benzodiazepines (particularly lorazepam) and ECT are considered the treatment of choice for catatonic symptoms.<sup>11</sup> More than 72% of patients with catatonic symptoms remit after a trial of a benzodiazepine.<sup>1</sup> ECT is considered when patients do not respond to a benzodiazepine after 48 to 72 hours.<sup>3</sup> Several cases of complete resolution of catatonic symptoms have been linked to ECT (*Table 3*).<sup>13-18</sup>

A recent retrospective review revealed that patients who do not respond to

lorazepam are more likely to come from a rural setting, have a longer duration of illness, exhibit mutism, and exhibit third-person auditory hallucinations and made phenomena (the feeling that some aspect of the individual is under the external control of others).<sup>19</sup> Case reports of treatment of catatonic patients with ECT vs lorazepam are listed in *Table 3*.<sup>13-18</sup>

In pregnancy, ECT can be considered early in the course of illness. A review of the literature on ECT during pregnancy reported at least partial remission in 78% of studies reporting efficacy data.<sup>20</sup> Among these 339 patients, there were 25 fetal or neonatal complications—only 11 of these were related to ECT—and 20 maternal complications, of which 18 were related to ECT. The authors of this review concluded that 1) ECT is an effective treatment for severe mental illness during pregnancy and 2) the risks to fetus and mother are low.

A 2007 study identified 1,979 infants whose mothers reported use of benzodiazepines or hypnotic benzodiazepine-receptor agonists during early pregnancy.<sup>21</sup> An additional 401 infants born to mothers who were prescribed these medications during late pregnancy also were included

#### Clinical Point

A literature review indicates ECT is an effective treatment for severe mental illness during pregnancy with low risk to mother and fetus

Table 3

## Evidence supporting catatonia treatments

## Electroconvulsive therapy

Study	Study design	Outcome: Complete resolution
Raveendranathan et al 2011 <sup>15</sup>	Retrospective	56/63
Zisselman et al 2010 <sup>13</sup>	Case report	1/1
Rohland et al 1993 <sup>14</sup>	Retrospective	26/28

## Lorazepam

Study	Study design	Outcome: Complete resolution
Huang 2005 <sup>18</sup>	Prospective	12/14
Payee et al 1999 <sup>16</sup>	Prospective	21/30
Bush et al 1996 <sup>17</sup>	Prospective	16/21

## Clinical Point

Antipsychotics have been used to treat catatonic symptoms; however, the efficacy and safety of these agents remains largely unknown

in this study. Women who took these medications were at an increased risk for preterm birth and low birth weight. The rate of congenital malformations in this study was moderately increased among infants exposed in early pregnancy (adjusted odds ratio = 1.24 [95% confidence interval, 1.00 to 1.55]).

Because catatonic symptoms can appear during the course of schizophrenia, several antipsychotics have been used to treat this condition. The efficacy and safety of antipsychotics for treating catatonia remains largely unknown, however.<sup>1</sup>

**OUTCOME Recovery, baby girl**

We begin oral haloperidol, 10 mg/d, for Mrs. K, which we then increase to 20 mg/d. Because she shows little response to haloperidol, we suggest a trial of ECT, but her husband refuses to consent. She is started on IM lorazepam, 6 mg/d.

Mrs. K gradually improves and increases her intake of food and liquids. After 10 days of lorazepam treatment, her BFCRS score decreases to 13. Mrs. K begins to speak and her gaze is less fixed. Negativistic behaviors are nearly absent.

Because we are concerned about Mrs. K's pregnancy, lab tests are repeated. A complete metabolic panel shows an elevated glucose

level (122 mg/dL); urinalysis reveals glycosuria (glucose, 1,000 mg/dL), proteinuria (protein, 10 mg/dL), and ketonuria, (ketones, 20 mg/dL). She is transferred to the obstetrics service for evaluation of gestational diabetes.

Psychotropics are continued while Mrs. K is on the obstetrics service; she returns to the inpatient psychiatric unit on an insulin regimen. IM lorazepam is increased to 8 mg/d, and haloperidol is decreased from 20 mg/d, to 10 mg/d, to prevent worsening of catatonia, which can occur when catatonic patients receive a psychotropic.<sup>11</sup> Three days later, Mrs. K's BFCRS score is 12 and she shows only mild rigidity. Mrs. K briefly interacts with staff, particularly when she wants something.

Lorazepam is decreased to 1 mg/d in anticipation of cesarean delivery. Mrs. K becomes more adherent with her medications; often, she takes the oral dose of haloperidol, rather than the IM formulation. On mental status examination she exhibits poor eye contact, rather than a fixed gaze, and her BFCRS score decreases to 7 by day 25.

By the end of lorazepam treatment, Mrs. K has fully recovered from her catatonic state. She interacts with staff, engages with the treatment team, and is excited to go home. At discharge, she is given a diagnosis of schizophrenia with catatonia, and is taking haloperidol, 5 mg, twice a day. She gives birth to a healthy girl.

**The authors' observations**

Mrs. K was treated initially with haloperidol for several reasons. Haloperidol is relatively safe during pregnancy (FDA pregnancy category C) as shown by a recent multicenter, prospective, cohort study in which babies exposed in utero to haloperidol showed a congenital malformation (limb defect) rate within the expected baseline risk for the general population.<sup>22</sup> Lorazepam is FDA category D for use in pregnancy and can cause preterm delivery,<sup>23</sup> floppy infant syndrome, and withdrawal syndromes.<sup>24</sup> We did not use a second-generation antipsychotic (SGA) because it could have made Mrs. K's hyperglycemia worse. SGAs can induce gestational diabetes and increase the incidence of large-for-gestational-age newborns, compared with first-generation antipsychotics.<sup>24</sup> Last, Mrs. K's family rejected ECT.

Because of Mrs. K's poor response to haloperidol, the treatment team decided to start IM lorazepam, which eventually was increased to 8 mg/d. The haloperidol dose was reduced by half to avoid worsening of catatonia and reduce the risk of neuroleptic malignant syndrome.<sup>1,25</sup> When clinical response was achieved, lorazepam was tapered and Mrs. K was discharged with only haloperidol.

In the absence of well-designed prospective follow-up studies, information on the potential impact of prenatal exposure to antipsychotics and benzodiazepines on a child's cognitive development is limited.<sup>26</sup> This case adds to the scant literature on the

**Related Resources**

- Fink M. Catatonia: a syndrome appears, disappears, and is rediscovered. *Can J Psychiatry*. 2009;54(7):437-445.
- Seethalakshmi R, Dhavale S, Suggu K, et al. Catatonic syndrome: importance of detection and treatment with lorazepam. *Ann Clin Psychiatry*. 2008;20(1):5-8.
- Salam S, Kilzieh N. Lorazepam treatment of psychogenic catatonia: an update. *J Clin Psychiatry*, 1988;49(suppl):16-21.

**Drug Brand Names**

Ceftriaxone • Rocephin	Olanzapine • Zyprexa
Haloperidol • Haldol	Short-acting Insulin • Novolin,
Lorazepam • Ativan	Humulin

treatment of catatonia during pregnancy and illustrates how the BFCRS can be utilized during serial patient evaluations to monitor clinical improvement.

**References**

1. Weder NJ, Muralee S, Penland H, et al. Catatonia: a review. *Ann Clin Psychiatry*. 2008;20(2):97-107.
2. Diagnostic and statistical manual of mental disorders, 5th ed. Arlington, VA: American Psychiatric Association; 2013.
3. Espinola-Nadurille M, Ramirez-Bermudez J, Fricchione GL. Pregnancy and malignant catatonia. *Gen Hosp Psychiatry*. 2007;29(1):69-71.
4. Solari H, Dickson KE, Miller L. Understanding and treating women with schizophrenia during pregnancy and postpartum. *Can J Clin Pharmacol*. 2009;16(1):e23-e32.
5. Gross AF, Smith FA, Stern TA. Dread complications of catatonia: a case discussion and review of the literature. *Prim Care Companion J Clin Psychiatry*. 2008;10(12):153-155.
6. Larsen HH, Ritchie JC, McNutt MD, et al. Pulmonary embolism in a patient with catatonia: an old disease, changing times. *Psychosomatics*. 2011;52(4):387-391.
7. Lachner C, Sandson NB. Medical complications of catatonia: a case of catatonia-induced deep venous thrombosis. *Psychosomatics*. 2003;44(6):512-4.
8. Morioka H, Nagatomo I, Yamada K, et al. Deep venous thrombosis of the leg due to psychiatric stupor. *Psychiatry Clin Neurosci*. 1997;51(5):323-326.
9. Nomoto H, Hatta K, Usui C, et al. Vitamin K deficiency due to prolongation of antibiotic treatment and decrease in food intake in a catatonia patient. *Psychosomatics*. 2011;52(5):486-487.
10. Srivastava A, Gupta A, Murthy P, et al. Catatonia and multiple pressure ulcers: a rare complication in psychiatric setting. *Indian J Psychiatry*. 2009;51(3):206-208.

continued

**Clinical Point**

**Babies exposed to haloperidol in utero showed a congenital malformation rate similar to the general population**

**Bottom Line**

Psychosis and catatonia during pregnancy are associated with complications to mother and child. The Bush-Francis Catatonia Rating Scale can be used to identify and track catatonic symptoms. Lorazepam and electroconvulsive therapy have been used safely and with good outcomes in mentally ill pregnant women when used appropriately.



# This month's instantpoll%

## Cases That Test Your Skills

Mr. P, age 85, is admitted to the hospital after he fell at home 2 days ago and is now lethargic, sleepy, confused, and answers questions slowly. He is taking a variety of medications for several chronic illnesses. The medical team asks you to assess Mr. P for possible depression. **How would you treat him?**

- Assess why Mr. P fell and order a CT scan to look for a subdural hematoma
- Review Mr. P's medication list and look for agents that may be contributing to his symptoms
- Prescribe IV haloperidol
- Prescribe risperidone

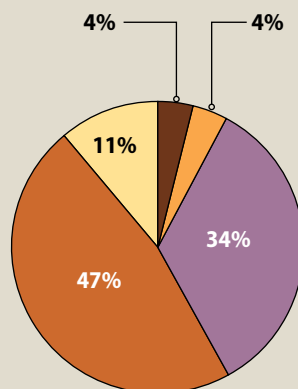
See **"Hospitalized, elderly, and delirious: What should you do for these patients"** page 10-18

Visit **CurrentPsychiatry.com** to answer the **Instant Poll** and see how your colleagues responded. Click on **"Have more to say?"** to comment.

## JUNE POLL RESULTS

Mr. G, age 29, seeks treatment because he's felt lethargic and hopeless and is not sure he wants to continue living since he was diagnosed with HIV 8 months ago. He says she drinks alcohol regularly and "occasionally" uses cocaine. **How would you help him?**

- 4%** Refer him for inpatient substance abuse treatment
- 4%** Prescribe citalopram, 20 mg/d
- 34%** Refer Mr. G for psychiatric hospitalization for suicidal ideation
- 47%** Consult with Mr. G's HIV clinicians to determine which medications she is receiving for HIV before selecting an antidepressant
- 11%** Refer him for psychotherapy



**SUGGESTED READING:**  
Cohen MA. CURRENT PSYCHIATRY. 2013;12(6):19-B.

11. Francis A. Catatonia: diagnosis, classification, and treatment. *Curr Psychiatry Rep.* 2010;12(3):180-185.
12. Sienaert P, Rooseleer J, De Fruyt J. Measuring catatonia: a systematic review of rating scales. *J Affect Disord.* 2011;135(1):1-9.
13. Zisselman MH, Jaffe RL. ECT in the treatment of a patient with catatonia: consent and complications. *Am J Psychiatry.* 2010;167(2):127-132.
14. Rohland BM, Carroll BT, Jacoby RG. ECT in the treatment of the catatonic syndrome. *J Affect Disord.* 1993;29(4):255-261.
15. Raveendranathan D, Narayanaswamy JC, Reddi SV. Response rate of catatonia to electroconvulsive therapy and its clinical correlates. *Eur Arch Psychiatry Clin Neurosci.* 2012;262(5):425-430.
16. Payee H, Chandrasekaran R, Raju GV. Catatonic syndrome: treatment response to lorazepam. *Indian J Psychiatry.* 1999; 41(1):49-53.
17. Bush G, Fink M, Petrides G, et al. Catatonia. II. Treatment with lorazepam and electroconvulsive therapy. *Acta Psychiatr Scand.* 1996;93(2):137-143.
18. Huang TL. Lorazepam and diazepam rapidly relieve catatonic signs in patients with schizophrenia. *Psychiatry Clin Neurosci.* 2005;59(1):52-55.
19. Narayanaswamy JC, Tibrewal P, Zutshi A, et al. Clinical predictors of response to treatment in catatonia. *Gen Hosp Psychiatry.* 2012;34:312-316.
20. Anderson EL, Reti IM. ECT in pregnancy: a review of the literature from 1941 to 2007. *Psychosom Med.* 2009;71: 235-242.
21. Wikner BN, Stiller CO, Bergman U, et al. Use of benzodiazepines and benzodiazepine receptor agonists during pregnancy: neonatal outcome and congenital malformations. *Pharmacoepidemiol Drug Saf.* 2007;16: 1203-1210.
22. Gentile S. Antipsychotic therapy during early and late pregnancy. A systematic review. *Schizophr Bull.* 2010;36: 518-544.
23. Calderon-Margalit R, Qiu C, Ornoy A, et al. Risk of preterm delivery and other adverse perinatal outcomes in relation to maternal use of psychotropic medications during pregnancy. *Am J Obstet Gynecol.* 2009;201:579e1-8.
24. Howland RH. Prescribing psychotropic medications during pregnancy and lactation: principles and guidelines. *J Psychosoc Nurs Ment Health Serv.* 2009;47(5):19-23.
25. White DA, Robins AH. Catatonia: harbinger of the neuroleptic malignant syndrome. *Br J Psychiatry.* 1991; 158:419-421.
26. Gentile S. Neurodevelopmental effects of prenatal exposure to psychotropic medications. *Depress Anxiety.* 2010; 27(7):675-686.