

Transgrediens et Progrediens Palmoplantar Keratoderma (Greither's Disease) with Particular Histopathologic Findings

Renato Grilli, MD, Madrid, Spain
Antonio Aguilar, MD, Madrid, Spain
Pilar Escalonilla, MD, Madrid, Spain
Luisa Soriano, MD, Madrid, Spain
Carmen Fariña, MD, Madrid, Spain
Lucía Martín, MD, Madrid, Spain
Luis Requena, MD, Madrid, Spain

GOAL

To discuss a family with Greither's disease with special focus on histopathologic findings.

OBJECTIVES

1. To describe the clinical appearance of *transgrediens et progrediens* palmoplantar keratoderma.
2. To identify the unique histopathologic findings of PPK.
3. To outline the differential diagnosis of PPK.

CME Test on page 156

We describe a patient with transgrediens et progrediens palmoplantar keratoderma (Greither's disease). Ten of the 25 members of this patient's family in six consecutive generations were affected by the disorder. The pedigree was consistent with an autosomal dominant inheritance pattern, with variable penetrance. The proband's physical examination showed typical signs of Greither's disease. The most striking findings were seen in histopathologic study and consisted of round, focal areas of orthohyperkeratosis located on delled areas of the epidermis. These histopathologic features were present in both the lesions of the palms and dorsum of the hands. We review the clinical

manifestations and histopathologic findings of this particular variant of palmoplantar keratoderma and the differential diagnosis.

In 1952, Greither¹ originally described keratosis ex-tremitatum hereditaria progrediens, a new kind of palmoplantar keratoderma (PPK), inherited in an autosomal dominant pattern with variable expression. We describe a family with Greither's disease. Histopathologic study of the lesions of the proband showed peculiar histopathologic findings that consisted of focal, round areas of orthohyperkeratosis on delled areas of the epidermis.

Case Report

A 47-year-old white woman was evaluated for diffuse palmoplantar keratotic lesions that had been present since she was 16 years old. The lesions started as confluent papules that progressed, resulting in diffuse hyperkeratosis. She also had palmoplantar hyper-

From the Department of Dermatology, Fundación Jiménez Díaz and Hospital Severo Ochoa, Madrid, Spain.
REPRINT REQUESTS to the Department of Dermatology, Fundación Jiménez Díaz, Avenida Reyes Católicos N° 2, Madrid 28040, Spain (Dr. Grilli).

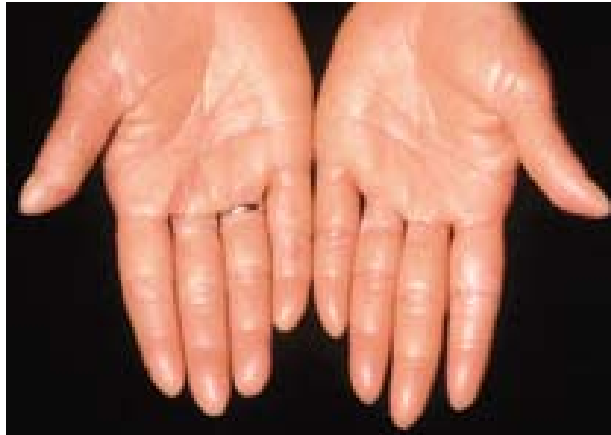

FIGURE 1. Diffuse keratoderma involving the palms.

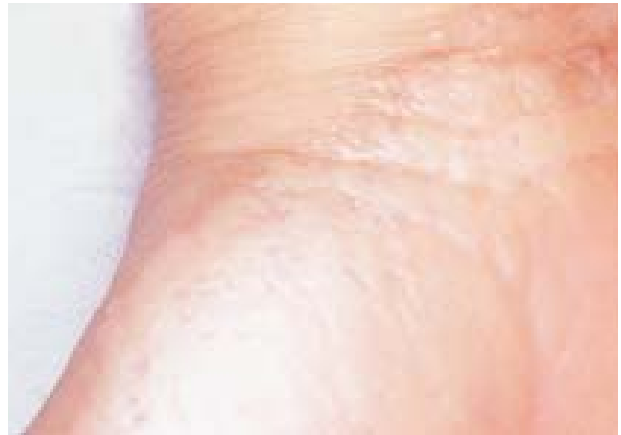

FIGURE 2. Lesions extended to the ventral aspect of the wrists. Confluent keratotic papules can be seen at the border.

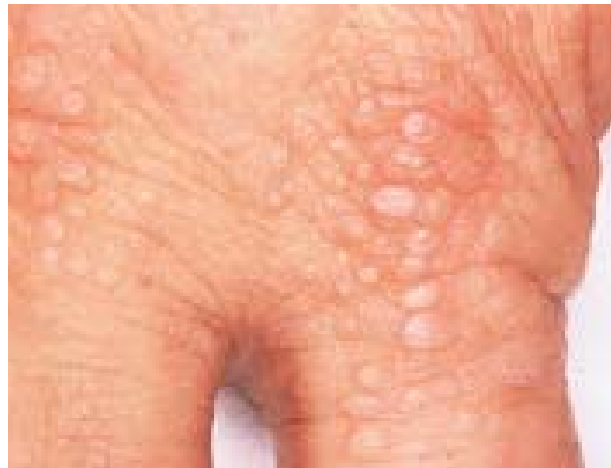

FIGURE 3. Keratotic papules over the knuckles.

hidrosis. Her personal history included Basedow-Graves' disease.

Physical examination revealed diffuse keratoderma on the palms and soles, with no erythematous border (Figure 1). The hyperkeratosis extended to the ventral aspect of the wrists, where confluent papules could be seen (Figure 2). There were hyperkeratotic papules on the dorsa of the fingers, especially over the knuckles (Figure 3). On the soles, hyperkeratotic lesions were arranged diffusely, although they were more prominent in areas of weight-bearing (Figure 4) and extended to the skin over the Achilles tendon (Figure 5). There was no hyperkeratosis over the knees and elbows. Hair, nails, and teeth were normal and no other anomalies were present.

A study of the family pedigree showed a family of 25 members in six generations, with 10 members affected by the diffuse palmoplantar keratoderma (Figure 6). The proband's father was married twice, having affected

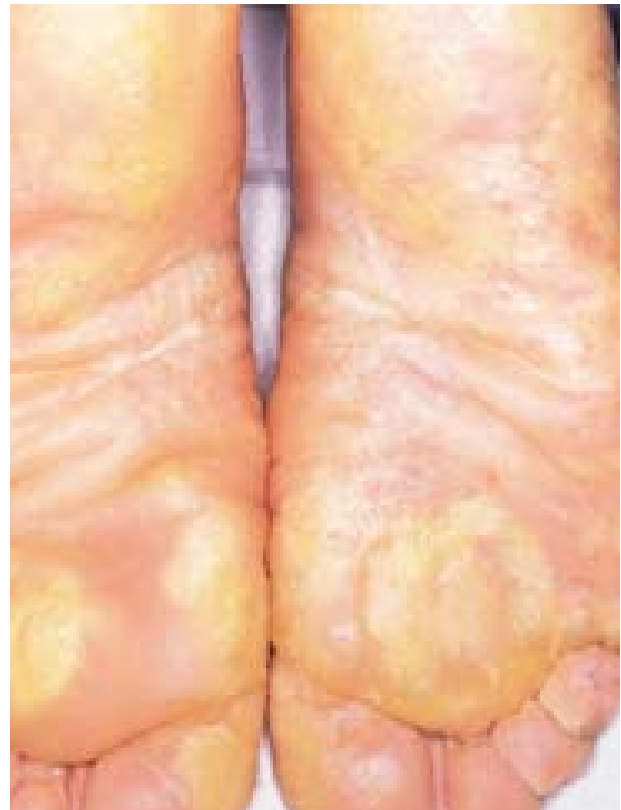

FIGURE 4. Diffuse hyperkeratosis of the soles, with more prominent lesions on weight-bearing areas.

relatives in families of both of his wives. One son and the grandson of the proband were 12 and 7 years old, respectively, and at this age, it is uncertain whether or not they will show palmoplantar keratoderma in the future. There was no history of consanguinity. The pedigree shows a typical pattern of autosomal dominant inheritance with variable expression.

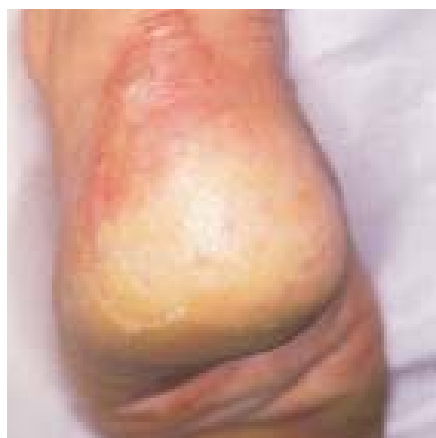

FIGURE 5. Hyperkeratosis extending to the Achilles tendon.

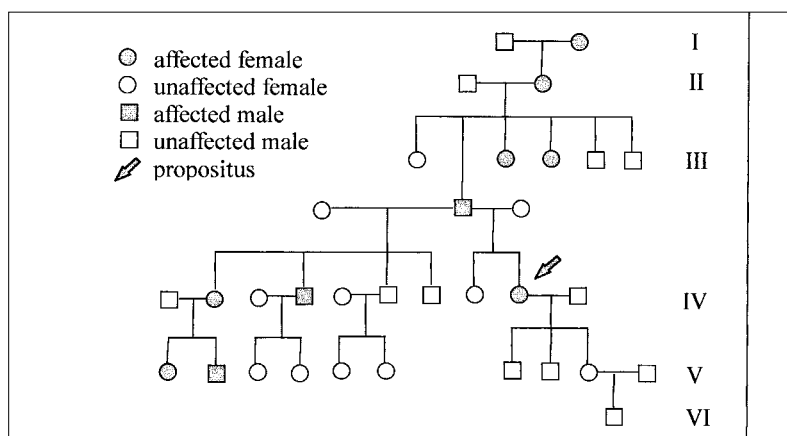


FIGURE 6. Family pedigree of proband with palmoplantar keratoderma.

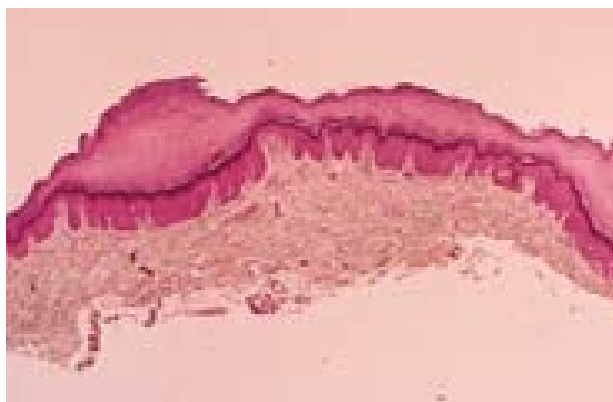

FIGURE 7. Histopathologic findings from a biopsy specimen taken from the left palm consisted of focal depressions of the epidermis occupied by round foci of compact orthokeratotic horny layer.

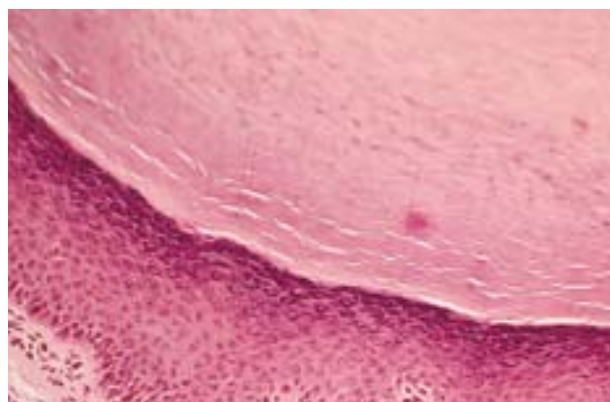


FIGURE 8. Hypergranulosis was more prominent at the bottom of the epidermal dells.

Two cutaneous biopsy specimens were taken: one from the left palm and the other from hyperkeratotic papules on the dorsum of the left hand. The histopathologic findings were similar in both specimens: focal depressions of the epidermis occupied by round foci of compact orthokeratotic horny layer (Figure 7). Hypergranulosis was more prominent at the bottom of the epidermal dells (Figure 8). There was no epidermolytic hyperkeratosis and stains for elastic tissue demonstrated no abnormalities.

Comments

Inherited PPKs are a heterogeneous group of diseases and many attempts to classify them have been made based on different criteria; the most important being clinical morphology, distribution of the hyperkeratosis, the presence or absence of associated anomalies, and the inheritance pattern.²⁻⁵ These classifications,

however, are not entirely reliable because they are based predominantly on morphology, and the clinical appearance of the lesions varies from one person to another, even within the same family.⁶ When the underlying specific genetic defects of each type of PPK are elucidated, significant improvement in our understanding of these disorders will be achieved.

In 1952, Greither described *transgrediens et progrediens* PPK, and since then, few cases of this variant of PPK have appeared in the literature.⁷⁻¹⁰ Greither's disease is characterized by diffuse keratoderma of the palms and soles, which may be slight, but by definition extends to the dorsal aspects (*transgrediens*), characteristically involving the skin over the Achilles tendon. Hyperkeratotic lesions on the palms and soles are usually associated with hyperhidrosis and the borders often exhibit an erythematoviolaceous hue. Hyperkeratotic erythematous plaques may also be present over the knees and elbows.

Table I Differential Diagnosis of Palmoplantar Keratoderma						
	Vörner PPK	UNNA-Thost PPK	Greither PPK	Mal De Meleda	Acrokerato elastoidosis	Focal Acral Hyperkeratosis
Inheritance	Autosomal dominant	Autosomal dominant	Autosomal dominant	Autosomal recessive	Autosomal dominant	Autosomal dominant
Onset	Before 2 years (since birth)	Before 2 years	After 2 years (since birth or the first weeks)	Before 2 years (mainly under 20 years)	After 2 years (mainly under 30 years)	After 2 years
Transgrediens	No	No	Yes	50% of cases	Yes	Yes
Constrictive Bands	No	No	No	Yes	No	No
Involution	No	No	Possible after 5 th decade	No	No	No
Hyperhidrosis	Yes	Yes	Yes	Yes	Possible	Possible
Epidermolytic Hyperkeratosis	Yes	No*	No	No	No	No
Altered Elastic Fibers	No	No	No	No	Yes	No
Nail Involvement	Rare	Rare	Rare	Frequent	No	No
PPK, palmoplantar keratoderma *It has recently been demonstrated that members of the same family of the patients originally described with Unna-Thost PPK showed epidermolytic hyperkeratosis. ¹⁴						

In classic cases, lesions of Greither's disease start after the 2nd year of life and tend to involute after the 6th decade. In the cases described in the literature, the histopathologic findings are nonspecific and consist of orthokeratotic hyperkeratosis. Flückiger and Itin studied a case of Greither's disease ultrastructurally and found cytoskeleton aberrations, filament aggregations, and cell-to-cell junctions with an imbricated pattern.⁷

Our case is clinically a typical example of Greither's disease. The histopathologic findings are the most striking feature because of the focal nature of the hyperkeratosis. On the dorsum of the hands, this might be related to the clinically papular character of the lesions, but these very same findings were present on the specimen taken from the palm, where the keratoderma showed a clinically diffuse character. To our knowledge, these peculiar histopathologic features have not been previously described in the literature, because biopsy specimens from lesions of Greither's disease usually show only a marked diffuse hyperkeratosis.

Greither's disease has been associated with erythrokeratoderma variabilis¹¹ and, recently, an inflammatory type of familial PPK has been proposed as a variant of Greither's disease.¹² Kansky and Arzensek questioned Greither's PPK as a specific entity. They included it within Unna-Thost PPK on the basis of previously published data of hyperkeratosis of the hands and feet extending to dorsal surfaces in patients with Unna-Thost PPK and the presence of hyperkeratosis of knees and elbows (one of the findings they consider typical of Greither's PPK) in other types of PPK.¹³

We, along with other authors,⁶⁻¹⁰ think that Greither's keratoderma is a separate entity from Unna-Thost disease, not only because of the presence or absence of hyperkeratosis on the knees and elbows, but also because of its characteristic onset after the 2nd year of life. This is in contrast to the earlier onset of Unna-Thost PPK, which usually appears in the 1st months of life. Furthermore, Greither's PPK always extends to the dorsal aspects of the hands and feet; characteristically, there is hyperkeratosis over the Achilles tendon and the hyperkeratosis on the palms and soles is usually less marked than in Unna-Thost PPK. In addition, Greither's PPK tends to involute after the 5th decade of life, while Unna-Thost PPK does not. Moreover, Unna-Thost PPK has recently been questioned as a separate nosologic entity by Küster and Becker. They found epidermolytic hy-

perkeratosis in members of the same family of the patients originally described by Thost.¹⁴

The differential diagnosis of Greither's disease, summarized in Table I, includes mal de Meleda, Unna-Thost PPK, Vörner keratoderma, and, because of the papular morphology of the lesions in our case, acrokeratoelastoidosis and focal acral hyperkeratosis were also considered.

REFERENCES

1. Greither A: Keratosis extremitatum hereditaria progrediens mit dominantem Erbgang. *Hautarzt* 3: 198-203, 1952.
2. Lucker GPH, van de Kerkhof PCM, Steijlen PM: The hereditary palmoplantar keratosis: an updated review and classification. *Br J Dermatol* 131: 1-14, 1994.
3. Itin PH, Lautenschlager S: Palmoplantar keratoderma and associated syndromes. *Semin Dermatol* 14: 152-161, 1995.
4. Ocaña Sierra J, Blesa G, Wilhelmi L: Queratodermias palmoplantares. *Actas Dermosifiliogr* 72: 513-526, 1981.
5. Moreno JC, Ortega M, Quintana J: Queratodermias palmoplantares. *Piel* 3: 363-371, 1988.
6. Itin PH: Classification of autosomal dominant palmoplantar keratoderma: past-present-future. *Dermatology* 185: 163-165, 1992.
7. Flückiger R, Itin PH: Keratosis extremitatum (Greither's disease): clinical features, histology, ultrastructure. *Dermatology* 187: 309-311, 1993.
8. Dominguez JD, de Argila D, Rivera R, et al.: Queratoderma difusa progresiva (enfermedad de Greither). *Actas Dermosifiliogr* 88: 119-122, 1997.
9. van de Kerkhof PCM, Mali-Gerits M, Ruiter D, et al.: Keratosis palmoplantaris transgrediens et progrediens Greither. *Br J Dermatol* 120: 125-126, 1989.
10. Rook AJ: Progressive palmoplantar keratoderma—Greither's syndrome. *Br J Dermatol* 79: 302, 1967.
11. Wollina U, Knopf B, Schaaschmidt H, et al.: Familiäre Koexistenz von erythrokeratoderma variabilis und Keratosis palmoplantaris transgrediens et progrediens. *Hautarzt* 40: 169-172, 1989.
12. Beylot-Barry M, Taïeb A, Surlève-Bazeille JE, et al.: Inflammatory familial palmoplantar keratoderma: Greither's disease? *Dermatology* 185: 210-214, 1992.
13. Kansky A, Arzensek J: Is palmoplantar keratoderma of Greither's type a separate nosologic entity? *Dermatologica* 158: 244-248, 1979.
14. Küster W, Becker A: Indication for the identity of palmoplantar keratoderma type Unna-Thost with type Vörner. Thost's family revisited 110 years later. *Acta Derm Venereol (Stockh)* 72: 120-122, 1992.

FACULTY DISCLOSURE

The Faculty Disclosure Policy of the College of Medicine requires that faculty participating in a CME activity disclose to the audience any relationship with a pharmaceutical or equipment company that might pose a potential, apparent, or real conflict of interest with regard to their contribution to the program. Dr. Grilli reports no conflict of interest.