

From The New York-Presbyterian Hospital, Columbia-Presbyterian Center

# Calcinosis Cutis Following the Administration of Intravenous Calcium Therapy

Mark H. Kagen, MD New York, New York

Mimi Goel Bansal, MD New York, New York

Marc Grossman, MD New York, New York

*Calcinosis cutis, the cutaneous deposition of calcium salts in the dermis,<sup>1</sup> can occur through a variety of pathogenetic mechanisms, and can be associated with both normal and elevated calcium levels. Iatrogenic causes of calcinosis cutis include extravasation of intravenously administered calcium chloride or calcium gluconate, and traumatic deposition of calcium in the skin, subsequent to electromyography or electroencephalography. We report two cases of calcinosis cutis following intravenous infusion of a calcium-containing salt.*

## Case I

A 65-year-old woman with a 1-year history of acute myelogenous leukemia on maintenance hydroxyurea therapy was admitted to the New York Presbyterian Hospital on June 27, 1997, complaining of increasing dyspnea on exertion and fatigue. A white blood cell count of  $93 \times 10^6/\text{mm}^3$ ; hemoglobin, 9.3 mg/dl; and platelets,  $25 \times 10^6/\text{mm}^3$  prompted admission with a diagnosis of relapsed leukemia. She was started on leukopheresis and combination cytarabine and fludarabine therapy. On July 3, she was found to have a calcium level of 5.6 mg/dl, and received three vials of 10 ml of intravenous calcium chloride solution 10% over a 1-hour period, after which her serum calcium level remained normal for the rest of her hospitalization. Other significant laboratory values included: phosphorous, 7.8 mg/dl; leutinizing deficiency hormone of 4520 IU; potassium, 3.6 mg/dl; blood urea nitrogen, 41 mg/dl; creatinine, 0.7 mg/dl; and uric acid, 4.6 mg/dl. On July 29, the dermatology service was consulted to evaluate several plaques on both arms, which first appeared 2 or 3 days after receiving

the calcium infusion. On physical examination, she had a  $2 \times 2$ -cm irregular indurated white plaque overlying the antecubital vein on the extensor surface of her right arm; she had five 0.5- to 1-cm white-yellow discrete papules overlying the antecubital vein on the extensor surface of her left arm arranged linearly (Figure 1). No ulcers, erythema, or necrosis were noted. A 3-mm punch biopsy was performed.

The histologic examination showed diffuse calcification primarily in the upper portion of the dermis, including the papillary dermis. There was no inflammatory infiltrate or intravascular calcification (Figure 2).

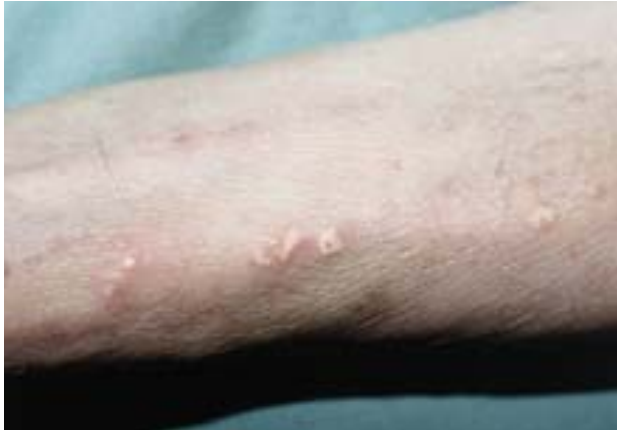## Case II

A 24-year-old woman with widespread Burkitt's lymphoma was admitted for renal insufficiency. The patient was being treated with cyclophosphamide, vincristine, and cytarabine chemotherapy. The hospital course was complicated by continued hypocalcemia and hyperphosphatemia. Significant laboratory values included: serum calcium, 5.0 mg/dl; phosphorus, 15.0 mg/dl; potassium, 4.7 mg/dl; blood urea nitrogen, 82 mg/dl; and creatinine, 3.6 mg/dl. She was treated with numerous vials of intravenous calcium gluconate. The dermatology service was consulted to evaluate several irregular, hard, yellow-white papules over her left intravenous site. X-ray of her left forearm revealed tiny calcifications in the fascial planes adjacent to the proximal radial shaft. A diagnosis of calcinosis cutis was made.

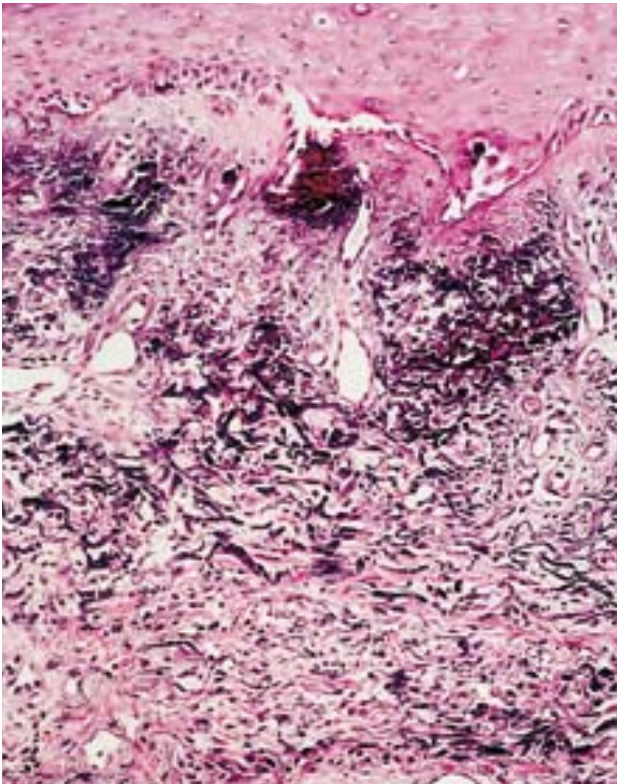
## Discussion

The deposition of calcium salts in tissues other than enamel and osteoid is defined as heterotopic calcification. Heterotopic calcification may be further subclassified into metastatic calcification if the serum calcium and phosphate levels are elevated or dystrophic calcification, if serum calcium and phosphate levels

REPRINT REQUESTS to Laboratory for Investigative Dermatology, Box 178, Rockefeller University, 1230 York Avenue, New York, NY 10021 (Dr. Kagen).



**FIGURE 1.** Extensor surface of the left arm, with several white-yellow papules in a linear distribution overlying the vein.



**FIGURE 2.** Diffuse calcification primarily in the upper portion of the papillary dermis (magnification,  $\times 40$ ).

are normal. Metastatic calcification is rarely associated with skin involvement, whereas dystrophic calcification, which may be seen in a variety of congenital, degenerative, and collagen vascular disorders, is more commonly associated with skin involvement.<sup>2</sup> Calcinosis cutis due to extravasated calcium, an iatrogenic form of calcinosis cutis, may have features of both types of heterotopic calcification.

Iatrogenic calcinosis cutis can occur as a complication of either intravenous calcium chloride or calcium gluconate therapy, as demonstrated in these two patients. Other reported causes of iatrogenic calcinosis cutis include minor trauma in association with prolonged contact with saturated calcium chloride electrode paste, in patients undergoing electroencephalographic or electromyographic examination.

When the extravasation of calcium solution is massive and followed by swelling, erythema, induration, and soft tissue necrosis, the diagnosis of this complication is simple.<sup>3</sup> When the extravasation is minor, it may be overlooked and the relationship between the extravasation and the calcinosis is less obvious.<sup>4</sup> Clinically, the lesions usually appear several days after calcium administration. The average time interval is 13 days, although a range of 2 hours to 24 days after infusion has been reported.<sup>2,5,6</sup> The diagnosis is suggested by the linear arrangement of firm to hard, yellow-white papules or plaques with or without areas of necrosis, with early inflammatory erythema that resolves. The lesions are usually located on an extremity proximal or distal to an intravenous site. If the lesions develop days to weeks after the infusion when the intravenous line has been long removed, the causal relationship may not be obvious.

The exact pathogenesis of this condition is unknown, but is thought to involve both a transient elevation of the local concentration of calcium after infusion and tissue damage at the site of the extravasated calcium solution. The final pathway of calcification is the formation of crystalline and insoluble calcium phosphate mineral, in the form of hydroxyapatite. Physicians need to be aware of this distinctive, local complication of peripheral intravenous calcium administration and its benign course.

## REFERENCES

1. Walsh JS, Fairley J: Calcifying disorders of the skin. *J Am Acad Dermatol* 33: 693-706, 1995.
2. Goldminz D, Barnhill R, McGuire J, Stenn K. Calcinosis cutis following extravasation of calcium chloride. *Arch Dermatol* 124: 922-925, 1988.
3. Stewart VL, Herling P, Dalinka MK: Calcification in soft tissues. *JAMA* 250: 78-81, 1983.
4. Dalinka MK, Melchior EL: Soft tissue calcification in systemic disease. *Bull NY Acad Med* 56: 539-563, 1980.
5. Jucgla A, Sais G, Curco N, Marcoval J, Moreno A, Peyri J: Calcinosis cutis following liver transplantation: a complication of intravenous calcium administration. *Br J Dermatol* 132: 275-278, 1995.
6. Weiss Y, Ackerman C, Schmilvitz L: Localized necrosis of scalp in neonates due to calcium gluconate infusions: a cautionary note. *Pediatrics* 56: 1084-1086, 1975.