

Lipedematous Alopecia

Alina G. Bridges, DO Rochester, Minnesota

Larry C. von Kuster, MD Freemont, Ohio

Stephen A. Estes, MD Cincinnati, Ohio

GOAL

To describe the characteristics of lipedematous alopecia, a highly unusual disorder of the scalp and scalp hairs.

OBJECTIVES

1. To outline the epidemiologic and etiologic features of lipedematous alopecia.
2. To discuss histologic findings associated with lipedematous alopecia.
3. To review therapeutic options for this unusual disorder

CME Test on page 210

Lipedematous alopecia is an unusual disorder characterized by short, brittle scalp hairs associated with thickening of the scalp by adipose tissue. All except one reported case have been in African-American females. It is our purpose to report the seventh case of this condition.

Lipedematous alopecia is a rare disorder characterized by short, brittle scalp hairs associated with thickening of the scalp by adipose tissue. Lipedematous scalp lacks hair loss or hair shaft abnormalities. This entity was first described by Cornbleet¹ in 1935. There have been five cases reported worldwide,^{1,5} and all except one case⁴ occurred in African-American females. We present a 48-year-old African-American female with lipedematous alopecia.

Case Report

A 48-year-old black female with renal failure presented with a 6-month history of scalp pruritus and hair loss. Her hair would grow to a length of 1 inch over a 3- to 6-month period and then suddenly break off. She used Ultra-Sheen hair conditioner and had not used a hot comb for at least two years before the onset of the hair loss. Family history was unremarkable.

Skin examination revealed diffuse boggy and thickening of her scalp. She also had several excoriations and patchy thinning of the hair on the scalp (Figure 1). The hair over the top of her head measured 4 mm in length, while along the sides and back these short hairs were mixed with longer, fine 1- to 2-cm hairs. The nails were short, but otherwise unremarkable. No hyperelasticity of the skin or hyperextensibility of the joints was noted. The thickness at the vertex of the scalp was 1 cm, measured by sterile needle probing, and 1.2 cm, measured by xeroradiogram.

Histologic examination of a biopsy obtained from the vertex of the scalp revealed a mild basketweave hyperkeratosis of the epidermis, a sparse superficial perivascular lymphocytic infiltrate, and an increased thickness of the subcutaneous fat layer (Figures 2 and 3). The hair follicles were in anagen phase, and appeared normal. There was no scarring in the dermis or subcutaneous fat. Microscopic examination of hairs obtained by hair pull revealed distal loss of cuticle, fraying, and splitting of the hair shaft as seen in trichorrhexis nodosa and trichoptilosis.

There was no change in her scalp appearance and examination over the next several months of observation. However, the longer fine hairs over the lateral and posterior regions of the scalp disappeared, and the scalp was covered diffusely by the shorter and thicker hairs.

Comments

Lipedematous alopecia is characterized by diffuse boggy or thickening of the scalp associated with short

Dr. Bridges is a Dermatopathology fellow at the Mayo Clinic, Rochester, Minnesota.

Dr. Von Kuster is in private practice in Freemont, Ohio.

Dr. Estes is Associate Professor of Clinical Dermatology at the University of Cincinnati, Cincinnati, Ohio

LIPEDEMATOUS ALOPECIA

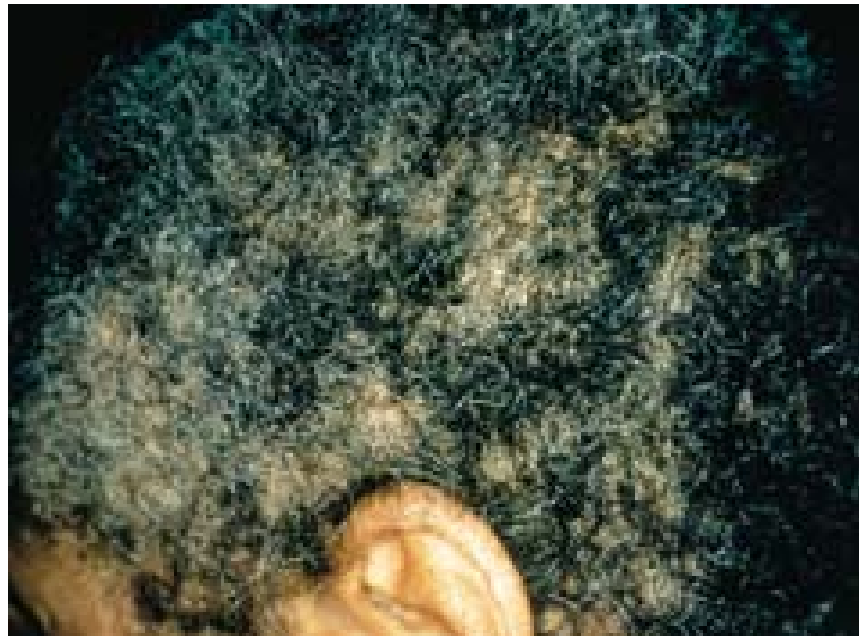

FIGURE 1. Diffuse bogginess and thickening of the scalp associated with patchy alopecia.

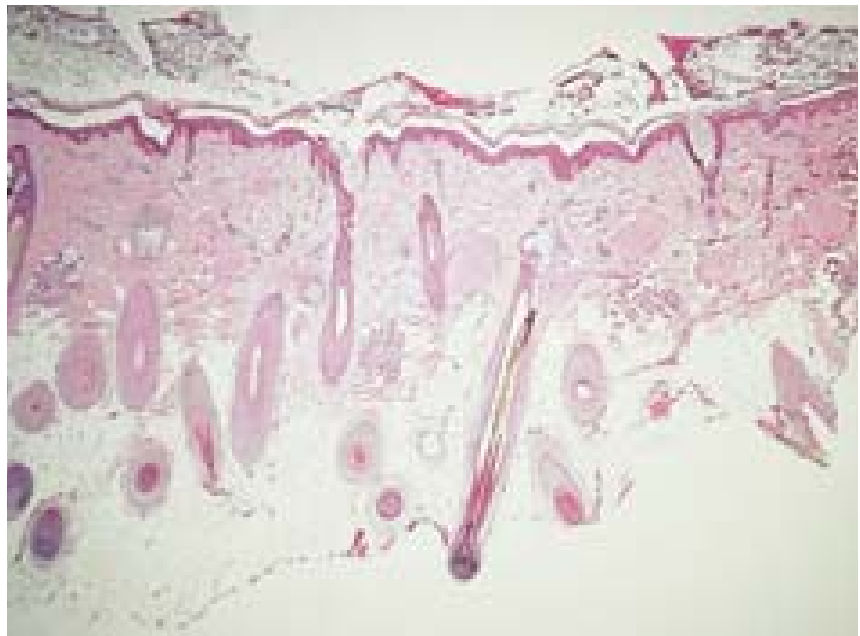


FIGURE 2. Hyperkeratosis with a mild perivascular infiltrate in the superficial dermis and increased thickness of subcutaneous fat layer (original magnification, x40).

brittle scalp hairs.^{2,3,5} Lipedematous scalp lacks the presence of scalp hair abnormalities.^{1,4} Six previous cases of lipedematous alopecia and scalp have been reported (see Table I for a summary of the findings in these two related conditions).¹⁻⁵ These patients may have pruritus, pain, or paresthesia of the scalp.^{1-3,5} All the patients, except for one female who was Korean,⁴ have been African-American females ranging in age from 28 to 75 years.^{1-3,5} The scalp thickness has ranged from 10 to 15 mm,¹⁻⁵ and the patients with an associated hair loss typically do not grow hair greater than

2 cm in length.^{2,3,5} The average scalp thickness at the bregma was found to be 5.8 ± 0.12 mm according to one study that evaluated 523 healthy adults using lateral skull roentgenograms.⁶ One patient had several hairs that were characteristic of trichorrhexis nodosa,³ and another had hairs that were fractured in the keratogenous zone.² Isolated cases have been associated with hyperelasticity of the skin and hyperextensibility of the joints,³ diabetes mellitus, and a systolic murmur.² Histologic examination has shown an increase in subcutaneous fat, hyperkeratosis, and a mild patchy

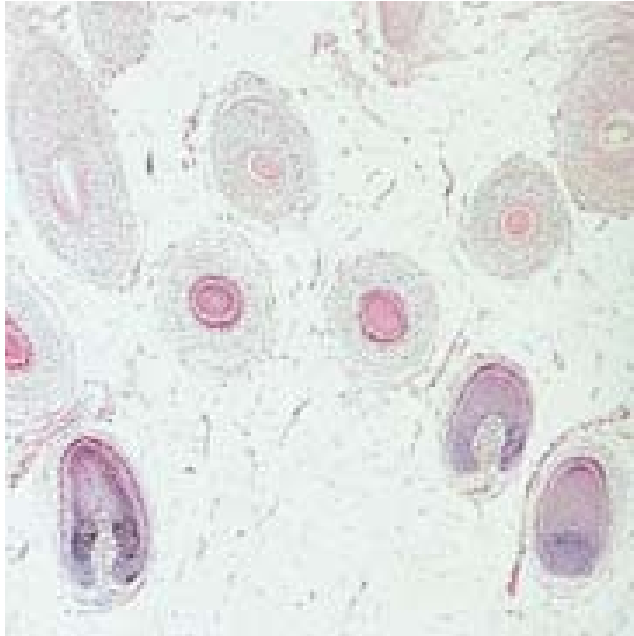


FIGURE 3. Hyperkeratosis with a mild perivascular infiltrate in the superficial dermis and increased thickness of subcutaneous fat layer (original magnification, X200).

Table I.

Summary of the Characteristics of Lipedematous Alopecia

Age	Race	Sex	Clinical	Hair Shaft Abnormality	Hair Length (cm)	Scalp Thickness (mm)	Treatment	Other Medical Problems	Ref.
48	African-American	F	Pruritic, thick, boggy areas of scalp with diffuse hair loss	Yes	0.4-2	12	None	Renal failure	-
44	African-American	F	Pruritic and occasional painful swelling of scalp	No	Unknown	Unknown	None	None	1
28	African-American	F	Sore, thick, boggy areas of scalp with diffuse hair loss	No	2	15	Improved with systemic corticosteroids	Systolic murmur	2
75	African-American	F	Fluctuant scalp and short hairs associated with pruritus and paresthesias	Yes	0.5-2	10	None	Diabetes mellitus	2
62	African-American	F	Mildly pruritic, thick, boggy scalp with short hairs	Yes	2-7	15	No response to intralesional triamcinolone or coal tar solution	Hyperelasticity of skin and hyperlaxity of joints	3
32	Korean	F	Asymptomatic swelling along the vertex of scalp	No	Unknown	10.7	None	None	4
49	African-American	F	Swelling of scalp and frontal hair thinning associated with paresthesias	No	0.5-2	12.3	None	None	5

lymphocytic infiltrate.^{3,5} In addition, follicular plugging, atrophic follicles, and dermal fibrosis were seen in one case.^{3,5} The course of the disease is chronic. One patient noticed an increase in scalp hairs and a decrease in scalp thickness on 4 months of systemic prednisone.² Intralesional triamcinolone and other topical treatments including coal tar solution and salicylic acid were ineffective in another patient.³ The other patients were treated symptomatically without progression of the disease.^{3,5}

Our case had a clinical appearance and histology similar to the previously reported cases. Our patient was a middle-aged African-American female who developed pruritic, thick, boggy areas of her scalp with diffuse hair loss. She had chronic renal failure, but did not have any cardiac, endocrinologic, or rheumatologic findings. She was unable to grow hair on her scalp longer than 2 cm and had several hairs with trichorrhexis nodosa. Histologic examination showed an increase in subcutaneous fat, hyperkeratosis, and a mild patchy lymphocytic infiltrate in the superficial dermis. Her condition has been stable with symptomatic therapy.

The differential diagnosis of lipedematous alopecia or scalp should include cutis verticis gyrata. The previously reported cases and our case did not have ridges or furrows of the scalp as seen in this entity. The findings of trichorrhexis nodosa in our case and another case could be due to physical trauma such as tight braiding of hair, mechanical trauma such as scratching of the scalp to relieve pruritus, and chemical trauma from hot combs and perming. But this hair shaft abnormality does not explain the in-

crease in thickness of the scalp due to the increase in the subcutaneous fat layer or the diffuse non-scarring hair loss seen in lipedematous alopecia. There has been no evidence to support an underlying systemic abnormality contributing to the development of this disorder, despite the isolated reports of patients with this disorder having cardiac, endocrinologic, or rheumatologic abnormalities.^{2,3} Lipedematous alopecia and scalp are rare disorders that should be recognized as distinct entities. However, the pathogenesis of these two related disorders is unknown. The fact that the hair follicles appear normal histologically suggests that the problem is secondary to the fatty change in the stroma. Why fat accumulates in the scalp is unknown. It has been hypothesized that the increase in subcutaneous fat exerts an increased pressure on the hair follicles leading to shorter hair growth or anagen cycles and decreased hair growth rates.²

REFERENCES

1. Cornbleet T: Cutis verticis gyrata? lipoma? *Arch Dermatol Syph* 32: 688, 1935.
2. Coskey RJ, Fosnaugh RP, Fine G: Lipedematous alopecia. *Arch Dermatol* 84: 619-622, 1961
3. Curtis JW, Heising NA: Lipedematous alopecia associated with skin hyperelasticity. *Arch Dermatol* 89: 819-820, 1964.
4. Lee JH, Sung YH, Yoon JS, Park JK: Lipedematous scalp. *Arch Dermatol* 130: 802-803, 1994.
5. Kane KS, Kwan T, Baden HP, Bigby M: Woman: with new-onset boggy scalp. *Arch Dermatol* 134: 499, 1998.
6. Garn MS, Selby S, Young R: Scalp thickness and fat-loss theory of balding. *Arch Dermatol Syph* 70: 601-608, 1954.

FACULTY DISCLOSURE

The Faculty Disclosure Policy of the College of Medicine requires that faculty participating in a CME activity disclose to the audience any relationship with a pharmaceutical or equipment company that might pose a potential, apparent, or real conflict of interest with regard to their contribution to the program. Dr. Bridges reports no conflict of interest.