

# Diltiazem-Induced Drug Eruption Sparing Seborrhic Keratoses

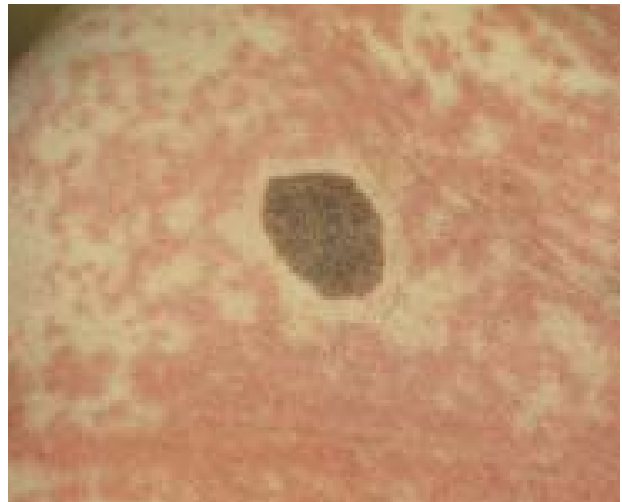
Warren R. Heymann, MD, Marlton, New Jersey

*A case of a diltiazem-induced morbilliform drug eruption, which spared the circumferential margin of seborrhic keratoses, is presented. Hypotheses regarding the pathogenesis of this novel exanthem are discussed. The potential mechanisms may be immunologic involving cytokines, or due to diminished levels of prostaglandin E<sub>2</sub>, altered optical properties of the skin, mechanical pressure phenomena, or altered local vasoconstriction secondary to diltiazem itself.*

**E**xanthematous drug rashes are among the most common adverse cutaneous reactions to medications. The pathogenesis of such eruptions is still an enigma, but is presumed to be immunologically based. A novel case of a drug eruption due to diltiazem, sparing a circumferential rim around seborrhic keratoses, is presented herein.

## Case Report

A 76-year-old woman with a medical history remarkable for hypertension, hypothyroidism, and hypercholesterolemia, presented with a rash of 3 days' duration. Diltiazem hydrochloride therapy was instituted 10 days before the onset of the eruption. Her other medications, which she had been ingesting for months, included levothyroxine and pravastatin, for hypothyroidism and hypercholesterolemia, respectively. The rash was initially observed on her breasts, and rapidly spread to her trunk and extremities. Pruritus was marked, but no other systemic symptoms were noted. Physical examination was remarkable for confluent, blanching, morbilliform erythema on her cheeks, torso, and proximal extremities. There was no involvement of mucous membranes. Brown, verrucous papules and plaques characteristic of seborrhic keratoses were noted on the neck, breast, and



**FIGURE 1.** The circumferential area of a 3.0-cm seborrhic keratosis of the right lower abdominal quadrant is spared of the morbilliform erythema induced by diltiazem.

right lower abdominal quadrant. These lesions had been present for years. The exanthem spared an approximately 0.5-cm circumferential rim around the seborrhic keratoses (Figure 1). Administration of prednisone (60 mg daily, tapered over 3 weeks) and discontinuation of the diltiazem led to complete resolution of the eruption.

## Discussion

Diltiazem is a calcium channel antagonist utilized in the treatment of hypertension and coronary artery disease. The incidence of rashes with the medication is approximately 1.3%, with morbilliform reactions being the most common. Erythema multiforme, Stevens-Johnson syndrome, toxic epidermal necrolysis, and exfoliative erythroderma have also been reported.<sup>1</sup> Leukocytoclastic vasculitis<sup>2</sup> and drug-induced fever preceding an exanthem<sup>3</sup> have also been attributed to diltiazem.

The patient developed her eruption within 2 weeks of administration of diltiazem, consistent with the observation that such diltiazem-induced drug

Dr. Heymann is Head, Division of Dermatology, Cooper Health System, UMDNJ - Robert Wood Johnson Medical School at Camden, Marlton, New Jersey.

REPRINT REQUESTS to Division of Dermatology, Cooper Health System, UMDNJ - Robert Wood Johnson Medical Center at Camden, 100 Brick Road, Suite 306, Marlton, New Jersey 08053.

rashes typically occur within this time frame.<sup>1</sup> Because her eruption resolved rapidly after discontinuing diltiazem, without discontinuation of levothyroxine or pravastatin, it is reasonable to assume that these other medications were not responsible for the eruption. The striking feature of her exanthem was the distinct sparing of skin around the circumference of her seborrheic keratoses, which, to the best of my knowledge, has not been previously reported.

The pathogenesis of morbilliform eruptions remains to be defined, but is presumed to be due to immunologic mechanisms. Seborrheic keratoses have been demonstrated by polymerase chain reaction to elaborate cytokines of the TH1 profile (predominantly IL-2 and interferon- $\gamma$ ).<sup>4</sup> Perhaps such cytokines locally inhibit the immunologic aberrations responsible for the exanthem. Less plausible hypotheses would include presumed mechanisms in the pathogenesis of the Woronoff ring (the circumferential blanching of skin at the perimeter of a healing psoriatic plaque), such as diminished levels of prostaglandin E2<sup>5</sup> or altered optical properties of the skin.<sup>6</sup> Mechanical factors could be pathogenic. Relative sparing of pressure areas may occur in exanthematous drug reactions.<sup>7</sup> Conceivably, the local pressure induced by a large benign lesion such as a seborrheic keratosis could result in an analogous phenomenon. A final possibility is that diltiazem itself, being a calcium channel blocker, altered local vasoconstriction around seborrheic keratoses to allow for this observation.

In conclusion, a case of a drug eruption due to diltiazem, which spared the borders of seborrheic keratoses, is presented. Although the pathomechanism of this process remains speculative, the eventual understanding of how skin may be protected from immunologic assault may ultimately result in novel therapies for such disorders.

## REFERENCES

1. Wirebaugh SR, Geraets DR: Reports of erythematous macular skin eruptions associated with diltiazem therapy: DICP. *Ann Pharmacother* 24: 1046-1049, 1990.
2. Kuo M, Winiarsarki N, Garella S: Nonthrombocytopenic purpura associated sequentially with nifedipine and diltiazem. *Ann Pharmacother* 26: 1089-1090, 1992.
3. Dominguez EA, Hamill RJ: Drug-induced fever due to diltiazem. *Arch Intern Med* 151: 1869-1870, 1991.
4. Yamamura M, Modlin RL, Ohmen JD, Moy RL: Local expression of anti-inflammatory cytokines in cancer. *J Clin Invest* 91: 1005-1010, 1993.
5. Pennys NS, Ziboh V, Simon P, Lord J: Pathogenesis of Woronoff ring in psoriasis. *Arch Dermatol* 112: 955-957, 1976.
6. Klemp P, Bojsen J: Local variation in cutaneous and subcutaneous blood flow measured by CdTe(Cl) minidetectors in normal and psoriatic skin. *J Invest Dermatol* 86: 109-114, 1986.
7. Breathnach SM: Drug reactions. In, Rook/Wilkinson/Ebling Textbook of Dermatology (Champion RH, Burton JL, Ebling FJG, eds), ed 5, pp 2961-3035. London, Blackwell Scientific Publications, 1992.