

Tufted Hair Folliculitis After Scalp Injury

José Carlos Fernandes, MD, Porto, Portugal

Teresa Martine Correia, MD, Porto, Portugal

Filomena Azevedo, MD, Porto, Portugal

José Mesquita-Guimarães, MD, Porto, Portugal

We describe the case of a 38-year-old epileptic man with tufted hair folliculitis. The condition started 5 years ago after a scalp laceration that had been sustained 3 months earlier during an epileptic crisis. There then appeared a circumscribed inflammatory bulging lesion (with exudation and crusts) that evolved to scarring alopecia with tufts of 20 to 30 apparently normal hair shafts. Results of bacteriologic examination of pus extruding from the dilated follicular ostia revealed Staphylococcus aureus. The cutaneous pathologic examination showed polymorphous inflammatory exudate in the upper and mid dermis, which was mostly perifollicular, and the presence of normal and independent follicles in the deep dermis, which, while ascending, converged to a common dilated follicular channel. The patient was treated successively with oral flucloxacillin, erythromycin, ciprofloxacin, and amoxicillin/clavulanic acid and with topical application of erythromycin, clindamycin, povidone iodine, and ketoconazole. Transient improvement was followed by recurrence and enlargement of the affected area.

Tufted hair folliculitis is a rare condition, described for the first time by Tagami in 1970 as “numerous multiple hairs.”¹ The term *tufted hair folliculitis* was first used by Smith and Sanderson.² Nineteen new cases have been published subsequently.³⁻¹²

Tufted hair folliculitis is characterized by the appearance of 1 or more inflammatory and exudating plaque lesions on the scalp that evolve slowly with peripheral extension. They result in scarring alopecia with sclerotic, erythematous, shining skin, from which tufts of 5 to 30 apparently normal hair shafts emerge through dilated follicular openings.

It occurs in patients of both genders, with a male-female ratio of 2.7:1. In the cases described, patients

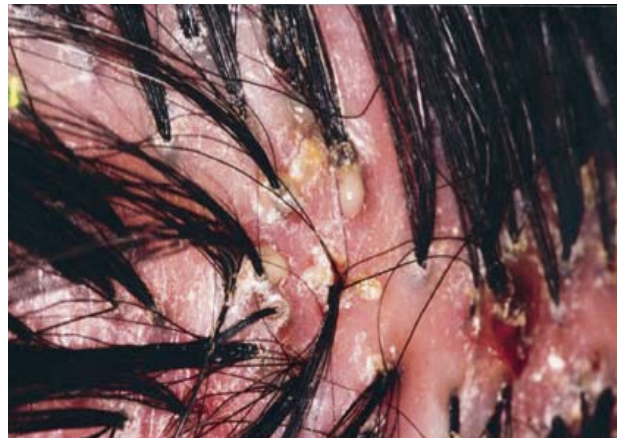

Figure 1. Area of scarring alopecia, with erythema, crusts, pustules, and tufts of normal-appearing hairs.

are usually between the ages of 19 and 68 years, and the lesion is usually located in the parietal and occipital areas. The condition frequently worsens, with peripheral extension of the inflammation that leads to cicatricial alopecia and tufts in previously normal scalp areas.⁷

Case Report

A 38-year-old man presented with a 4-cm inflammatory, bulging, exudating, and crusted lesion at the vertex. It was close to a scar caused by an injury sustained 3 months earlier during an epileptic seizure. He had been epileptic since the age of 4 years, after brain surgery for the treatment of a left frontal abscess.

The lesion was initially diagnosed as a fungal kerion and treated with griseofulvin for 2 months, without success. The lesion remained inflammatory, round, elevated, well circumscribed, and 10 cm in diameter, with scarring alopecia from which emerged tufts of 20 to 30, apparently normal, hair shafts in rows about 1 cm apart that resembled hair implants (Figure 1).

When pressure was exerted on the inflammatory area, a purulent exudate extruded through the follicular openings. Results of bacteriologic tests showed *Staphylococcus aureus* sensitive to ampicillin, cephalothin, ciprofloxacin, clindamycin, oxacillin,

Drs. Fernandes, Correia, Azevedo, and Mesquita-Guimarães are from the Department of Dermatology and Venereology, Hospital de São João, Porto, Portugal.

Reprints not available from the author.

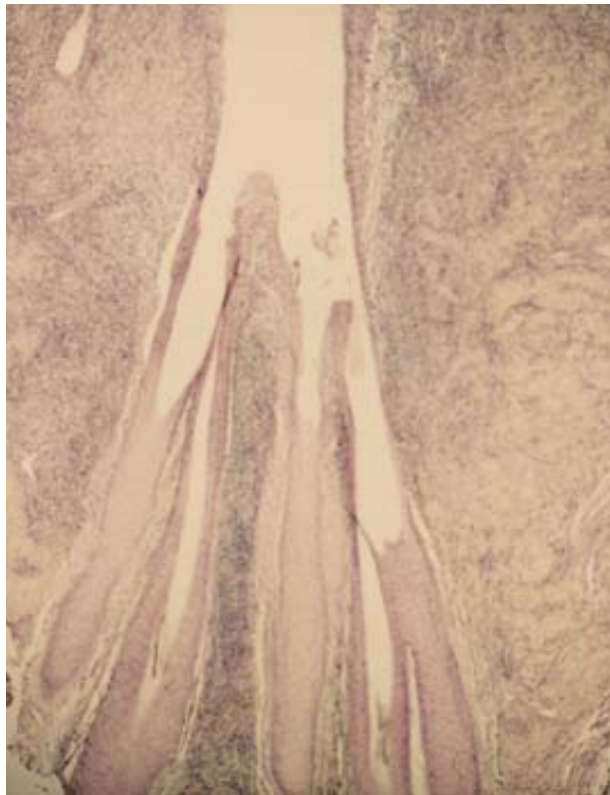


Figure 2. Convergence of several follicles into a common dilated infundibulum (H&E).

tetracycline, trimethoprim sulfamethoxazole, and vancomycin. Several fungal cultures were negative.

The remainder of the scalp was normal; there were no enlarged cervical lymph nodes, and the patient was in generally good health. Examination of a skin biopsy specimen showed an inflammatory process in the perifollicular dermis, with neutrophils, lymphocytes, plasma cells, and eosinophils. There was interfollicular fibrosis in the upper dermis, and the hairs merged into a common follicular ostium (Figure 2). The general analytical study was normal or negative.

For the 5 years since the lesions had appeared, the patient was treated systemically with flucloxacillin, erythromycin, ciprofloxacin, and amoxicillin/clavulanic acid and topically with erythromycin, clindamycin, povidone iodine, and ketoconazole. However, because the patient experienced a worsening of epileptic seizures when taking antibiotics, he discontinued the medication prematurely. As a result, the affected area grew centrifugally until it covered the entire central portion of the scalp, leaving a normal rim of about 5 cm (Figure 3).

Recently, with the addition of vigabatrin to carbamazepine and phenobarbital (the antiepileptic agents he had been taking previously), better control of the epilepsy was achieved, allowing the patient to

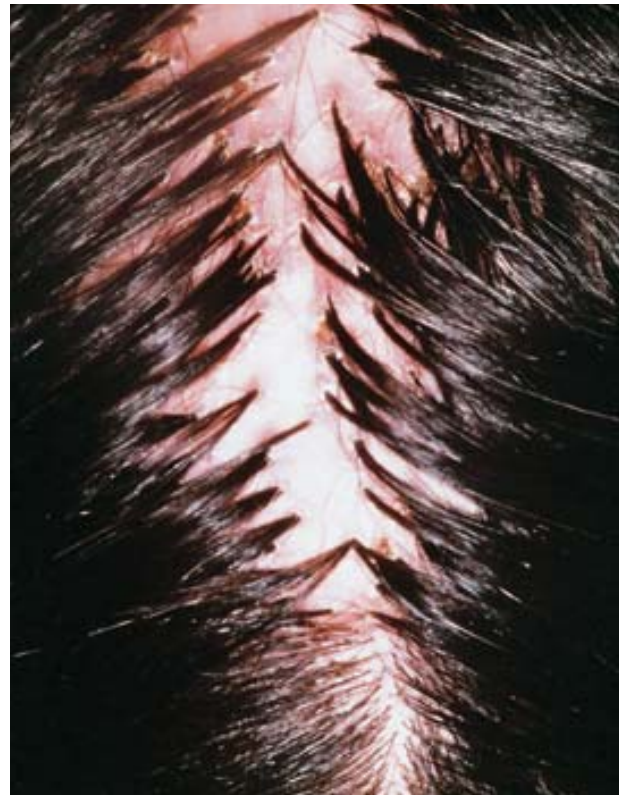

Figure 3. Transition between the central affected area and the peripheral, normal-appearing scalp.

continue with systemic amoxicillin/clavulanic acid (625 mg every 8 h) for 3 weeks and then with flucloxacillin (500 mg every 8 h) for 4 weeks. A marked reduction of the inflammatory signs was observed but only during treatment periods.

Comment

The cause of tufted hair folliculitis is unknown, but several explanations have been proposed. It is considered by some authors as a variant of folliculitis decalvans.^{1,13} Since *S aureus* is almost always isolated in this situation, it may be a recurrent staphylococcal folliculitis with fibrosis in the interfollicular areas and consequent approximation of the follicles, with hairs emerging in tufts.^{2,8} In addition, it has been suggested that tuft formation is due to telogenic hairs being retained around an anagenic follicle,⁶ but it has since been demonstrated that most follicles in a tuft are anagenic.⁸ It also may be a localized nevus malformation, with tufts present since birth but becoming apparent only when infection occurs with the destruction of some of the follicles.⁵ The compound follicles are more prone to chronic infection by *S aureus*,¹⁴ but this theory does not explain the centrifugal nature of the lesions nor the appearance of tufts in previously normal scalp areas. Pujol et al¹⁵ suggest that hair tufting may be a

nonspecific secondary phenomenon that may occur in several exudative inflammatory diseases of the scalp, including dissecting cellulitis of the scalp, folliculitis decalvans, and folliculitis keloidalis.

In our patient, the lesion started shortly after he sustained a scalp injury. In 4 clinical cases described previously, there was also a reference to traumatic or surgical injury to the scalp sometime before the onset of dermatosis.^{8,11} However, most authors give little importance to this fact and mention it without further consideration. The diagnosis of tufted hair folliculitis is usually late, and minor trauma occurring sometime before might not be mentioned by the patient. As a result, its frequency may not be appreciated. It seems reasonable that injuries may allow the installation of a staphylococcal infection that, for reasons not yet understood, become chronic and could be caused by host factors, such as an immunologic defect that results in greater susceptibility to *S aureus* infection.⁷

The most significant fact in the pathology of tufted hair folliculitis is the convergence of several follicles toward a common follicular duct. The lowest portions of the follicles are normal, each with a papilla and independent internal and external root sheaths, which differentiate them from pili multigemini.¹⁶ In the superior and mid dermis, there is an inflammatory infiltrate with neutrophils, eosinophils, lymphocytes, and plasma cells, mostly perifollicular. Rupture of the follicular wall and the presence of hair debris in the macrophage cytoplasm and in multinucleate giant cells have been reported^{3,6-8,11} but were not seen in our patient.

Antibiotics administered systemically and topically have been the most commonly used treatment. However, complete cures are rare.^{8,11} As a rule, the antibiotics allow reasonable control of the inflammatory signs, but discontinuing their use leads—after a period from weeks to months—to the reappearance of lesions.⁷

Isotretinoin,⁷ zinc sulfate,^{7,8} and rifampin⁸ are used without great success. Surgery, while technically fea-

sible,⁵ seems to be effective only at an early stage, which is why early diagnosis is essential.

REFERENCES

1. Tagami H. Numerous multiple hairs. *Arch Dermatol*. 1970; 102:309-312.
2. Smith NP, Sanderson KV. Tufted folliculitis of the scalp. *J R Soc Med*. 1978;71:606-608.
3. Metz J, Metz G. Navoide bundelhaare beim menschen. *Hautarzt*. 1978;29:586-589.
4. Oakley A, Scollay D. Hair bundles. A presentation of folliculitis. *Aust J Dermatol*. 1985;26:139-143.
5. Tong AKF, Baden HP. Tufted hair folliculitis. *J Am Acad Dermatol*. 1989;21:1096-1099.
6. Dalziel KL, Telfer NR, Wilson CL, et al. Tufted folliculitis: a specific bacterial disease? *Am J Dermatopathol*. 1990;12:37-41.
7. Pujol RM, Matias-Gufu X, Garcia-Patos V, et al. Tufted-hair folliculitis. *Clin Exp Dermatol*. 1991;16:199-201.
8. Luelmo-Aguilar J, Gonzalez-Castro U, Castells-Rodellas A. Tufted hair folliculitis: a study of four cases. *Br J Dermatol*. 1993;128:454-457.
9. Offidani A, Cellini A, Giangiacomi M, et al. Folliculite épilante de quinquaud et cheveux en touffes. *Ann Dermatol Venereol*. 1994;121:319-321.
10. Secch T, Balme B, Thomas L, et al. Folliculites en touffes du cuir chevelu. *Ann Dermatol Venereol*. 1994;121:479-481.
11. Veraldi S, Grimalt R, Cappio F, et al. Tufted hair folliculitis. *Eur J Dermatol*. 1995;5:125-127.
12. Lombardo M, Collina G, Giroloni G. Guess what! (tufted hair folliculitis). *Eur J Dermatol*. 1996;6:75-76.
13. Champion RH, Burton JL, Ebling FJG. In: *Rook/Wilkinson/Ebling: Textbook of Dermatology*. 5th ed. Oxford, England: Blackwell Scientific Publications; 1992:2600-2601.
14. Loewenthal LJA. "Compound" and grouped hairs of the human scalp: their connection with follicular infections. *J Invest Dermatol*. 1947;8:263-273.
15. Pujol RM, García-Patos V, Ravella-Mateu A, et al. Tufted hair folliculitis: a specific disease? *Br J Dermatol*. 1994;130: 259-260.
16. Pinkus H. Multiple hairs: report of two cases of pili multigemini and discussion of some other anomalies of the pilary complex. *J Invest Dermatol*. 1951;17:291-301.