

# Nonendemic Pemphigus Foliaceus Presenting as Fatal Bullous Exfoliative Erythroderma

Hossein C. Nousari, MD, Baltimore, Maryland  
Margaret Moresi, MD, Baltimore, Maryland  
Mitchell Klapper, MD, Baltimore, Maryland  
Grant J. Anhalt, MD, Baltimore, Maryland

*Pemphigus foliaceus* is a cutaneous autoimmune blistering disease that is characterized by lower morbidity and mortality than those observed in pemphigus vulgaris or paraneoplastic pemphigus. However, erythrodermic forms of the endemic variant of pemphigus foliaceus have been associated with a higher mortality. We report a case of nonendemic pemphigus foliaceus that presented as fatal bullous exfoliative erythroderma, and thus, we will emphasize the inclusion of this entity in the differential diagnosis and the use of skin direct immunofluorescence in the evaluation of patients with erythroderma.

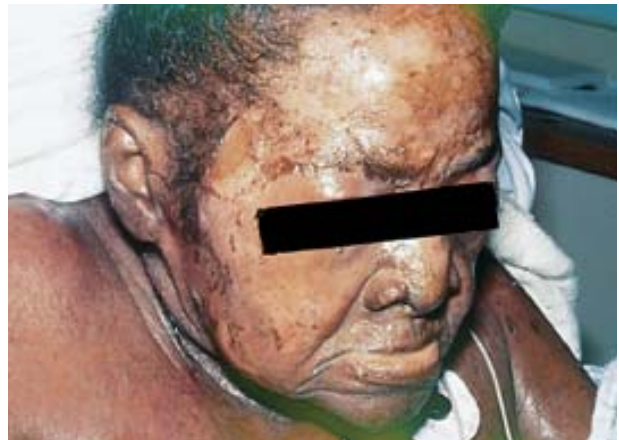**P**emphigus foliaceus is a rare autoimmune blistering disorder characterized by the presence of pathogenic IgG antibodies against desmoglein 1, an epidermal desmosomal protein.<sup>1,3</sup> It is characterized by discrete centripetally distributed scaling and erosive plaques and the absence of mucosal involvement. In contrast to pemphigus vulgaris and paraneoplastic pemphigus, its morbidity and mortality are low. Aggressive generalized forms have been reported in its endemic variant, which is prevalent in some areas of Brazil and other South American countries.<sup>4,5</sup> We present a patient with a severe bullous exfoliative erythrodermic form of nonendemic pemphigus foliaceus.

## Case Report

A 69-year-old black female was admitted with a 2-week history of progressive cutaneous denudation.

Drs. Nousari, Moresi, Klapper, and Anhalt are from the Department of Dermatology, Johns Hopkins Medical Institutions, Baltimore, Maryland.

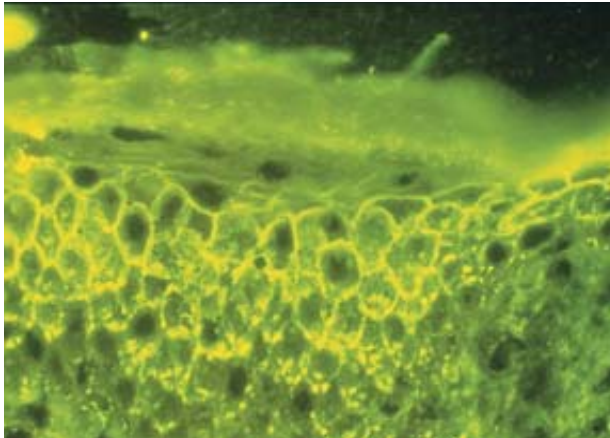
Reprints: Hossein C. Nousari, MD, Division of Dermatoinmunology, Ross Research Building, Room 771, 720 Rutland Ave, Johns Hopkins School of Medicine, Baltimore, MD 21205.



**Figure 1.** Extensive superficial erosions on the head and neck area.

Her medical history was significant for cirrhosis, Alzheimer's dementia, hypothyroidism, and hypertension. Medications included diltiazem, levothyroxine, lactulose, risperidone, and ranitidine. There was no history of new medications or recent traveling. Personal and familial histories of cutaneous disorders were unremarkable. On physical examination, she had confluent, erythematous-based, superficial denudation involving about 80% of the body surface (Figure 1) and discrete areas of desquamation on the extremities. Nikolsky's sign was positive. No mucosal involvement was present. Her complete blood cell count, creatinine, urea nitrogen, aminotransferases, bilirubin, alkaline phosphatase, glucose, electrolytes, and urinalysis were all reported within normal limits.

Both fresh-frozen and formalin-fixed histopathologic skin specimens showed subcorneal splitting and superficial perivascular lymphomonocytic infiltrate. Direct immunofluorescence examination of perilesional skin revealed IgG and C3 deposition on the cell surfaces of superficial keratinocytes (Figure 2).



**Figure 2.** Direct immunofluorescence examination of perilesional skin showing linear and granular IgG deposition on the surfaces of superficial keratinocytes (original magnification  $\times 800$ ).

Indirect immunofluorescence examination of the patient's serum using monkey esophagus substrate revealed antiepidermal IgG autoantibodies at a titer of 1280.

The patient was treated with 60 mg of oral prednisone daily. The eruption began to slowly subside within the first 7 days; however, her clinical course was complicated by *Pseudomonas aeruginosa* and *Staphylococcus epidermidis* sepsis and by multiorgan dysfunction syndrome. She died after 24 days in the hospital.

### Comment

Toxic epidermal necrolysis syndrome, pemphigus vulgaris, paraneoplastic pemphigus, other variants of pemphigus foliaceus,<sup>6</sup> and other exfoliative erythroderma-associated dermatoses were excluded

as diagnoses based on the absence of their typical clinical, epidemiologic, histologic, and immunofluorescence features. The diagnosis of staphylococcal scalded skin syndrome was formerly entertained because of the absence of mucosal involvement and the presence of subcorneal splitting on histologic examination. However, the absence of renal failure, the inability to isolate *Staphylococcus aureus* from cultures, and the positive findings on the immunofluorescence examination ruled out this condition.

Based on this unusual case, we suggest that skin immunofluorescence examination be included in the evaluation of both bullous and nonbullous forms of generalized exfoliative erythroderma.

### REFERENCES

1. Rock B, Martins CR, Theofilopoulos AN, et al. The pathogenic effect of IgG4 autoantibodies in endemic pemphigus foliaceus. *N Engl J Med.* 1989;320:1463-1469.
2. Labib RS, Izumi H, Santana H, et al. Purification of immunoprecipitated pemphigus foliaceus antigen fragment and its use in radioimmunoassay. *J Invest Dermatol.* 1992;99:819-823.
3. Amagai M, Hashimoto T, Green KJ, et al. Antigen-specific immunoabsorption of pathogenic autoantibodies in pemphigus foliaceus. *J Invest Dermatol.* 1995;104:895-901.
4. Diaz LA, Sampaio SAP, Rivitti EA, et al. Endemic pemphigus foliaceus (fogo selvagem), I: clinical features and immunopathology. *J Am Acad Dermatol.* 1989;20:657-669.
5. Robledo MA, Prada S, Jamarillo D, et al. South American pemphigus foliaceus: study of an epidemic in El Bagre and Nechi, Colombia, 1982 to 1986. *Br J Dermatol.* 1988;118:737-744.
6. Noursari HC, Anhalt GJ. Bullous skin diseases. *Curr Op Immunol.* 1995;7:844-852.