

# Eruptive Xanthomas and Chest Pain in the Absence of Coronary Artery Disease

Patricia P. Hentges, BA, Omaha, Nebraska

Christopher J. Huerter, MD, Omaha, Nebraska

## GOAL

To describe a case of eruptive xanthoma and chest pain in a patient without coronary artery disease

## OBJECTIVES

Upon completion of this activity, dermatologists and general practitioners should be able to:

1. Identify the manifestations and causes of hypertriglyceridemia.
2. Describe the characteristic lesions of eruptive xanthoma.
3. Discuss chylomicronemia syndrome, its presentation, and diagnosis.

CME Test on page 308.

This article has been peer reviewed and approved by Michael Fisher, MD, Professor of Medicine, Albert Einstein College of Medicine. Review date: March 2001.

This activity has been planned and implemented in accordance with the Essentials and Standards of the Accreditation Council for Continuing Medical Education through the joint sponsorship of Albert Einstein College of Medicine and Quadrant HealthCom, Inc. The Albert Einstein College of Medicine is accredited by the

ACCME to provide continuing medical education for physicians.

Albert Einstein College of Medicine designates this educational activity for a maximum of 1.0 hour in category 1 credit toward the AMA Physician's Recognition Award. Each physician should claim only those hours of credit that he/she actually spent in the educational activity.

This activity has been planned and produced in accordance with ACCME Essentials.

*Because hyperlipidemia may present as xanthomas, a dermatologist may be the first to diagnose these skin lesions and associated lipid abnormalities.<sup>1</sup> Xanthomas are of concern because of their association with coronary artery disease and pancreatitis. We describe the case of a 40-year-old white male with chest pain and eruptive xanthomas. Laboratory tests revealed severe hypercholesterolemia, hypertriglyceridemia, and diabetes mellitus, and the histopathology of the skin lesions was consistent with eruptive xanthomas. Surprisingly, even with overwhelming risk factors for both atherosclerosis and pancreatitis,*

*this patient did not show evidence of either disease process. After initiating therapy for the diabetes and hyperlipidemia, the patient has had no recurrence of chest pain, and the skin lesions have gradually resolved. The most likely explanation for this patient's pattern of symptoms and laboratory results is the chylomicronemia syndrome, which can be seen in patients with type I or type V hyperlipoproteinemia.*

Because hyperlipidemia may manifest as various dramatic cutaneous abnormalities, a dermatologist is often the first to diagnose these skin lesions and associated lipid abnormalities.<sup>1</sup> Once xanthomas are discovered, it is important to search for and treat the underlying hyperlipidemia to prevent complications, such as coronary artery disease and pancreatitis.<sup>1-3</sup> There are 4 types of xanthomas associated with disorders of lipid

Ms. Hentges and Dr. Huerter are from Creighton University School of Medicine, Omaha, Nebraska. Ms. Hentges is a medical student, and Dr. Huerter is Associate Professor and Chief, Division of Dermatology.

Reprints: Christopher J. Huerter, MD, 601 N 30th St, Suite 5850, Omaha, NE 68131.

**Types of Xanthomas and the Associated Hyperlipoproteinemia<sup>1,4,5</sup>**

Type of Xanthoma	Associated Hyperlipoproteinemia
Tendinous	Hypercholesterolemia
Planar	Hypercholesterolemia and/or hypertriglyceridemia
Tuberous	Hypercholesterolemia and/or hypertriglyceridemia
Eruptive	Hypertriglyceridemia

metabolism (Table).<sup>1,4,5</sup> Tendinous, planar, and tuberous xanthomas are usually seen in patients with hypercholesterolemia, while eruptive xanthomas are usually indicative of hypertriglyceridemia.<sup>1,4,5</sup>

Most plasma triglycerides are carried in the form of very low density lipoproteins and chylomicrons.<sup>6</sup> When triglyceride levels are greater than 1000 mg/dL, it is usually because of the accumulation of chylomicrons, very low density lipoproteins, and lipoprotein remnant particles.<sup>2,7</sup> Eruptive xanthomas are most commonly seen when serum triglyceride levels are in excess of 2000 mg/dL, and result from the phagocytosis of triglyceride-rich lipoproteins by macrophages in the skin.<sup>1,2,5,7,8</sup> The characteristic lesions erupt suddenly in groups over the extensor surfaces of the arms, legs, and buttocks and have the appearance of small yellow papules surrounded by erythematous halos.<sup>4,5,8,9</sup> The xanthomas usually measure 1 to 4 mm in diameter.<sup>1,4,5</sup>

Other manifestations of hypertriglyceridemia may include acute pancreatitis and lipemia retinalis.<sup>1,2,7,8</sup> While it is well established that increased low density lipoprotein cholesterol is a risk factor for coronary artery disease, the relationship between increased triglycerides and atherosclerosis is more controversial.<sup>6,9,12</sup> We report a case of eruptive xanthomas in a patient also manifesting symptoms suggestive of coronary artery disease.

**Case Report**

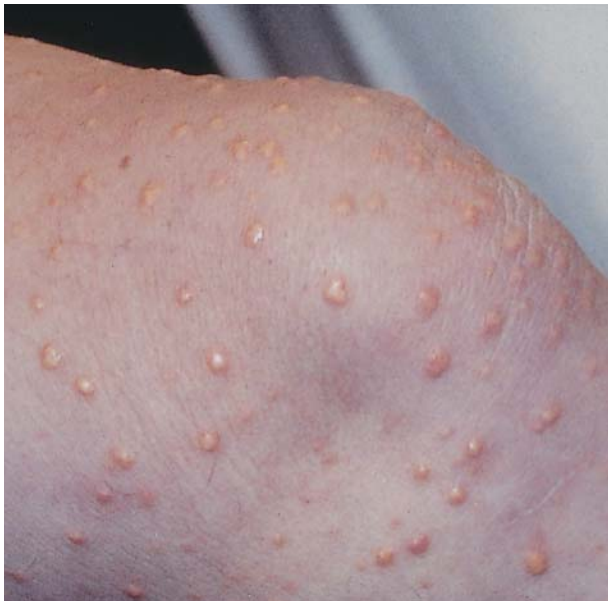A 40-year-old white male presented with episodic chest pain, dyspnea, and an occasionally pruritic rash that developed over a 2-month period. Other symptoms included polydipsia, polyuria, and polyphagia. He denied having any abdominal pain and was not taking any medications. The patient's social history included cigarette use since his teens and occasional consumption of small amounts of alcohol. There was a family history of adult-onset

diabetes mellitus, and the patient's parents died in middle adulthood from unspecified causes.

Physical examination revealed mild obesity and moderate hypertension. A large number of yellow papules with erythematous halos were present on his back and extensor aspects of his arms and legs (Figure 1). There was no overt jaundice of the skin, and funduscopic examination revealed lipemia retinalis. Chest discomfort and dyspnea were experienced during exercise stress testing, and the electrocardiogram revealed ST depression in the inferior and anterolateral leads. The patient was admitted to the hospital and left heart catheterization with angiography showed normal coronary arteries and a normal ejection fraction. Fasting laboratory results included the following: serum glucose, 398 mg/dL (normal, 75–110 mg/dL); cholesterol, 1067 mg/dL (normal, <200 mg/dL); and triglycerides, 11,700 mg/dL (normal, <250 mg/dL). The plasma was lipemic, and lipoprotein electrophoresis could not be performed because of greatly elevated triglycerides.

A skin biopsy was obtained, and the histopathology was consistent with eruptive xanthomas (Figure 2). Additional laboratory results included aspartate aminotransferase, 47 U/L (normal, 10–34 U/L); alanine aminotransferase, 69 U/L (normal, 8–63 U/L); total bilirubin, 9.5 mg/dL (normal, 0.2–1.3 mg/dL); and lipase, 272 U/L (normal, 0–190 U/L). Complete blood count, amylase levels, and thyroid-stimulating hormone levels were within normal limits. Insulin was given to control the hyperglycemia, and the hyperlipidemia was treated with fenofibrate. The patient was started on metoprolol for hypertension.

An examination 2 months later showed near resolution of the patient's cutaneous lesions. New laboratory results revealed cholesterol, 132 mg/dL; triglycerides, 229 mg/dL; low density lipoprotein,



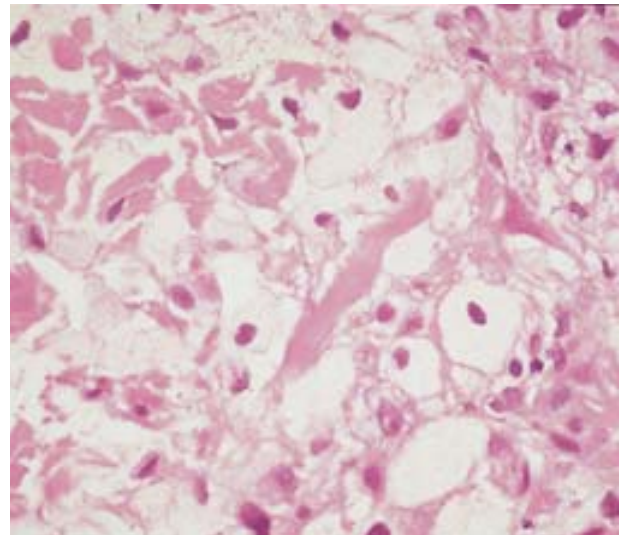
**Figure 1.** Eruptive xanthomas on the extensor surface of the knee.

48 mg/dL (normal, <130 mg/dL); and high density lipoprotein, 38 mg/dL (normal, 35–55 mg/dL). Fasting blood sugar levels ranged between 102 and 135 mg/dL. The patient denied having any recent chest pain or dyspnea.

### Comment

Our patient was diagnosed with severe fasting hypercholesterolemia and hypertriglyceridemia associated with uncontrolled, recent-onset type 2 diabetes mellitus. Eruptive xanthomas presenting in adults are usually indicative of type V hyperlipoproteinemia.<sup>1-3,7,9,10</sup> In type V hyperlipoproteinemia, the hypertriglyceridemia and chylomicronemia characteristically seen appear to be the result of an underlying genetic defect in the lipolysis of triglyceride-rich lipoproteins, combined with secondary causes of elevated triglycerides.<sup>1,2,4,7,8</sup> Genetically acquired lipoprotein abnormalities seen in type V hyperlipoproteinemia include familial combined hyperlipidemia, familial hypertriglyceridemia, lipoprotein lipase deficiency, or familial apoprotein CII deficiency.<sup>1,2,4,7</sup> Secondary causes of hypertriglyceridemia include diabetes, obesity, hypothyroidism, nephrotic syndrome, alcohol consumption, excessive use of simple sugars and saturated fats, and drugs, including isotretinoin and intravenous miconazole.<sup>1,2,4,5,7,8,10</sup>

Although the relationship between hypertriglyceridemia and atherosclerosis is uncertain and controversial, our patient did present with many of the well-known risk factors for coronary artery disease, including hypercholesterolemia, moderate hypertension, diabetes mellitus, and tobacco use.<sup>6,9-13</sup>



**Figure 2.** Skin biopsy showing foamy histiocytes infiltrating the dermis (H&E, original magnification  $\times 400$ ).

Surprisingly, considering the patient's risk factors, presenting symptoms, positive stress test, and skin lesions, we found no evidence of atherosclerosis with coronary catheterization. Other possible etiologies for this patient's chest pain and dyspnea include coronary vasospasm or the chylomicronemia syndrome. Resolution of the dyspnea and chest pain with treatment of the hyperlipidemia supports the diagnosis of the chylomicronemia syndrome.

The chylomicronemia syndrome, which can be seen in patients with type I or type V hyperlipoproteinemia, is the most likely explanation for this patient's interesting combination of symptoms and test results.<sup>1,2,7</sup> Patients who have the chylomicronemia syndrome are noted to have both subjective and objective shortness of breath.<sup>2,7</sup> These patients also commonly present with eruptive xanthomas, lipemia retinalis, and mild elevations in liver transaminases, as seen in our patient.<sup>2,7</sup> They also have been known to have artificially elevated levels of bilirubin, which may explain our patient's marked increase of total bilirubin in the absence of jaundice.<sup>2</sup>

The most common and troubling manifestation of chylomicronemia syndrome is abdominal pain, indicative of pancreatitis.<sup>2,7</sup> Our patient denied having abdominal pain, and laboratory results were not suggestive of acute pancreatitis. Although this patient had overwhelming risk factors for both atherosclerosis and pancreatitis and presented with dramatic signs and symptoms, laboratory and diagnostic studies did not show evidence of either disease process.

## REFERENCES

1. Parker F. Xanthomas and hyperlipidemias. *J Am Acad Dermatol*. 1985;13:1-30.
2. Brunzell JD, Bierman EL. Chylomicronemia syndrome: interaction of genetic and acquired hypertriglyceridemia. *Med Clin North Am*. 1982;66:455-468.
3. Gotto AM Jr. Clinical diagnosis of hyperlipoproteinemia. *Am J Med*. 1983;74:5-9.
4. Crowe MJ, Gross DJ. Eruptive xanthoma. *Cutis*. 1992;50:31-32.
5. Pistone GA. Pathology quiz case 1: eruptive xanthoma (associated with type 5 hyperlipoproteinemia). *Arch Dermatol*. 1984;120:1366-1368.
6. Ginsberg HN. Lipoprotein metabolism and its relationship to atherosclerosis. *Med Clin North Am*. 1994;78:1-20.
7. Santamarina-Fojo S. The familial chylomicronemia syndrome. *Endocrinol Metab Clin North Am*. 1998;27:551-567.
8. Teltscher J, Silverman RA, Stork J. Eruptive xanthomas in a child with the nephrotic syndrome. *J Am Acad Dermatol*. 1989;21:1147-1149.
9. Archer CB, MacDonald DM. Eruptive xanthomata in type V hyperlipoproteinaemia associated with diabetes mellitus. *Clin Exp Dermatol*. 1984;9:312-316.
10. Davignon J, Genest J Jr. Genetics of lipoprotein disorders. *Endocrinol Metab Clin North Am*. 1998;27:521-550.
11. Austin MA, Hokanson JE. Epidemiology of triglycerides, small dense low-density lipoprotein, and lipoprotein(a) as risk factors for coronary heart disease. *Med Clin North Am*. 1994;78:99-115.
12. Schaefer EJ. Familial lipoprotein disorders and premature coronary artery disease. *Med Clin North Am*. 1994;78:21-39.
13. Hunninghake DB. Diagnosis and treatment of lipid disorders. *Med Clin North Am*. 1994;78:247-257.

### DISCLAIMER

The opinions expressed herein are those of the authors and do not necessarily represent the views of the sponsor or its publisher. Please review complete prescribing information of specific drugs or combination of drugs, including indications, contraindications, warnings, and adverse effects before administering pharmacologic therapy to patients.

### FACULTY DISCLOSURE

The Faculty Disclosure Policy of the College of Medicine requires that faculty participating in a CME activity disclose to the audience any relationship with a pharmaceutical or equipment company that might pose a potential, apparent, or real conflict of interest with regard to their contribution to the program. It is required by the Accreditation Council for Continuing Medical Education that each author of a CME article disclose to the participants any discussion of an unlabeled use of a commercial product or device or an investigational use not yet approved by the Food and Drug Administration. Ms. Hentges and Dr. Huerter report no conflict of interest. Dr. Fisher reports no conflict of interest.