

Sarcoidosis With Giant Parotomegaly

Shun Ohtsuka, MD, Tochigi, Japan
Akihiko Yanadori, MD, Tochigi, Japan
Hideyuki Tabata, MD, Tochigi, Japan
Akio Yamakage, MD, Tochigi, Japan
Soji Yamazaki, MD, Tochigi, Japan

We report the case of a 63-year-old man with bilateral parotid gland sarcoidosis. Giant, elastic, hard, subcutaneous tumors had been present on the right parotid and submaxillary regions for 11 years and on the left for 1 year. The patient had had diabetes mellitus for 8 years. Noncaseating epithelioid cell granulomata were revealed histopathologically in the periductal area of the parotid gland. Bilateral hilar lymphadenopathy was noted on chest x-ray studies. Serum levels of lysozyme were increased. Levels of serum angiotensin-converting enzyme were within normal limits. Tuberculin skin reaction was positive. The tumors gradually improved after treatment with oral minocycline. Giant parotomegaly, as it occurred in this case, is very rare.

Sarcoidosis, a disease of unknown origin, causes noncaseating epithelioid cell granulomata in lymph nodes, lungs, eyes, and skin. Some authors have reported on sarcoidosis with enlarged parotid gland as an extrapulmonary lesion.^{1,2} We examined a patient with sarcoidosis accompanied by giant parotomegaly.

Case Report

A 63-year-old Japanese man presented with a right parotid and submaxillary subcutaneous node that had been present for 11 years. He also had hypertension, diabetes mellitus, and heart failure.

The node gradually increased in size, and, one year before presenting, a similar but smaller node appeared in the left parotid region. On examination, the tumors were elastic, hard, and painless, and the right tumor was partially lobular. The right submaxillary tumor (Figure 1) measured 72×67×32 mm; the left




Figure 1. Giant parotomegaly in a 63-year-old Japanese patient.

measured 43×32×13 mm. There was no facial nerve palsy, dry eye, or dry mouth.

Many routine examinations—peripheral blood cell count; liver function test; urinalysis; serum electrophoresis; and tests of blood urea nitrogen, serum electrolyte, uric acid, and serum amylase levels—yielded results within normal limits. Bilateral hilar lymphadenopathy was seen by chest x-ray studies. The serum lysozyme level was 17.6 mg/L (normal, 4.2–11.5 mg/L), and the angiotensin-converting enzyme level was 2.1 U/L (normal, 7.7–29.4 U/L). Results of testing with purified

Drs. Ohtsuka, Yanadori, Tabata, Yamakage, and Yamazaki are from the Department of Dermatology, Dokkyo University School of Medicine, Tochigi, Japan.

Reprints: Shun Ohtsuka, MD, Department of Dermatology, Dokkyo University School of Medicine, Mibu, Tochigi, 321-02, Japan.

protein derivative were 19×15/58×42 mm; CD4/CD8 ratio was 1.15 (normal, 0.6–2.9). Uveitis did not show up on ophthalmologic examination. A cardiac muscle biopsy specimen did not show signs of cardiac sarcoidosis. Cardiac catheter examination led to a diagnosis of an old myocardial infarction.

A biopsy specimen was taken from the right parotid tumor. The epidermis and dermis appeared normal. There were many ductal lumen structures (eg, part of a salivary gland in the subcutis). Some ductal lumina were enlarged and secreting. Some noncaseating granulomata composed of epithelioid cells and multinucleated giant cells were apparent in periductal areas. Marked lymphocytic infiltration was found around the granulomata (Figure 2). The walls of small vessels were thickened, and their lumina were stenosed. Polarized-light microscopic examination showed no birefringent foreign body.

We diagnosed this case as sarcoidosis of the parotid and submaxillary glands. Our patient refused hospital admission, barium scintigraphy, magnetic resonance imaging, and corticosteroid treatment. He was treated with oral minocycline 100 mg per day, and his tumors decreased gradually over 3 months.

Comment

On histopathologic examination, our patient showed typical sarcoidosis in the extended parotid and submandibular gland. To our knowledge, this is the first reported case of sarcoidosis with giant parotomegaly. Siltzbach et al¹ found enlarged parotid glands in 104 (6.5%) of all 1609 patients with sarcoidosis worldwide; and Greenberg et al² found enlarged parotid glands in 23 (5.9%) of 388 patients with histologically confirmed generalized sarcoidosis. We could find no reports of submandibular gland swelling, although many patients with sarcoidosis have histologically documented sarcoidosis of the submandibular gland. Perhaps investigators overlook swelling of the submandibular gland and neither examine a biopsy specimen nor perform gallium scintigraphy.

Several factors may account for the enormous size of our patient's tumors. First, his disease had lasted a long time—11 years. In Japan, sarcoidosis detection has involved x-ray examination (50%), reporting of subjective symptoms (38%), and other methods (12%).³ Our patient had been unaware of any symptoms and had never been examined. His indifference may have contributed to this situation—he ignored the lump until it became unavoidable.²

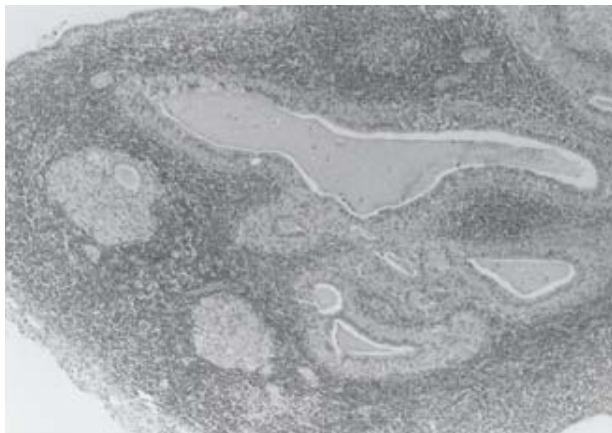


Figure 2. Photomicrograph shows noncaseating granulomata composed of epithelioid cells and multinucleated giant cells with enlarged salivary gland duct. Marked lymphocytic infiltration is evident around the granulomata (H&E, original magnification ×25).

Second, a secretory disturbance of the parotid and submandibular glands may have led to secondary swelling and a further increase in lesion size. The patient did not complain of dry mouth, and his serum amylase level was within normal limits. However, parts of the ducts were shown histopathologically to be so extended and collapsed that they could not secrete saliva, and others were so pressured and occluded by sarcoid granulomata that saliva accumulated in enlarged glands.³

Third, the patient's diabetes mellitus may have modified his sarcoidosis. Microangiopathy, usually seen in diabetes, is also seen in sarcoidosis. Epithelioid cells are thought to produce endothelial cell growth factor. Diabetic microangiopathy, a common pathophysiologic change, may act catalytically in sarcoidosis and enlarge the salivary gland lesion. Further, older patients with diabetes have increased inflammation, another factor that may contribute to enlargement of these lesions.

REFERENCES

1. Siltzbach LE, James DG, Neville E, et al. Course and prognosis of sarcoidosis around the world. *Am J Med.* 1974;57:847-852.
2. Greenberg G, Anderson R, Sharpstone P, et al. Enlargement of parotid gland due to sarcoidosis. *BMJ.* 1964;2:861-862.
3. Hosoda Y, Hiraga Y, Odaka M. A cooperative study of sarcoidosis in Asia and Africa: analytic epidemiology. *Ann N Y Acad Sci.* 1976;278:355-367.