

Eruptive Dermatofibromas in a Kindred

Curt Samlaska, MD, FACP; Scott Bennion, MD, FACP

Benign fibrous histiocytomas of the skin, or dermatofibromas, are common fibrohistiocytic tumors that affect women more commonly than men. Proposed causes range from a reactive process to a neoplastic growth. We report on a family affected with numerous dermatofibromas, suggesting that there also may be a genetic cause to this common tumor.

Case Report

A 71-year-old man presented for evaluation of numerous firm skin nodules that began to develop when he was in his 20s and early 30s. A number of the lesions had been removed, particularly those in the head and neck regions. The patient was very young when his father died, and he did not know if his mother had similar lesions. All 3 of his children had similar findings (Figure 1).

On clinical examination, there were more than 60 firm flesh-colored to reddish-brown papulonodules distributed over the lower extremities, predominantly the pretibial regions (Figure 2). Smaller lesions demonstrated a positive dimple sign. Nodules also were found on the arms and the head and neck regions.

The results of multiple biopsies showed epidermal hyperplasia with focal induction. There were dermal tumors composed of plump spindle cells with pale eosinophilic cytoplasm in a collagenous stroma and groups of histiocytes with pale-staining cytoplasm.

The patient's oldest daughter, aged 46 years, had more than 100 lesions, predominantly involving the lower legs (Figure 3). There were more than 20 on the arms. Her first lesion occurred at age 15 years, and new lesions continue to appear. Her oldest daughter had a single lesion on her buttock. The results of 2 biopsies interpreted the lesions as dermatofibromas.

The patient's middle daughter, aged 45 years, had 20 lesions on the left leg, 10 on the right leg, 2 on the left arm, 4 involving the right arm, and a solitary lesion on her abdomen, as well as solitary lesions in other areas. Most of the leg lesions were below the knees.

The patient's youngest daughter, aged 41 years, had more than 100 lesions on her legs, 2 on her buttocks, and a few on the arms. In the 5 cases, there was no history supporting an association with pregnancy, malignancies, or unusual exposure to arthropods.

Comment

References in the literature to familial dermatofibroma are sparse. Excluding the series reported here, to our knowledge, there is only one other well-documented family reported by Roberts et al.¹ In their series, which spanned 3 generations, the male proband died of a malignant fibrous histiocytoma of the lung. The 5 other family members with dermatofibromas also were men. Metastasizing dermatofibromas have been suggested as a possibility by some authors, although dermatofibrosarcoma protuberans also must be a consideration.^{1,2}

In our series, all 3 offspring from the proband had dramatic disease, suggesting a familial cause. Although the grandchildren were young, a clinical lesion was detected on the oldest child. The inheritance pattern in this series may be autosomal dominant or X-linked dominant.

Dermatofibromas are common and have a predilection for the limbs, particularly the lower extremities. It is not unusual for them to be multiple. Eruptive dermatofibromas (defined as >15 lesions) have been reported rarely in healthy individuals. More commonly, the lesions are seen in patients with immunosuppression by human immunodeficiency virus, mycosis fungoides, systemic lupus, myasthenia gravis, Sjögren syndrome, ulcerative colitis, pemphigus vulgaris, and atopic dermatitis.³⁻⁵ Pregnancy and immunosuppressive therapy also may be risk factors for developing eruptive dermatofibromas.^{3,6} None of our patients had any of these disorders or noted an association with pregnancy.

Dr. Samlaska is from the University of Nevada School of Medicine, Henderson. Dr. Bennion is from the Department of Dermatology, University of Colorado Health Science Center, Denver.
Reprints: Curt Samlaska, MD, 100 N Green Valley Pkwy, Suite 315, Henderson, NV 89074 (e-mail: csamlaska@aol.com).

Eruptive Dermatofibromas

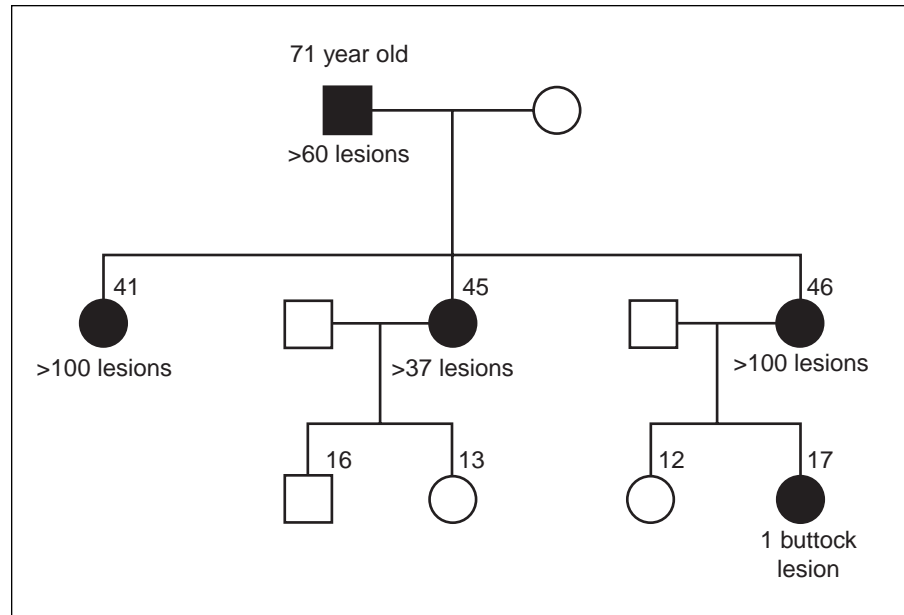


Figure 1. Pedigree chart of affected family. Black circles and black square represent female and male patients, respectively, with dermatofibroma.

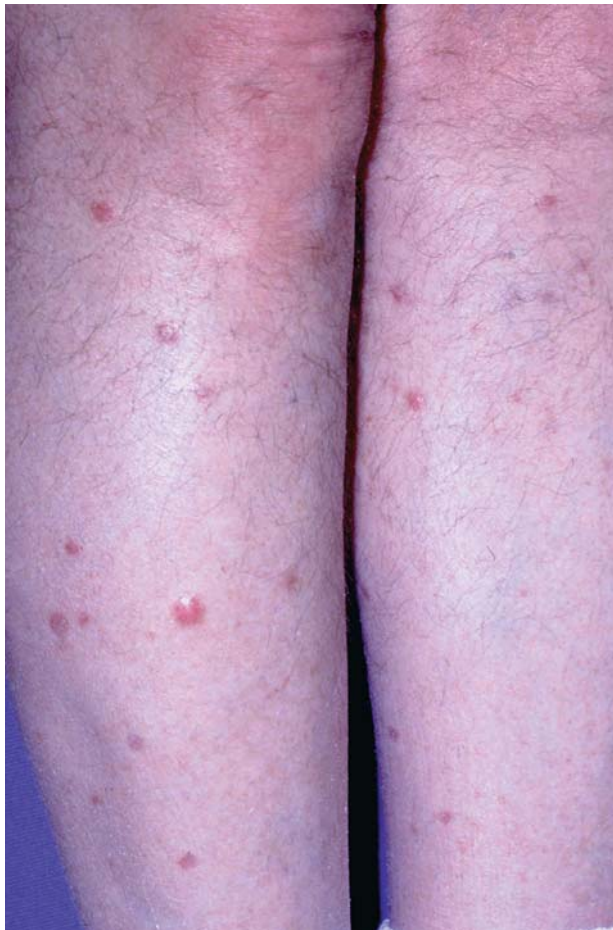

Figure 2. Legs of proband, aged 71 years.

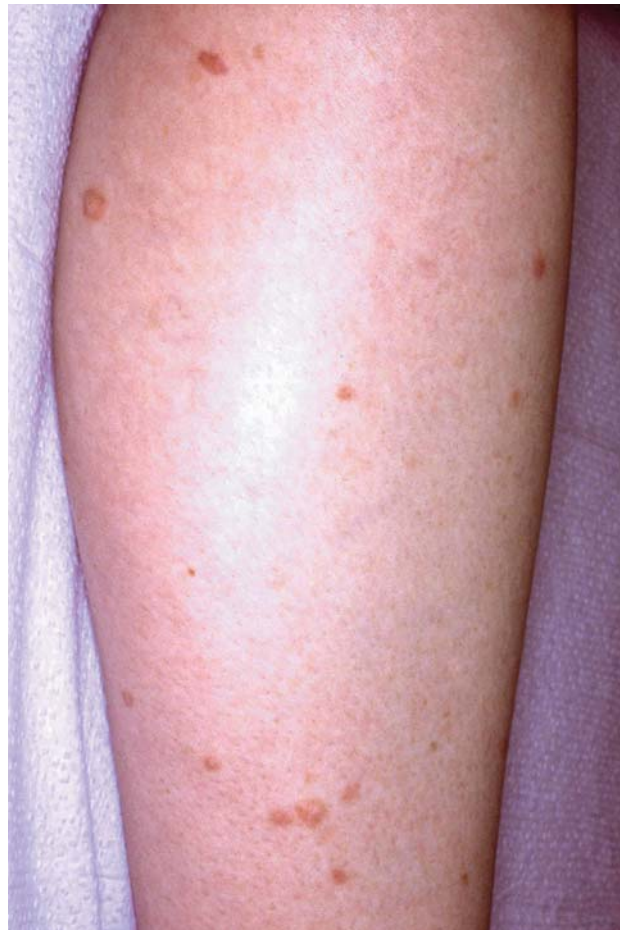

Figure 3. Leg of oldest daughter, aged 46 years.

CONTINUED ON PAGE 190

CONTINUED FROM PAGE 188

The cause of dermatofibromas remains unknown. It has long been suspected to be the result of a reactive process caused by trauma or insect bites.³ An alternative hypothesis is that of an altered or abortive immunologic process. Dermatofibromas contain large numbers of dendritic cells that express major histocompatibility complex class II molecules and are potent antigen-presenting cells. It is possible that these dermal antigen-presenting cells may trigger an abortive immune response to an unidentified antigen.⁴

Chen et al⁷ suggest that benign fibrous histiocytoma is a clonal disease. They compared dermatofibroma tissue with adjacent nonlesional skin serving as controls to analyze the methylation pattern of the polymorphic X-linked androgen receptor gene in 8 cases. In all cases, the authors were able to show a significant reduction in one of the allelic bands compared with controls, suggesting that dermatofibroma is a clonal disease favoring a neoplastic process.

REFERENCES

1. Roberts JT, Byrne EH, Rosenthal D. Familial variant of dermatofibroma with malignancy in the proband. *Arch Dermatol.* 1981;117:12-15.
2. Colome-Grimmer MI, Evans HL. Metastasizing cellular dermatofibroma. a report of two cases. *Am J Surg Pathol.* 1996;20:1361-1367.
3. Gualandri L, Betti R, Cerri A, et al. Eruptive dermatofibromas and immunosuppression. *Eur J Dermatol.* 1999;9:45-47.
4. Ammirati CT, Mann C, Hornstra IK. Multiple eruptive dermatofibromas in three men with HIV infection. *Dermatology.* 1997;195:344-348.
5. Lu I, Cohen PR, Grossman ME. Multiple dermatofibromas in a woman with HIV infection and systemic lupus erythematosus. *J Am Acad Dermatol* 1995;32:901-903.
6. Stainforth J, Goodfield MJD. Multiple dermatofibromata developing during pregnancy. *Eur J Dermatol.* 1999;9:59-60.
7. Chen TC, Kuo T, Chan HL. Dermatofibroma is a clonal proliferative disease. *J Cutan Pathol.* 2000;27:36-39.