

# Disseminated Coccidioidomycosis Discovered During Routine Skin Cancer Screening

CPT Braden R. Rance, MC, USAR; COL Dirk M. Elston, MC, USA

*A 78-year-old white man presented for routine dermatologic examination. A 4×4-mm erythematous papule was noted on the left upper back. It was asymptomatic and previously unnoticed by the patient. The results of a shave biopsy revealed a large spherule with granular cytoplasm diagnostic of coccidioidomycosis. Chest x-ray revealed a 1.8-cm right upper lobe mass. The complement fixation antibody titer for cocci was 1:128. The patient was treated for disseminated coccidioidomycosis with oral fluconazole. The epidemiology, diagnosis, and management of coccidioidomycosis are discussed.*

Coccidioidomycosis is caused by the fungus *Coccidioides immitis*, which is found in soil and is endemic to the southwestern United States (California, Arizona, New Mexico, and Texas) and parts of Central and South America.<sup>1</sup> One half to two thirds of infections are asymptomatic or sub-clinical.<sup>2</sup> We describe a case of disseminated coccidioidomycosis discovered incidentally after a biopsy was performed on a lesion found during a routine dermatologic examination.

## Case Report

A 78-year-old white man presented for routine dermatologic examination. A 4×4-mm erythematous papule was noted on the left upper back (Figure 1). The patient had not previously noted this lesion. Because basal cell carcinoma was suspected, a shave

biopsy was performed. Results of hematoxylin and eosin (H&E) staining revealed a large spherule with granular cytoplasm within a giant cell in the context of a granulomatous reaction pattern (Figure 2). The patient reported a 1-year history of dry cough but was otherwise asymptomatic. He denied any history of trauma or injury to the involved area of his back. No lymphadenopathy was noted on physical examination. Chest x-ray revealed a 1.8-cm right upper lobe mass with a suggestion of central lucency. The complement fixation antibody titer for cocci was 1:128. Calcofluor white preparation and cultures of cerebrospinal fluid were negative. The patient also tested negative for human immunodeficiency virus.

A diagnosis of disseminated coccidioidomycosis was made based on (1) finding cutaneous coccidioidomycosis in a location unlikely to occur via direct cutaneous inoculation, (2) a cocci complement fixation antibody titer of 1:128, and (3) radiographic findings consistent with prior pulmonary coccidioidal infection. The patient is presently receiving treatment for disseminated coccidioidomycosis with 400 mg of oral fluconazole daily.

## Comment

Although most coccidioidal infections are caused by inhalation of arthroconidia, cutaneous inoculations can occur in rare instances.<sup>3</sup> Each year, approximately 3% of people living within an endemic area are at risk of coccidioidomycosis infection.<sup>4</sup> The large number of Americans migrating to the Sunbelt states has greatly expanded these endemic populations. Approximately 100,000 new cases of coccidioidomycosis will occur annually.<sup>2</sup> The concurrent rise in the number of immunosuppressed patients and increased susceptibility to serious coccidioidal infections has made coccidioidomycosis a notable public health concern.<sup>5</sup>

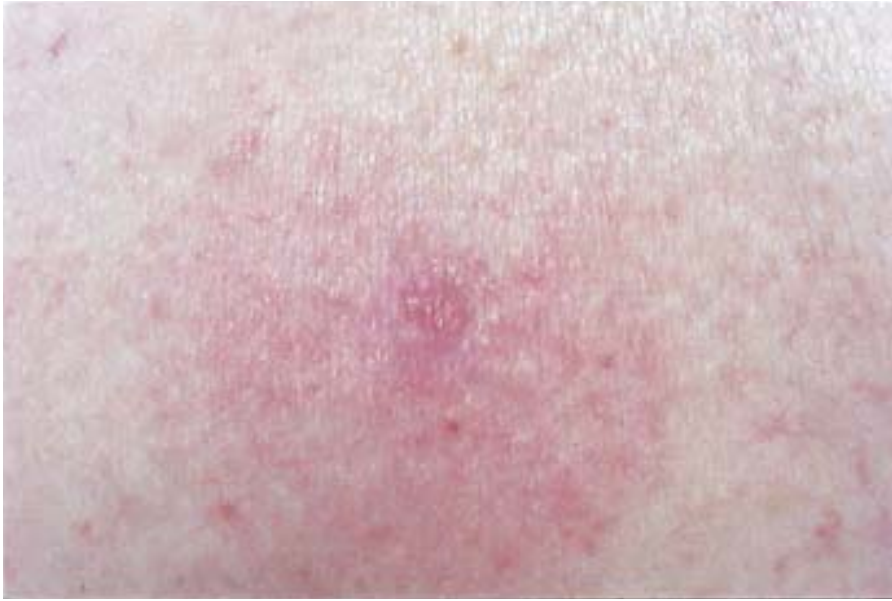Approximately 60% of people infected with *C immitis* are asymptomatic.<sup>6</sup> Other people typically develop symptoms of a lower respiratory infection 1 to 3 weeks after exposure. Symptoms include

---

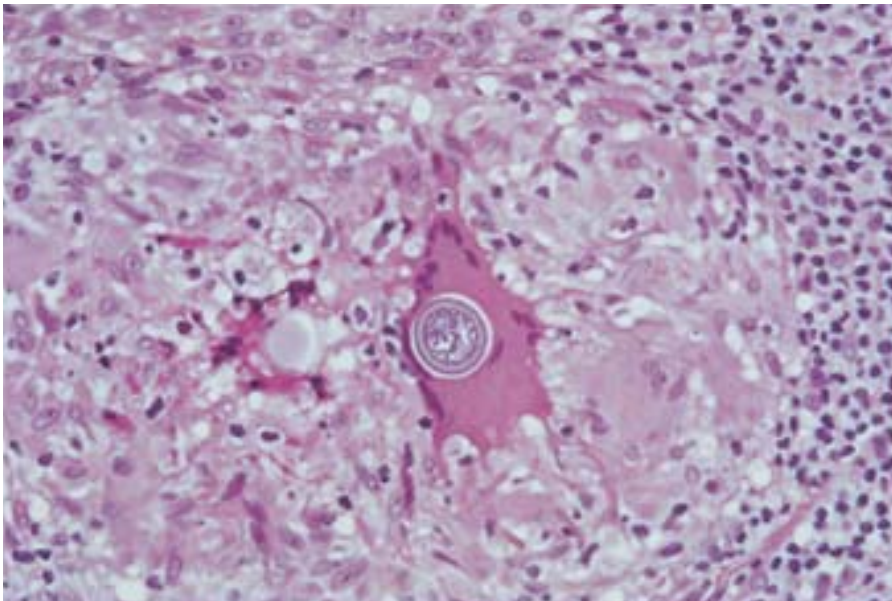
Dr. Rance is from the San Antonio Uniformed Services Health Education Consortium, Texas. Dr. Elston is from the Department of Dermatology, Brooke Army Medical Center and Wilford Hall Air Force Medical Center, San Antonio.

The opinions expressed are those of the authors and should not be construed as official or as representing those of the Army Medical Department, the United States Air Force, or the Department of Defense.

Reprints: CPT Braden R. Rance, MC, USAR, Department of Dermatology, Ehrling Berquist Hospital, Offutt AFB, NE 68113-4013 (e-mail: btrance@msn.com).



**Figure 1.** A 4×4-mm erythematous papule on the left upper back.



**Figure 2.** Large spherule with granular cytoplasm within a giant cell (H&E, original magnification ×200).

fever, sweating, cough, sputum production, chest pain, arthralgias, anorexia, and weakness. Erythema nodosum or erythema multiforme can occur.<sup>7</sup> The triad of fever, erythema nodosum, and arthralgias has been called “desert rheumatism.”<sup>2</sup> Approximately 5% of infected people have asymptomatic residual pulmonary findings, usually thin-walled cavities or nodules.<sup>7</sup>

Disseminated coccidioidomycosis occurs in fewer than 1 in 200 infected individuals. Certain ethnic backgrounds (American black, Filipino, and

Mexican), pregnant women, and immunosuppressed patients are most commonly affected.<sup>1</sup> The skin is the most common site of dissemination, and there is a predilection for lesions at the nasolabial fold.<sup>2</sup> Lesions can present as papules, ulcerating nodules, verrucous plaques, abscesses, or a draining sinus tract.<sup>8</sup> Common sites of extrapulmonary disease include the meninges, bones and joints, and soft tissues.<sup>7</sup> Coccidioidal meningitis is the most severe form of disseminated infection and is nearly always fatal within 2 years of diagnosis if untreated.<sup>2</sup>

The diagnosis of coccidioidomycosis can be established by finding spherules in or isolating *C immitis* from a clinical specimen or by detecting specific anticoccidioidal antibodies in the patient's blood serum, cerebrospinal fluid, or other bodily fluid.<sup>2</sup> The diagnostic role of skin tests is limited because anergy is common in progressive disease.<sup>7</sup>

Treatment regimens for most patients with non-meningeal dissemination include 400 mg of fluconazole daily, 200 mg of itraconazole twice daily, or 400 mg of ketoconazole daily. Treatment typically is continued for at least one year, and then for another 6 months past the point at which further improvement ceases. Relapses occur in approximately a third of patients once therapy is stopped; thus, some patients may require indefinite suppressive therapy.<sup>2</sup>

The subtle clinical presentation in our patient underscores the importance of performing a biopsy on clinically nondiagnostic lesions. A biopsy performed on a small erythematous papule established the diagnosis of a disseminated life-threatening infection.

*Acknowledgments*—We wish to thank Drs. David Dooley and Sue Baum from the Department of Infectious Diseases for their assistance in preparing this manuscript.

## REFERENCES

1. Hay RJ. Deep fungal infections. In: Freedberg IM, Eisen AZ, Wolff K, et al, eds. *Fitzpatrick's Dermatology in General Medicine*. 5th ed. New York, NY: McGraw-Hill; 1999:2372-2388.
2. Galgiani J. *Coccidioides immitis*. In: Mandell GL, Bennett JE, Dolin R, eds. *Mandell, Douglas, and Bennett's Principles and Practice of Infectious Diseases*. 5th ed. Philadelphia, Pa: Churchill Livingstone; 2000:2746-2757.
3. Winn WA. Primary cutaneous coccidioidomycosis: reevaluation of its potentiality based on study of three new cases. *Arch Dermatol*. 1965;92:221-228.
4. Dodge RR, Lebowitz MD, Barbee RA, et al. Estimates of *C immitis* infection by skin test reactivity in an endemic community. *Am J Public Health*. 1985;75:863-865.
5. Galgiani JN. Coccidioidomycosis: a regional disease of national importance. *Ann Intern Med*. 1999;130:293-300.
6. Smith CE, Beard RR, Whiting EG, et al. Varieties of coccidioidal infection in relation to the epidemiology and control of the diseases. *Am J Public Health*. 1946;36:1394-1402.
7. Stevens DA. Coccidioidomycosis. *N Engl J Med*. 1995;332:1077-1082.
8. Fitzpatrick TB, Johnson RA, Wolff KW, et al. Disseminated coccidioidomycosis. In: Fitzpatrick TB, Johnson RA, Wolff KW, et al, eds. *Color Atlas and Synopsis of Clinical Dermatology*. 3rd ed. New York, NY: McGraw-Hill; 1997:755-757.