

# A Case of Bullous Pemphigoid Limited to Psoriatic Plaques

CAPT Todd T. Kobayashi, MD; COL Dirk M. Elston, MD;  
COL Lester F. Libow, MD; COL Kathleen David-Bajar, MD

## GOAL

To identify possible links between bullous pemphigoid (BP) and psoriasis

## OBJECTIVES

Upon completion of this activity, dermatologists and general practitioners should be able to:

1. Describe possible causes of BP in patients with psoriasis.
2. Understand the immune reaction involved in BP and psoriasis.
3. Examine treatment options for BP and psoriasis.

CME Test on page 276.

This article has been peer reviewed and approved by Michael Fisher, MD, Professor of Medicine, Albert Einstein College of Medicine. Review date: October 2002.

This activity has been planned and implemented in accordance with the Essential Areas and Policies of the Accreditation Council for Continuing Medical Education through the joint sponsorship of Albert Einstein College of Medicine and Quadrant HealthCom, Inc. The Albert Einstein College of

Medicine is accredited by the ACCME to provide continuing medical education for physicians.

Albert Einstein College of Medicine designates this educational activity for a maximum of 1.0 hour in category 1 credit toward the AMA Physician's Recognition Award. Each physician should claim only those hours of credit that he/she actually spent in the educational activity.

This activity has been planned and produced in accordance with ACCME Essentials.

Drs. Kobayashi, Elston, Libow, and David-Bajar report no conflict of interest. The authors report no discussion of off-label use. Dr. Fisher reports no conflict of interest.

*Psoriasis occurs with increased incidence in patients with bullous pemphigoid (BP). In this*

Dr. Kobayashi is a resident, and Dr. David-Bajar is staff dermatologist, Department of Dermatology, San Antonio Uniformed Services Health Education Consortium, Texas. Dr. Elston is chief, Department of Dermatology, and Dr. Libow is staff dermatologist and chief of Dermatopathology, Brooke Army Medical Center, San Antonio. The views reflected in this article are those of the authors and should not be construed to reflect those of the US Air Force, the US Army, or the Department of Defense. Reprints: COL Kathleen David-Bajar, MD, Department of Dermatology (MCHE-DD), Brooke Army Medical Center, 3851 Roger Brooke Dr, Fort Sam Houston, TX 78234-6200 (e-mail: kathy.bajar@cen.amedd.army.mil).

*article, we describe the seventh reported English literature case in which the bullous lesions were limited to psoriatic plaques, and we discuss the pathophysiologic mechanisms that might explain this phenomenon. Treatment with acitretin quickly cleared both psoriatic and bullous lesions, suggesting a direct link between the psoriatic inflammatory process and the evolution of bullous lesions.*

**B**ullous pemphigoid (BP) limited to psoriatic plaques was first reported by Person and Rogers<sup>1</sup> in 1976. Subsequent cases were reported by Abel and Bennett<sup>2</sup> in 1979, Grunwald et al<sup>3</sup> in

1985 (2 cases), Smith et al<sup>4</sup> in 1991, and Kirtschig et al<sup>5</sup> in 1996. In all 6 cases, blisters cleared when psoriatic lesions resolved, suggesting a pathogenic link. In this article, we report a seventh English literature case of BP limited to psoriatic plaques and consider pathogenic mechanisms that could account for this association.

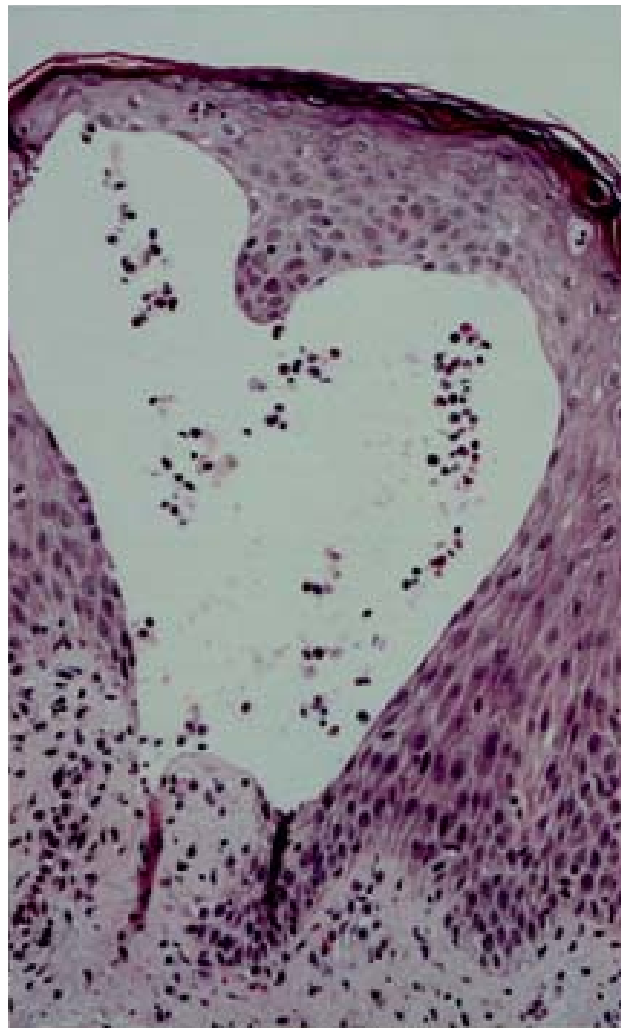
### Case Report

A 47-year-old Hispanic man with a 2-year history of chronic plaque psoriasis presented with a 2-week flare thought to be secondary to a recent upper respiratory tract infection. Treatment consisted of calcipotriene ointment only. Prior treatment included topical steroids and UVB light, which the patient discontinued one year earlier. The patient reported drinking approximately 12 oz of beer each day. Numerous well-demarcated erythematous plaques were noted over the trunk, buttock, scalp, and extremities; some of these plaques had a thick scale, and many were confluent. Vesicles and bullae were limited to the junction of psoriatic plaques and normal skin on the right chest and bilaterally on the peripheral axillae. A few erosions also were noted within the plaques themselves.

Results of complete blood cell count, routine chemistry panel, urinalysis, thyroid stimulating hormone test, and lipid panel were normal. Results of liver function tests were mildly elevated: alkaline phosphatase, 172 U/L (reference range, 35–106 U/L); alanine aminotransferase, 88 U/L (reference range, 3–55 U/L); and  $\gamma$ -glutamyl transpeptidase, 269 U/L (reference range, 5–109 U/L). Results of total protein, albumin, aspartate aminotransferase, total bilirubin, conjugated bilirubin, and indirect reacting bilirubin tests were normal. Results of hepatitis B and C panels were negative. A hepatitis A IgG antibody test was positive, consistent with past history of hepatitis A. Throat culture was negative, but serum antistreptococcal O titer was 333 Todd units (reference range, <100 Todd units), consistent with recent streptococcal infection. Results of bacterial and viral cultures of the vesicles were negative.

A punch biopsy specimen from a vesicular lesion showed a subepidermal vesicle with eosinophils (Figure 1). Results of direct immunofluorescence of perilesional skin showed trace linear IgG and 3+ linear continuous C3 at the dermal-epidermal junction (Figure 2). IgM, IgA, and fibrin were negative. Indirect immunofluorescence with the patient's serum on salt-split skin was negative.

The patient was treated for 2 weeks with levofloxacin, phenylpropanolamine, and guaifenesin for symptoms of a sinus infection. Topical clobetasol

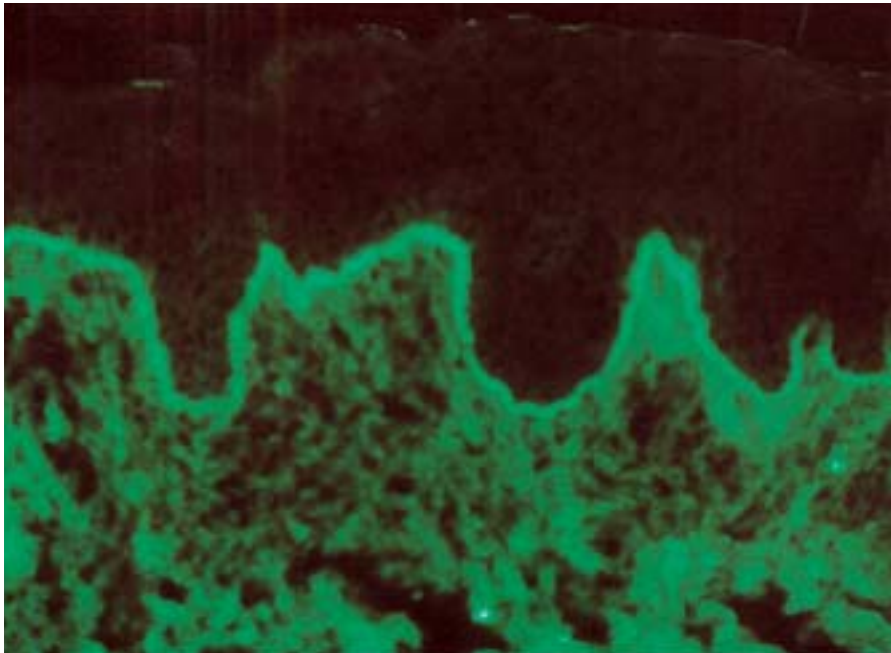


**Figure 1.** A punch biopsy specimen from a vesicular lesion shows a subepidermal vesicle with eosinophils.

and calcipotriene had little effect on either the psoriatic plaques or the vesicles and bullae. Acitretin was started at 25 mg/d. Within 2 weeks, all vesicular and bullous lesions resolved completely; after one month, the psoriasis was significantly improved. Then the acitretin dosage was increased to 50 mg/d. The psoriatic plaques cleared, and the vesicular lesions did not recur. After one year of treatment, the patient was still almost completely clear of psoriatic plaques, and vesicular lesions had not recurred. Liver function tests normalized after one month of stopping alcohol intake and beginning acitretin therapy, and lipid levels remained within reference range.

### Comment

Our patient's case of BP seemed to have been restricted to psoriatic plaques. Epidermolysis bullosa



**Figure 2.** Perilesional skin shows trace linear IgG and 3+ linear continuous C3 at the dermal-epidermal junction (direct immunofluorescence, original magnification  $\times 200$ ).

acquisita (EBA) remained a diagnostic consideration because of a negative indirect immunofluorescent study. However, the rapid response to therapy supported a diagnosis of BP rather than EBA.

Psoriasis and BP cooccur with an incidence greater than would be expected by chance alone.<sup>6</sup> The limitation of bullous lesions to psoriatic plaques further supports the association of these diseases. Other immunobullous diseases reported less commonly with psoriasis include pemphigus vulgaris,<sup>3</sup> pemphigus foliaceus,<sup>7,8</sup> EBA,<sup>9-11</sup> pemphigus erythematosus,<sup>12</sup> and systemic lupus erythematosus.<sup>13</sup>

Numerous reports of other inflammatory skin diseases associated with immunobullous disorders support the theory that immunobullous disorders may be induced by tissue injury in genetically predisposed individuals—perhaps by unmasking or exposing antigenic sites in the basement membrane zone (BMZ). “Epitope spreading” is thought to occur through similar mechanisms with the development of new antibodies to recently unveiled antigenic sites.<sup>14-16</sup> Once “sensitized,” the antibodies become pathogenic.<sup>17</sup> Lichen planus pemphigoides likely represents a similar pathogenic process.

No BP lesions occurred independent of psoriatic lesions in our patient, indicating either that the antibody alone was not pathogenic or that the titer was too low to produce lesions on normal skin. Also, bullous lesions occurred in typical BP distribution (peripheral axillae). As BP antigen expression is highest in the flexures, it may affect lesion

distribution.<sup>18</sup> Perhaps the presence of activated lymphocytes in these areas of high antigen concentration provided adequate stimulation for the development of autoimmunity. Another possibility is that psoriatic skin expresses higher BP antigen levels than normal skin does, which would explain cases of bullous disease limited to psoriatic plaques.

Alterations in the BMZ of psoriatic skin cause basal keratinocyte herniation through electron-lucent areas in the lamina densa<sup>19</sup> and through areas where basal keratinocytes are detached from the BMZ or are resting directly on the papillary dermis without the interposition of the lamina densa.<sup>20</sup> These alterations may provide easier antigen access to low-titer antibodies or may initiate autoimmunity. In many reported cases of BP associated with psoriasis, UV light or aggressive topical therapy was thought to be the inducing agent. UV light can induce BP,<sup>2,21-26</sup> perhaps by inducing antigenic changes in basal keratinocytes.<sup>23</sup> In our patient, there was no correlation with UV light exposure, and topical therapy was limited to calcipotriene. According to a 1990 study, human neutrophil elastase may be involved in the destruction of the dermal-epidermal junction in psoriatic plaques.<sup>27</sup> Incubation of normal skin with human neutrophil elastase destroys hemidesmosomes and separates epidermis from dermis above the level of the BP antigen.<sup>27</sup> Other enzymes that may have a role are neutral proteinases, elastase, cathepsin, serine proteinases, and plasminogen activator.<sup>27</sup> C3

produced by keratinocytes is thought to be the predominant complement factor in the BMZ in autoimmune and inflammatory skin disorders (likely contributing to the inflammatory milieu in the BMZ).<sup>28</sup>

In 1990, Baird et al<sup>29</sup> reported increased levels of plasminogen activator in skin with psoriasis and BP but not in normal skin. We postulate that BP was limited to psoriatic plaques because antigens at these sites were unmasked through enzymatic degradation of the BMZ, allowing easier access to circulating low-titer antibodies. Our patient's bullous lesions resolved quickly after his psoriasis had been controlled with acitretin—thus supporting a direct pathogenic link.

Treatment of patients with cooccurring psoriasis and BP presents special problems. Systemic steroids, in general, should be avoided when treating psoriasis, and UV light should be avoided when treating BP. Methotrexate,<sup>5,21,24,30</sup> dapsone,<sup>31</sup> cyclosporine,<sup>32-34</sup> cyclophosphamide,<sup>25</sup> mycophenolate mofetil,<sup>35</sup> topical steroids,<sup>2,3,10</sup> etretinate,<sup>9</sup> and azathioprine<sup>26,36,37</sup> have all been used to successfully treat the coexisting diseases. Of the 6 reported cases of BP limited to psoriatic plaques, one case resolved without treatment,<sup>1</sup> 3 resolved with topical steroids,<sup>2,3</sup> one resolved with oral prednisone (low maintenance dose),<sup>4</sup> and one resolved with methotrexate.<sup>5</sup> In all 6 cases, psoriasis tended to be more problematic than BP, obviating the need for aggressive or long-term systemic therapy directed at the immunobullous disease. Our patient's BP lesions completely resolved within 4 weeks of starting acitretin.

In summary, we have reported the seventh English literature case of BP associated with psoriasis in which the immunobullous disease was restricted to psoriatic plaques. Unmasking of antigenic determinants in the BMZ by the psoriatic inflammatory process is postulated. This unmasking leads to de novo antibody synthesis in genetically predisposed individuals or to clinical disease in individuals with subclinical antibody titers.

## REFERENCES

1. Person JR, Rogers RS III. Bullous pemphigoid and psoriasis: does subclinical bullous pemphigoid exist? *Br J Dermatol.* 1976;95:535-540.
2. Abel EA, Bennett A. Bullous pemphigoid: occurrence in psoriasis treated with psoralens plus long-wave ultraviolet radiation. *Arch Dermatol.* 1979;115:988-989.
3. Grunwald MH, David M, Feuerman EJ. Coexistence of psoriasis vulgaris and bullous diseases. *J Am Acad Dermatol.* 1985;13:224-228.
4. Smith WDF, Jones MSL, Stewart TW, et al. Bullous pemphigoid occurring in psoriatic plaques in association with Hashimoto's thyroiditis. *Clin Exp Dermatol.* 1991;16:389-391.
5. Kirtschig G, Chow ETY, Venning VA, et al. Acquired subepidermal bullous diseases associated with psoriasis: a clinical, immunopathological and immunogenetic study. *Br J Dermatol.* 1996;135:738-745.
6. Grattan CE. Evidence of an association between bullous pemphigoid and psoriasis. *Br J Dermatol.* 1985;113:281-283.
7. Tomasini D, Cerri A, Cozzani E, et al. Development of pemphigus foliaceus in a patient with psoriasis: a simple coincidence? *Eur J Dermatol.* 1998;8:56-59.
8. Perez GL, Agger WA, Abellera RM, et al. Pemphigus foliaceus coexisting with IgA nephropathy in a patient with psoriasis vulgaris. *Int J Dermatol.* 1995;34:794-796.
9. Endo Y, Tamura A, Ishikawa O, et al. Psoriasis vulgaris coexistent with epidermolysis bullosa acquisita. *Br J Dermatol.* 1997;137:783-786.
10. Saeki H, Hayashi N, Komine M, et al. A case of generalized pustular psoriasis followed by bullous disease: an atypical case of bullous pemphigoid or a novel bullous disease? *Br J Dermatol.* 1996;134:152-155.
11. Smith AG. Epidermolysis bullosa with psoriasis. *Lancet.* 1934;1:1393.
12. Jaimovich L, de Kaminsky AR, Intebi D, et al. Coexistence of psoriasis and pemphigus erythematosus. *Dermatol Int.* 1965;4:143-146.
13. Millns JL, Muller SA. The coexistence of psoriasis and lupus erythematosus: an analysis of 27 cases. *Arch Dermatol.* 1980;116:658-663.
14. Vanderlugt CJ, Miller SD. Epitope spreading. *Curr Opin Immunol.* 1996;8:831-836.
15. Chan LS, Vanderlugt CJ, Hashimoto T, et al. Epitope spreading: lessons from autoimmune skin disease. *J Invest Dermatol.* 1998;110:103-109.
16. Chan LS. Epitope spreading in paraneoplastic pemphigus: autoimmune induction in antibody-mediated blistering skin diseases. *Arch Dermatol.* 2000;136:663-664.
17. Liu Z, Diaz LA, Troy JL, et al. A passive transfer model of the organ specific autoimmune disease, bullous pemphigoid, using antibodies generated against the hemidesmosomal antigen, BP180. *J Clin Invest.* 1993;92:2480-2488.
18. Goldberg DJ, Sabolinski M, Bystryjn JC. Bullous pemphigoid antibodies: human skin as a substrate for indirect immunofluorescence assay. *Arch Dermatol.* 1985;121:1137-1140.
19. Heng MC, Kloss SG, Kuehn CS, et al. Significance and pathogenesis of basal keratinocyte herniations in psoriasis. *J Invest Dermatol.* 1986;87:362-366.
20. Vaccaro M, Pergolizzi S, Mondello MR, et al. The dermoepidermal junction in psoriatic skin as revealed by scanning electron microscopy. *Arch Dermatol Res.* 1999;291:396-399.

21. Perl S, Rappersberger K, Fodinger D, et al. Bullous pemphigoid induced by PUVA therapy. *Dermatology*. 1996;193:245-247.
22. George PM. Bullous pemphigoid possibly induced by psoralen plus ultraviolet A therapy. *Photodermatol Photoimmunol Photomed*. 1996;11:185-187.
23. Muramatsu T, Yamashina Y, Shirai T, et al. UVB irradiation reduces the expression of pemphigoid antigens in organ-cultured normal human skin. *Arch Dermatol Res*. 1994;286:142-144.
24. Albergo RP, Gilgor RS. Delayed onset of bullous pemphigoid after PUVA and sunlight treatment of psoriasis. *Cutis*. 1982;30:621-624.
25. Robinson JK, Baughman RD, Provost TT. Bullous pemphigoid induced by PUVA therapy: is this the aetiology of the acral bullae produced during PUVA treatment? *Br J Dermatol*. 1978;99:709-713.
26. Thomsen K, Schmidt H. PUVA-induced bullous pemphigoid. *Br J Dermatol*. 1976;95:568-569.
27. Glinski W, Jarzabek-Chorzelska M, Kuligowski M, et al. Basement membrane zone as a target for human neutrophil elastase in psoriasis. *Arch Dermatol Res*. 1990;282:506-511.
28. Basset-Seguín N, Porneuf M, Dereure O, et al. C3d,g deposits in inflammatory skin diseases: use of psoriatic skin as a model of cutaneous inflammation. *J Invest Dermatol*. 1993;101:827-831.
29. Baird J, Lazarus GS, Belin D, et al. mRNA for tissue-type plasminogen activator is present in lesional epidermis from patients with psoriasis, pemphigus, or bullous pemphigoid, but is not detected in normal epidermis. *J Invest Dermatol*. 1990;95:548-552.
30. Koerber WA Jr, Price NM, Watson W. Coexistent psoriasis and bullous pemphigoid: a report of six cases. *Arch Dermatol*. 1978;114:1643-1646.
31. Hisler BM, Aronson PJ, Rudner EJ. Bullous pemphigoid in psoriatic lesions. *J Am Acad Dermatol*. 1989;20:683-684.
32. Boixeda JP, Medina S, Ledo A. Bullous pemphigoid and psoriasis: treatment with cyclosporine. *J Am Acad Dermatol*. 1991;24:152.
33. Bianchi L, Gatti S, Nini G. Bullous pemphigoid and severe erythrodermic psoriasis: combined low-dose treatment with cyclosporine and systemic steroids. *J Am Acad Dermatol*. 1992;27:278.
34. Chen KR, Shimizu S, Miyakawa S, et al. Coexistence of psoriasis and an unusual IgG-mediated subepidermal bullous dermatosis: identification of a novel 200-kDa lower lamina lucida target antigen. *Br J Dermatol*. 1996;134:340-346.
35. Nousari HC, Sragovich A, Kimyai-Asadi A, et al. Mycophenolate mofetil in autoimmune and inflammatory skin disorders. *J Am Acad Dermatol*. 1999;40:265-268.
36. Ahmed AR, Winkler NW. Psoriasis and bullous pemphigoid [letter]. *Arch Dermatol*. 1977;113:845.
37. Primka EJ III, Camisa C. Psoriasis and bullous pemphigoid treated with azathioprine. *J Am Acad Dermatol*. 1998;39:121-123.

**DISCLAIMER**

The opinions expressed herein are those of the authors and do not necessarily represent the views of the sponsor or its publisher. Please review complete prescribing information of specific drugs or combination of drugs, including indications, contraindications, warnings, and adverse effects before administering pharmacologic therapy to patients.

**FACULTY DISCLOSURE**

The Faculty Disclosure Policy of the Albert Einstein College of Medicine requires that faculty participating in a CME activity disclose to the audience any relationship with a pharmaceutical or equipment company that might pose a potential, apparent, or real conflict of interest with regard to their contribution to the activity. Any discussions of unlabeled or investigational use of any commercial product or device not yet approved by the US Food and Drug Administration must be disclosed.