

Randomized Trial Evaluating a New 0.5% Fluorouracil Formulation Demonstrates Efficacy After 1-, 2-, or 4-Week Treatment in Patients With Actinic Keratosis

Joseph Jorizzo, MD; Daniel Stewart, DO; Alicia Bucko, DO; Steven A. Davis, MD; Paul Espy, MD; Peter Hino, MD; David Rodriguez, MD; Ronald Savin, MD; Dow Stough, MD; Katharine Furst; Margaret Connolly, PhD; Sharon Levy, MD

The efficacy and safety of a new 0.5% fluorouracil topical cream were compared with vehicle control for the treatment of actinic keratosis (AK). Active treatment applied once daily for 1, 2, or 4 weeks was more effective than vehicle control in achieving reduction from baseline in lesion counts and lesion clearance. Active treatment also resulted in significantly better global assessments of overall improvement. Treatment was effective regardless of the number of baseline lesions. Although longer treatment duration correlated with greater

efficacy, treatment for 1, 2, or 4 weeks was effective. This new microsphere-based fluorouracil formulation was generally well tolerated; adverse events were primarily limited to facial irritation that resolved quickly after treatment. This new treatment provides a safe alternative to the topical fluorouracil formulations currently available for the 1-, 2-, or 4-week treatment of AK.

Actinic keratoses (AKs) are precancerous lesions, with as many as 5% evolving into squamous cell carcinoma (SCC).¹ Individuals with significant sun damage may have many lesions that are ill defined or in contiguous widespread masses, making assessment of the disease challenging. In addition, clinical or histologic differentiation between AK and SCC is sometimes impossible, further complicating assessment of this important condition.² Moreover, many patients have a number of subclinical lesions that are not visible on examination. Because of its status on the continuum to SCC, AK should be treated rather than simply observed for transition to invasive SCC.¹

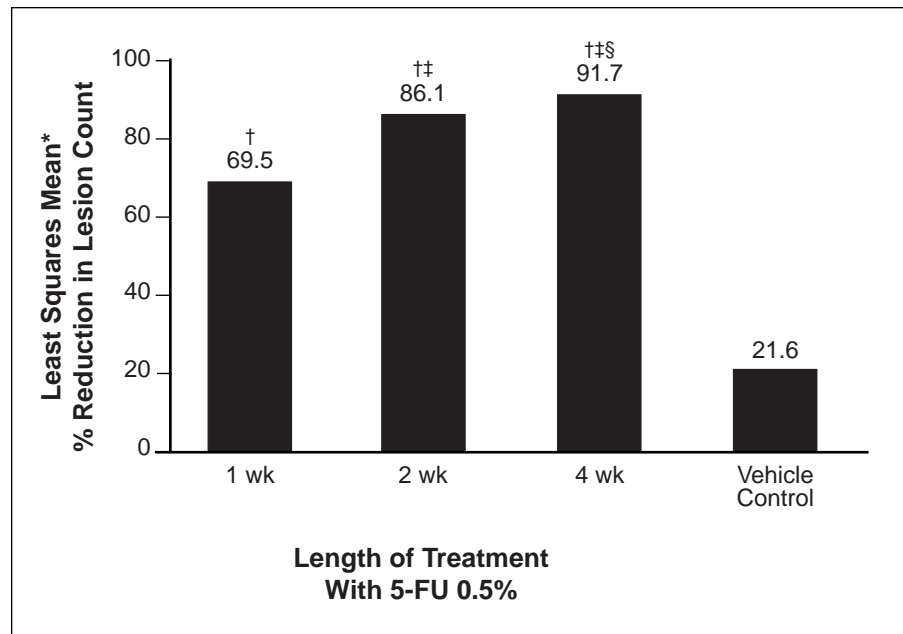
Topical fluorouracil is effective for the treatment of AK.^{1,3-5} In contrast to “spot” treatments, such as cryosurgery and curettage, “blanket” treatment with topical fluorouracil may aid in the destruction of subclinical areas of involvement. A topical preparation of 0.5% fluorouracil cream that incorporates a microsphere (Microsponge®) vehicle has been developed specifically for the treatment of AK (Carac™). Microsphere-based topical formulations

Dr. Jorizzo is from Wake Forest University School of Medicine, Winston-Salem, North Carolina. Dr. Stewart is from Midwest Cutaneous Research, Clinton Township, Missouri. Dr. Bucko is from Academic Dermatology Associates, Albuquerque, New Mexico. Dr. Davis is from Dermatology Clinical Research Center of San Antonio™, Texas. Dr. Espy is from Espy Research Group, Marietta, Georgia. Dr. Hino is from Dermatology Center of Dallas, Texas. Dr. Rodriguez is from International Dermatology Research, Miami, Florida. Dr. Savin is from Savin Dermatology Center, PC, New Haven, Connecticut. Dr. Stough is from The Stough Clinic, Hot Springs, Arkansas. Ms. Furst and Dr. Levy are from Dermik Laboratories, Berwyn, Pennsylvania. Dr. Connolly is from ShellSTAT, Inc, Marion Station, Maryland.

The following authors have relationships with Dermik Laboratories: Dr. Jorizzo, speakers' bureau; Drs. Bucko and Davis, clinical research investigators; Dr. Hino, advisory board member; Ms. Furst and Dr. Levy, employees; and Dr. Connolly, paid consultant. This study was funded by Dermik Laboratories, Berwyn, Pennsylvania.

Reprints: Joseph Jorizzo, MD, Wake Forest University School of Medicine, Department of Dermatology, Clinical Sciences Building, Medical Center Blvd, Winston-Salem, NC 27157-1071 (e-mail: jjorizzo@wfubmc.edu).

Figure 1. Mean percentage reductions in actinic keratosis lesions. Asterisk indicates least squares mean (method of predicting the difference between observed and predicted response for a variable that is a function of ≥ 1 independent variables); dagger, $P < .001$ vs vehicle; double dagger, $P < .001$ vs 0.5% fluorouracil for 1 week; section mark, $P = .016$ vs 0.5% fluorouracil for 2 weeks.



have been designed to trap active ingredients at the skin surface, potentially enhancing drug availability at the application site while limiting drug dispersion.⁶ The efficacy and safety of this novel formulation were evaluated in this randomized, double-blind, vehicle-controlled, parallel-group, multicenter study.

Methods

Eligible patients were 18 years or older with at least 5 AKs (≥ 4 mm in diameter) on the face or frontal scalp. Patients were excluded if they had a confounding skin condition (eg, basal cell carcinoma or SCC), history of facial skin irritation, or treatment for AK within the previous month. The study included a screening visit and baseline clinical evaluation, treatment phase, and posttreatment follow-up phase, with a final evaluation 4 weeks after treatment completion or discontinuation. Patients were randomized to 0.5% fluorouracil cream or vehicle control once daily for 1, 2, or 4 weeks. Institutional review board approval and written informed consent were obtained for each patient before study entry.

Primary efficacy variables included AK lesion reduction from baseline at the posttreatment follow-up evaluation and total clearance of AK lesions at the posttreatment follow-up visit, as determined by Physician Global Assessment of Improvement ratings. This rating scale ranges from -4 (much worse) to $+5$ (total clearance). Absolute reductions from baseline in AK lesion counts

and proportional reductions (expressed as a percentage of baseline) were calculated. The safety assessment, based on adverse events, included details of facial irritation, namely, maximum severity, symptoms, onset and overall duration, post-treatment duration, and summary by visit. Facial irritation was graded as 0 (none), 1 (mild), 2 (moderate), or 3 (severe). To ensure that all facial irritation was recorded, the last observed value for facial irritation was carried forward if a patient discontinued treatment for any reason. Efficacy and safety contrasts among active treatment and placebo groups were performed using pooled data from all vehicle control groups. A P value less than 0.05 was considered statistically significant.

Results

Demographics—Of the 207 randomized patients, 47, 46, and 45 received 1, 2, and 4 weeks of active treatment with 0.5% fluorouracil topical cream, respectively, and 69 patients received vehicle control. The study was completed by 45 patients each in the 1- and 2-week fluorouracil groups (96% and 98%, respectively), by 44 patients (98%) in the 4-week fluorouracil group, and by all 69 patients in the vehicle control group, for an overall completion rate of 98%. The mean number of lesions across all groups ranged from 14.6 to 15.8. Most patients were white (97%) and male (80%), and most (86%) had skin type I or II. One hundred eighteen patients (57%) had received prior therapy for AK, most commonly cryosurgery (45%), and

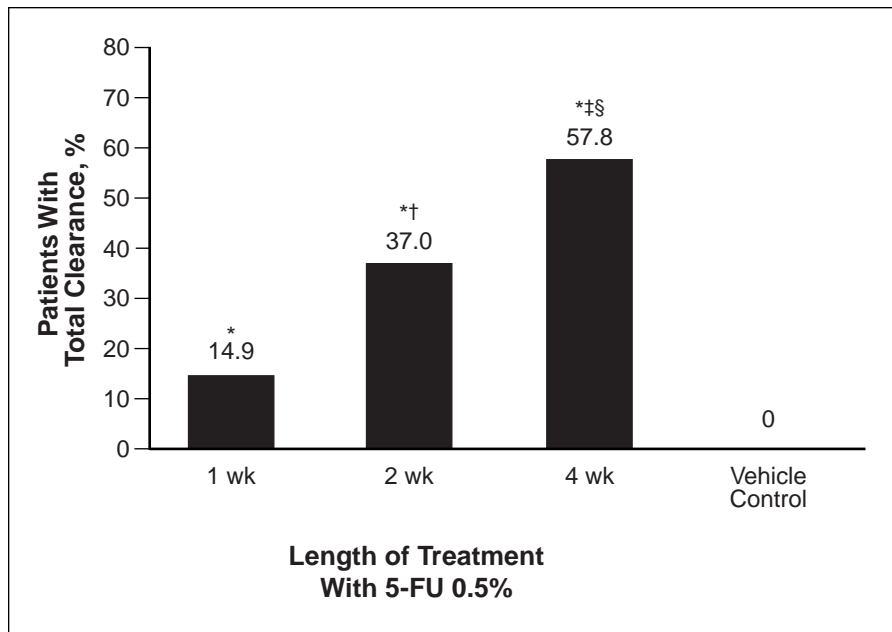


Figure 2. Percentage of patients with total clearance of actinic keratosis lesions. Asterisk indicates $P < .001$ vs vehicle; dagger, $P = .014$ vs 0.5% fluorouracil for 1 week; double dagger, $P < .001$ vs 0.5% fluorouracil for 1 week; section mark, $P = .029$ vs 0.5% fluorouracil for 2 weeks.

9% had been treated with a topical fluorouracil preparation (Efudex®).

Efficacy—At the final evaluation, treatment with 0.5% fluorouracil topical cream was significantly ($P < .001$) more effective than vehicle for all primary efficacy comparisons. Absolute and percentage reductions from baseline in AK lesions were significantly greater ($P < .001$) in the 1-week (69.5%), 2-week (86.1%), and 4-week (91.7%) fluorouracil groups versus the vehicle control group (21.6%) (Figure 1). Patients with few or many baseline lesions had a similar number of lesions at the end of the study, suggesting a relatively greater improvement in patients with many baseline AK lesions. The proportion of patients with total lesion clearance also was significantly greater ($P < .001$) in the active treatment groups (14.9%–57.8%) compared with the vehicle control group (0%) (Figure 2). The Physician Global Assessment of Improvement scores significantly improved ($P < .001$) in the 1-, 2-, and 4-week active treatment groups compared with the vehicle control group.

Safety—The safety of 0.5% fluorouracil topical cream was assessed based on adverse events in all 207 randomized patients. Approximately 50% of patients (range, 45.8%–58.7%) in all treatment groups entered the study with some degree of facial irritation. The most commonly observed signs and symptoms of facial irritation in each group at baseline were dryness (36.2%) and erythema (42%). Other signs and symptoms of facial irritation

included erosion, edema, pain, and burning. Throughout the study, facial irritation was reported by most patients in the 1-week fluorouracil (89%), 2-week fluorouracil (98%), 4-week fluorouracil (96%), and vehicle (65%) study groups. Differences in the incidence of facial irritation among each active treatment and vehicle control groups were significant for all contrasts ($P = .004$ for 1-week active treatment vs vehicle and $P < .001$ for both 2- and 4-week active treatment vs vehicle). The maximum facial irritation severity was mostly mild or moderate for all active treatment groups compared with the vehicle control group ($P < .001$). The severity of facial irritation increased throughout the treatment phase for the 1- and 2-week fluorouracil groups. However, in the 4-week fluorouracil group, facial irritation severity appeared to reach a plateau after the third week of therapy (Figure 3). Although most of these patients were able to tolerate fluorouracil therapy, 5 patients discontinued treatment because of facial irritation.

The time course of facial irritation was predictable. Median onset of irritation was at day 4 in all groups, and the median duration increased with longer treatment duration (overall median durations during the treatment and posttreatment periods were 19 days in the 1-week treatment group; 29 days in the 2-week treatment group; 41 days in the 4-week treatment group; and 10 days in the vehicle control group).

Resolution of facial irritation after treatment completion or discontinuation followed a similar

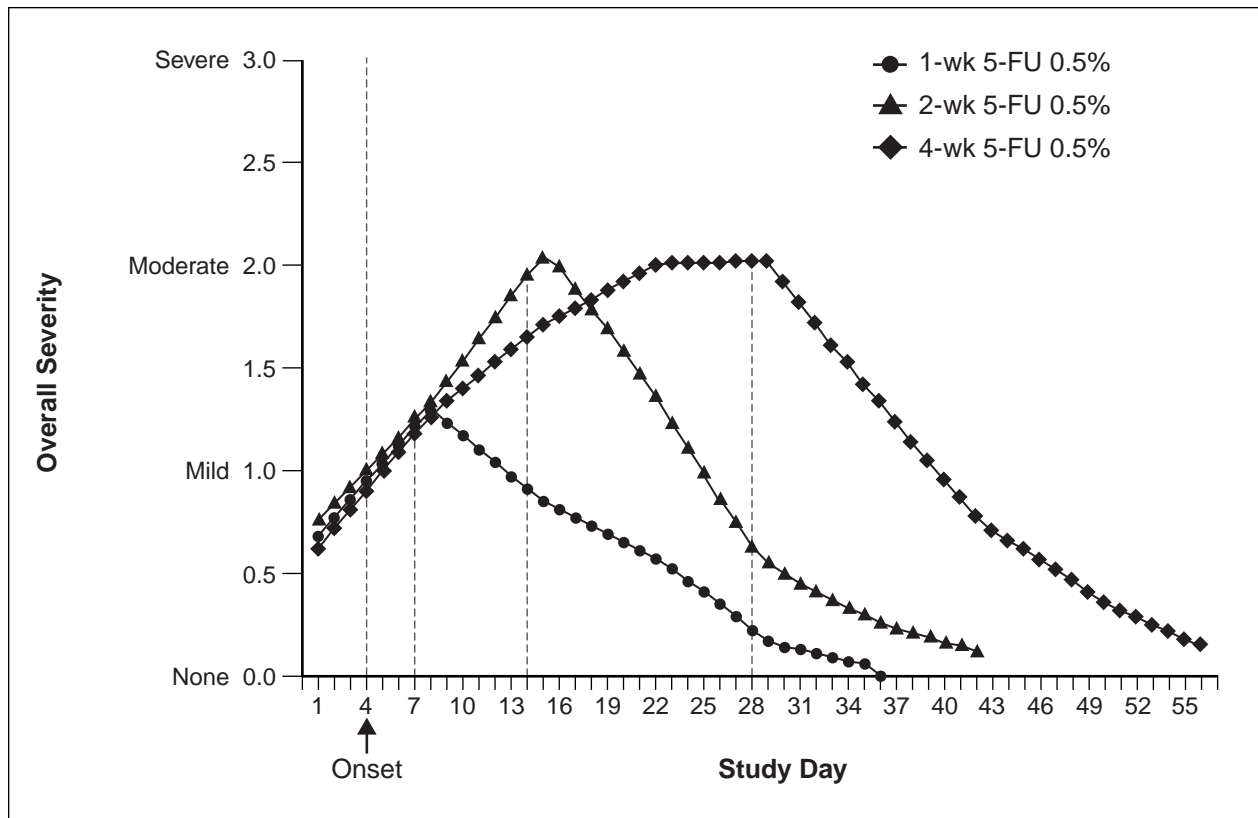


Figure 3. Overall severity and time course of facial irritation during and after treatment periods. Severity based on the following scale: 0 (none), 1 (mild), 2 (moderate), or 3 (severe).

time course in all fluorouracil groups (median durations calculated during posttreatment periods were 18 days, 1-week treatment; 19 days, 2-week treatment; and 21 days, 4-week treatment). By comparison, the median duration was 9 days in the vehicle control group. Facial irritation severity decreased rapidly during the first 2 weeks after the treatment period to near baseline and continued to decline to below baseline level (Figure 3). Little or no irritation was present in any treatment group by post-treatment week 4; only 9% of all active treatment groups and 4% of the vehicle control group had facial irritation at the final evaluation.

A total of 24 patients discontinued study medication because of an adverse event; 12 patients were in the 4-week fluorouracil group. Serious adverse events occurred in only 5 patients, 3 of whom were receiving active treatment; no events were related to treatment.

Comment

A new microsphere-based formulation of 0.5% fluorouracil topical cream applied once daily was significantly more effective than vehicle for the 1-, 2-, or 4-week treatment of AK. Once-daily

treatment with 0.5% fluorouracil cream significantly reduced the number of AK lesions and achieved total lesion clearance in a significantly greater proportion of patients compared with vehicle control. Although no patients in the vehicle group experienced total clearance of AK lesions, these patients experienced a 21.6% mean reduction of AK lesions from baseline. Several reasons may account for this finding, including spontaneous AK remission⁷⁻⁹ or variability of investigator assessment. For example, a large confluent lesion may have been counted as several lesions during one assessment and as one lesion during a subsequent assessment. These results are similar to those of vehicle in other studies.^{10,11}

Although increased efficacy with longer treatment was apparent from comparisons across treatment groups, significant improvements were evident with the shorter treatment (ie, 1-week regimen). Furthermore, treatment was effective in patients with a number of baseline AK lesions; the mean number of lesions at baseline in all patients ranged from 14.6 to 15.8. Patients with widespread AK may have benefited from the treatment of sub-

clinical lesions. After treatment, redness and irritation were found in the areas where the lesions were not visible, suggesting the activity of fluorouracil in occult lesions.

The most frequent adverse event was mild to moderate facial irritation and occurred in most patients in both active treatment and vehicle control groups. However, at the end of the treatment phase, the percentage of patients experiencing some level of irritation was similar to that observed at baseline (55.1%), and decreased to below baseline levels as early as posttreatment week 1 (27.9%). Resolution of facial irritation typically occurred 18 to 21 days after treatment cessation in all groups receiving active treatment. Although greater mean overall irritation occurred in patients in the 2- and 4-week active treatment groups compared with the 1-week group, facial irritation severity reached a plateau after approximately 3 weeks in the 4-week active treatment group, and the severity of facial irritation experienced by patients in the 2- and 4-week treatment groups was similar. Of note, systemic tolerance of 0.5% fluorouracil cream was excellent in this trial, and only 5 patients reported serious adverse events.

A recent study¹² demonstrated that the amount of fluorouracil excreted in the urine of patients treated with this 0.5% formulation was one fortieth that of patients treated with a currently available 5% fluorouracil cream (2.737 μg vs 119.8 μg , respectively), suggesting that systemic absorption of the 0.5% cream was much lower than the expected difference of one tenth. Based on a conservative ratio of systemically available fluorouracil excreted in urine (1:10), these urinary excretion data suggest that the systemic absorptions of 0.5% and 5% fluorouracil cream are 0.55% and 2.4%, respectively.¹² In addition, 86% to 92% of topically applied 0.5% fluorouracil cream is retained in the skin compared with only 55% of a currently available 5% fluorouracil cream, indicating targeted delivery of fluorouracil to the skin.¹³

Conclusion

The efficacy of this new microsphere-based 0.5% fluorouracil cream was clearly demonstrated in this study when compared with vehicle control. Patients can anticipate improvements in lesion counts, clearance, and overall skin condition. Extending

treatment for up to 4 weeks appears to improve efficacy without significantly increasing the intensity of irritation. This new 0.5% fluorouracil topical cream is a safe and effective alternative to traditional topical fluorouracil formulations for the 1-, 2-, or 4-week treatment of AK and offers a treatment regimen tailored to patients' needs.

REFERENCES

1. Skin cancer (PDQ) treatment—health professionals. National Cancer Institute Web site. Available at: <http://www.cancernet.nci.nih.gov>. Accessed September 19, 2000.
2. Cohn BA. From sunlight to actinic keratosis to squamous cell carcinoma. *J Am Acad Dermatol*. 2000;42(suppl 1, pt 1):143-144.
3. Breza T, Taylor R, Eaglstein WH. Noninflammatory destruction of actinic keratoses by fluorouracil. *Arch Dermatol*. 1976;112:1256-1258.
4. Dillaha CJ, Jansen GT, Honeycutt WM, et al. Selective cytotoxic effect of topical 5-fluorouracil. *Arch Dermatol*. 1963;88:247-256.
5. Hodge SJ, Schrodt GR, Owen LG. Effect of topical 5-fluorouracil treatment on actinic keratosis: a light and electron microscopic study. *J Cutan Pathol*. 1974;1:238-248.
6. Microsponge Systems Information. Enhanced Derm Technologies, Inc. Available at: <http://www.pimpleportal.com>. Accessed May 16, 2000.
7. Marks R. Epidemiology of non-melanoma skin cancer and solar keratoses in Australia: a tale of self-immolation in Elysian fields. *Australas J Dermatol*. 1997;38:26-29.
8. Thompson SC, Jolley D, Marks R. Reduction of solar keratoses by regular sunscreen use. *N Engl J Med*. 1993;329:1137-1151.
9. Marks R, Foley P, Goodman G, et al. Spontaneous remission of solar keratoses: the case for conservative management. *Br J Dermatol*. 1986;115:649-655.
10. Wolf JE, Taylor JR, Tschen E, et al. Topical 3.0% diclofenac in 2.5% hyaluronan gel in the treatment of actinic keratoses. *Int J Dermatol*. 2001;40:709-711.
11. Rivers JK, Arlette J, Shear N, et al. Topical treatment of actinic keratoses with 3.0% diclofenac in 2.5% hyaluronan gel. *Br J Dermatol*. 2002;146:94-100.
12. Levy S, Furst K, Chern W. A pharmacokinetic evaluation of 0.5% or 5% fluorouracil topical cream in patients with actinic keratosis. *Clin Ther*. 2001;23:908-920.
13. Levy S, Furst K, Chern W. Comparison of the skin permeation of three topical 0.5% fluorouracil formulations with that of a 5% formulations. *Clin Ther*. 2001;23:901-907.