

What's Eating You?

Strongyloides stercoralis

COL Dirk M. Elston, MC, USA; MAJ Katherine Czarnik, MC, USA;
Lt Col Royce Brockett, USAF, BSC; James H. Keeling, MD

S*trongyloides stercoralis* (Figure 1) is endemic to Southeast Asia, the southern United States (especially Kentucky and Tennessee), central Africa, and warmer areas of South America (especially Brazil).¹ Among immigrants from Southeast Asia, the prevalence of infection may be as high as 38%.² The most characteristic skin lesion associated with *Strongyloides* infection is larva currens (Figures 2 and 3), a rapidly moving urticarial form of cutaneous larva migrans. These linear or serpiginous urticarial streaks are typically noted on the buttocks or lower trunk. Larva currens may migrate up to 10 cm in a matter of hours, unlike the slow progression of cutaneous larva migrans. Although lesions of cutaneous larva migrans persist for days, larva currens is fleeting and may vanish a few hours after onset. Thumbprint purpura also may be noted, especially on the lower trunk and buttocks. In one study of patients with disseminated strongyloidiasis, skin biopsy results of purpuric lesions demonstrated the parasite in 10 of 12 biopsy specimens.³ Recognition of the characteristic skin lesions can be crucial for early diagnosis and treatment.⁴ Nonspecific lesions are common, including urticaria, morbilliform eruptions, and generalized or localized pruritus. *Strongyloides* infection also may present as generalized prurigo nodularis or

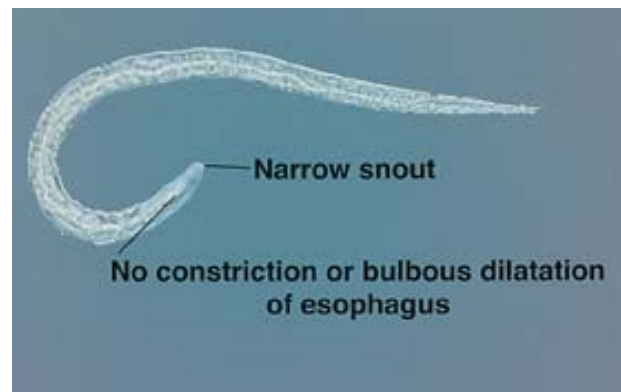


Figure 1. *Strongyloides* larva.

lichen simplex chronicus.⁵ The larval worm in Figure 4 was isolated from the feces of a patient with urticaria and prurigo nodularis. She had recently been treated with a course of prednisone. Complete blood count results revealed peripheral eosinophilia, which prompted examination of stool samples for ova and parasites. Lesions resolved after treatment for *Strongyloides* with albendazole and ivermectin.

Laboratory recognition of *Strongyloides* infection usually depends on enzyme-linked immunosorbent assay testing of serum or the recovery of larvae from stool, duodenal, or sputum samples. Adult worms and eggs are infrequently recovered. If unpreserved stool specimens have been allowed to remain at room temperature for 24 hours or more, hookworm eggs, if present, may hatch to first-stage larvae, which can be confused with *Strongyloides* larvae. *Strongyloides* are differentiated from hookworm larvae by the presence of a short buccal cavity, notched tail, and prominent genital primordium. Hookworm larvae have a long buccal

Accepted for publication October 29, 2001.

From the Departments of Dermatology, Brooke Army Medical Center, San Antonio, Texas, and Geisinger Medical Center, Danville, Pennsylvania.

The views expressed are those of the authors and are not to be construed as official or as representing those of the Army Medical Department or the Department of Defense. This work is in the public domain.

Reprints: Dirk M. Elston, MD, Department of Dermatology, Geisinger Medical Center, 100 N Academy Ave, Danville, PA 17822-1406.

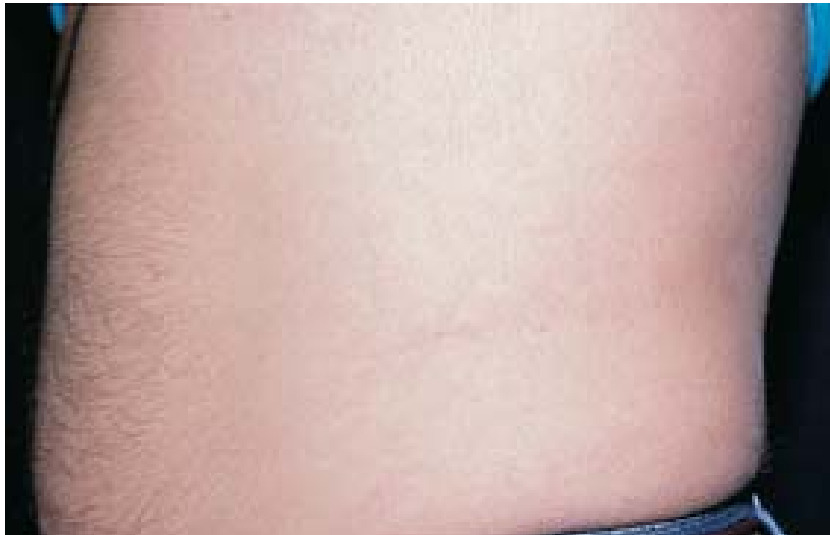

Figure 2. A patient demonstrating the urticarial "burrow" of larva currens.

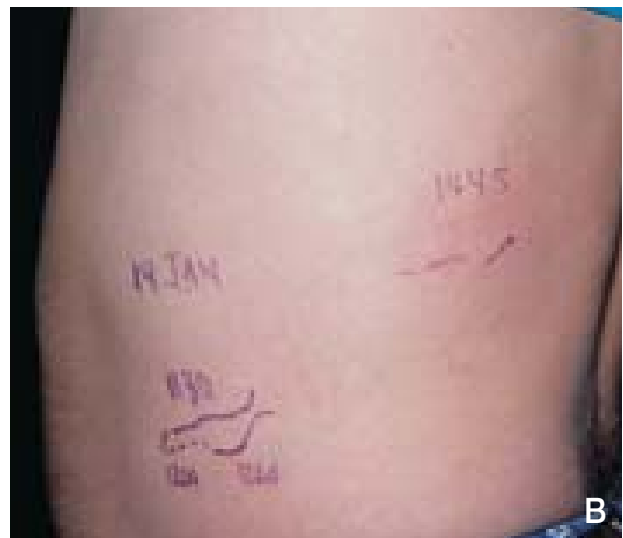

Figure 3. Larva currens position marked at 11:30 AM (blue) and 12:00 PM (red). Ruler indicates distance in centimeters (A). Progression onto the back by 2:45 PM (B).

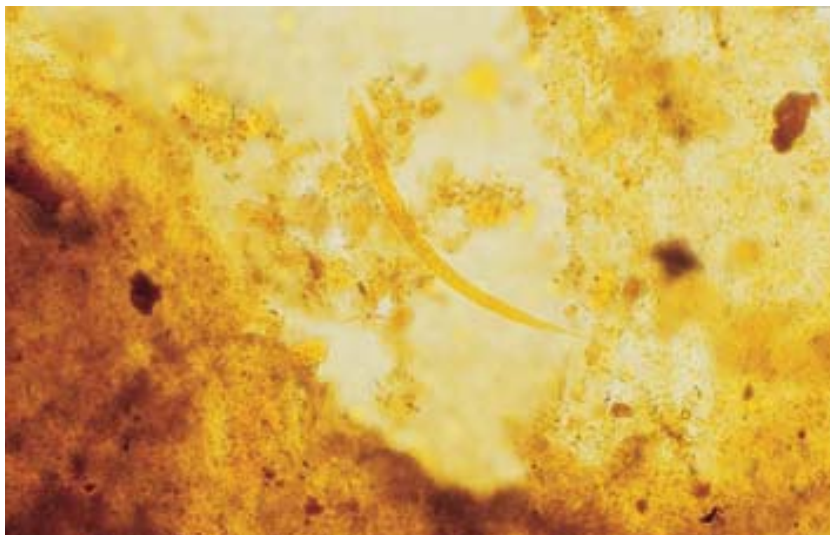


Figure 4. *Strongyloides* in a stool sample from a patient with urticaria, prurigo nodularis, and peripheral eosinophilia.

cavity, pointed tail, and inconspicuous genital primordium. *Strongyloides* larvae are much smaller than pinworms and lack the pinworm's broad snout and bulbous esophageal dilatation. Intermittent larval shedding hampers diagnosis of *Strongyloides* in stool specimens.⁶ The sensitivity of routine laboratory detection of *Strongyloides* can be increased by agar-plate culture. The plates are examined daily for characteristic furrows left by the larvae.⁷

Morbidity related to *Strongyloides* infection is greatest in immunocompromised patients. The life cycle of autoinfection from the bowel results in persistent infection in immunocompromised hosts. Dissemination of strongyloidiasis has been associated with as little as a single large dose of a systemic corticosteroid.⁸ In endemic areas, physicians should screen patients with peripheral eosinophilia for *Strongyloides* infection before initiating corticosteroid therapy. In nonendemic areas it is wise to elicit a travel history before initiating immunosuppressive therapy.

Patients infected with the human T-cell lymphoma/leukemia virus type I have a higher incidence of *Strongyloides* infection.⁹ Death from gastrointestinal bleeding and multiorgan failure has been reported as the initial presentation of disease in the setting of the human T-cell lymphoma/leukemia virus type I and *Strongyloides* infection.¹⁰ Death from massive pulmonary hemorrhage has been reported in strongyloidiasis in the setting of systemic lupus erythematosus.¹¹ Serum immunofluorescence and enzyme-linked immunosorbent assay tests are helpful in screening for *Strongyloides* infection in immunocompromised patients.^{12,13}

Ivermectin and albendazole are useful in the treatment of strongyloidiasis.^{14,15} Resistance to albendazole treatment appears to be associated with HLA-DR9 (DRB1*0901) and elevated *Strongyloides*-specific IgG4 antibody titer.¹⁶ Thiabendazole may be associated with a higher incidence of side effects.¹⁷ *The Medical Letter on Drugs and Therapeutics* is a good source for current recommendations regarding the treatment of parasitic infestations.

REFERENCES

1. Mahmoud AA. Strongyloidiasis. *Clin Infect Dis*. 1996;23:949-953.
2. Nutman TB, Ottesen EA, Ieng S, et al. Eosinophilia in Southeast Asian refugees: evaluation at a referral center. *J Infect Dis*. 1987;155:309-313.
3. Chaudhary K, Smith RJ, Himelright IM, et al. Case report: purpura in disseminated strongyloidiasis. *Am J Med Sci*. 1994;308:186-191.
4. Gordon SM, Gal AA, Solomon AR, et al. Disseminated strongyloidiasis with cutaneous manifestations in an

- immunocompromised host. *J Am Acad Dermatol*. 1994;31:255-259.
5. Jacob CI, Patten SF. *Strongyloides stercoralis* infection presenting as generalized prurigo nodularis and lichen simplex chronicus. *J Am Acad Dermatol*. 1999;41:357-361.
6. Dreyer G, Fernandes-Silva E, Alves S, et al. Patterns of detection of *Strongyloides stercoralis* in stool specimens: implications for diagnosis and clinical trials. *J Clin Microbiol*. 1996;34:2569-2571.
7. Jongwutiwes S, Charoenkorn M, Sitthichareonchai P, et al. Increased sensitivity of routine laboratory detection of *Strongyloides stercoralis* and hookworm by agar-plate culture. *Trans R Soc Trop Med Hyg*. 1999;93:398-400.
8. Thomas MC, Costello SA. Disseminated strongyloidiasis arising from a single dose of dexamethasone before stereotactic radiosurgery. *Int J Clin Pract*. 1998;52:520-521.
9. Chieffi PP, Chiattoni CS, Feltrim EN, et al. Coinfection by *Strongyloides stercoralis* in blood donors infected with human T-cell leukemia/lymphoma virus type 1 in Sao Paulo City, Brazil. *Memorias do Instituto Oswaldo Cruz*. 2000;95:711-712.
10. Sorensen M, Andersen O, Friis-Moller A, et al. Fatal outcome of *Strongyloides stercoralis* infection in a patient with no previously known immunosuppression. *Ugeskrift Laeger*. 2000;162:2894-2895.
11. Setoyama M, Fukumaru S, Takasaki T, et al. SLE with death from acute massive pulmonary hemorrhage caused by disseminated strongyloidiasis. *Scand J Rheumatol*. 1997;26:389-391.
12. de Paula FM, de Castro E, Goncalves-Pires M, et al. Parasitological and immunological diagnoses of *Strongyloides* in immunocompromised and non-immunocompromised children in Uberlandia, State of Minas Gerais, Brazil. *Rvisita do Instituto de Medicina Tropical de Sao Paulo*. 2000;42:51-55.
13. Abdul-Fattah MM, Nasr ME, Yousef SM, et al. Efficacy of ELISA in diagnosis of strongyloidiasis among the immunocompromised patients. *J Egypt Soc Parasitol*. 1995;25:491-498.
14. Marti H, Haji HJ, Savioli L, et al. A comparative trial of a single-dose of ivermectin versus three days of albendazole for treatment of *Strongyloides stercoralis* and other soil-transmitted helminth infections in children. *Am J Trop Med Hyg*. 1996;55:477-481.
15. Detry A, Hilmarsdottir I, Mayorga-Sagastume R, et al. Treatment of *Strongyloides stercoralis* infection with ivermectin compared with albendazole: results of an open study of 60 cases. *Trans R Soc Trop Med Hyg*. 1994;88:344-345.
16. Satoh M, Toma H, Sato Y, et al. Production of a high level of specific IgG4 antibody associated with resistance to albendazole treatment in HLA-DRB1*0901-positive patients with strongyloidiasis. *Am J Trop Med Hyg*. 1999;61:668-671.
17. Gann PH, Neva FA, Gam AA. A randomized trial of single- and two-dose ivermectin versus thiabendazole for the treatment of strongyloidiasis. *J Infect Dis*. 1994;169:1076-1079.