

# A Patient With Extensive Stem Cell Factor–Induced Hyperpigmentation

Jane S. Bellet, MD; Joseph M. Obadiah, MD; Barbara M. Frothingham, MSN, FNP; Joanne Kurtzberg, MD; James M. Grichnik, MD, PhD

*Stem cell factor (SCF) is a cytokine that stimulates development of erythroid precursors and, consequently, may have potential importance in the treatment of certain anemias. We report a case of a young woman with Diamond-Blackfan anemia who received SCF treatment. One effect of SCF treatment is cutaneous hyperpigmentation at the injection site. In contrast to previously reported cases of patients who had fewer SCF injections, her hyperpigmentation was extensive and of major cosmetic concern. SCF may play a role in a number of disease processes. This case demonstrates the need to consider the potential pigmentary side effects of SCF therapy and to make careful selection of the injection sites.*

**S**tem cell factor (SCF)—also known as Kit ligand, mast cell growth factor, or steel factor—a ligand for the tyrosine kinase receptor *c-Kit*, controls components of hematopoiesis, melanogenesis, and gametogenesis. By acting on early progenitor cells and committed cells, SCF affects the survival, proliferation, and differentiation of these lineages.<sup>1</sup> Defects in this pathway result in impaired hematopoiesis, loss of pigment, and infertility.<sup>1-3</sup>

Diamond-Blackfan anemia is a congenital, red cell, hypoplastic anemia that in most cases requires lifelong transfusion therapy. Long-term transfusions lead to iron overload and often to premature death. Deficiencies of certain erythroid growth factors have been postulated to play a role in this anemia's pathogenesis.<sup>4</sup> Hematologic studies have shown stimulatory effects of SCF on pluripotent hematologic stem cells, both in culture<sup>5</sup> and in vivo,<sup>6</sup> making SCF a candidate for therapy of anemic disorders.<sup>7</sup> Specifically, SCF has been found to increase the number of erythroid colonies in human bone marrow culture.<sup>1,8</sup>

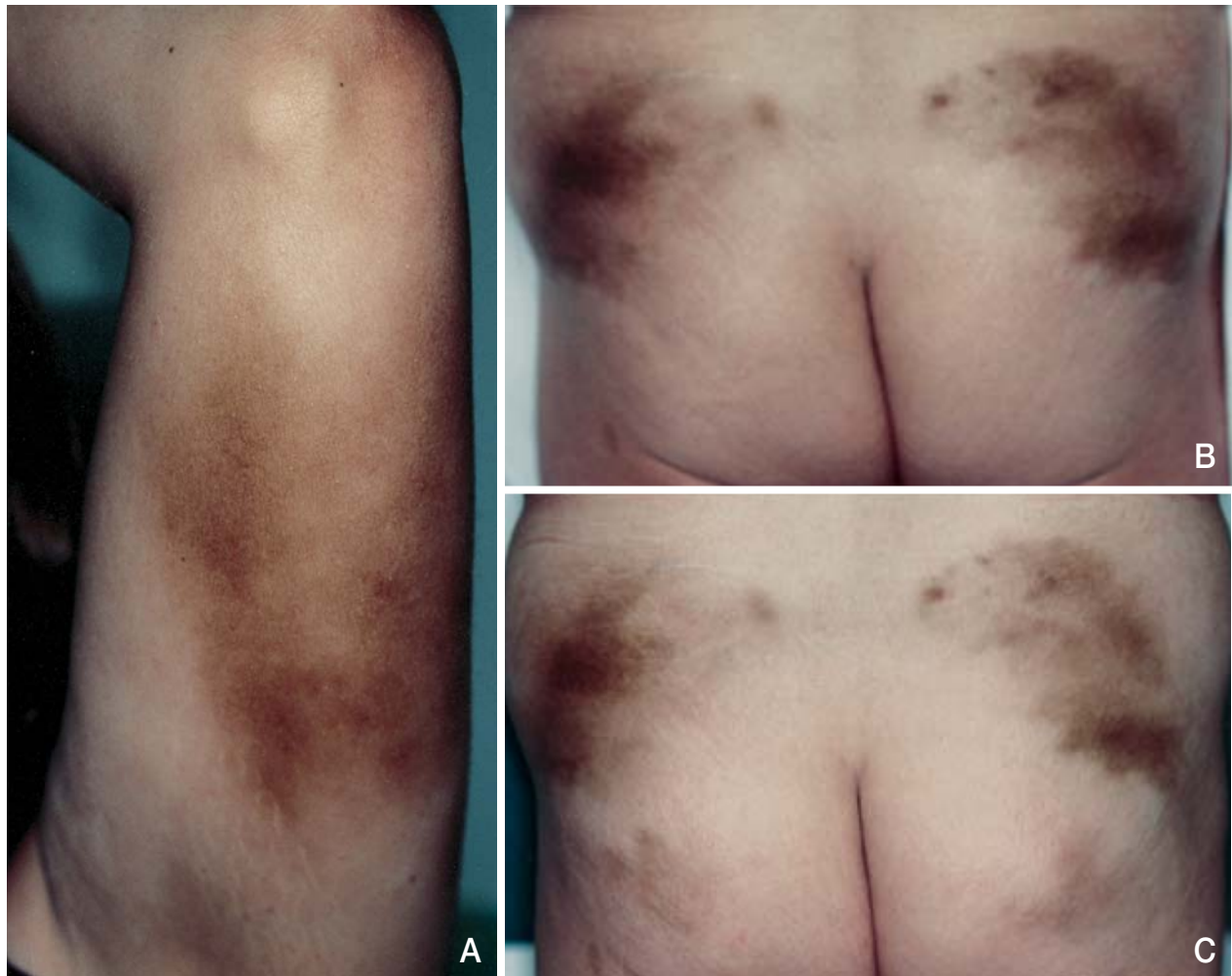
SCF also plays a critical role in the pigmentary system, and melanocytic hyperplasia has previously been reported at SCF injection sites.<sup>9,10</sup> Herein, we report on a patient with Diamond-Blackfan anemia who had been unresponsive to azathioprine treatment, was allergic to deferoxamine mesylate, and underwent SCF treatments. She experienced large areas of hyperpigmentation, which appeared to be more extensive than those previously reported.<sup>9,10</sup>

## Case Report

A 20-year-old white woman with Diamond-Blackfan anemia, diagnosed at 2 months of age, had been dependent on monthly exchange transfusions. Consequently, the problems of iron excess have complicated her course of treatment, and she received erythrocytapheresis and chelation therapy with deferoxamine mesylate until her allergy developed. Recent developments in hemopoietic growth factors led to treatment with SCF, which was used in an effort to increase the patient's blood counts and minimize transfusion requirements. After informed consent and local institutional review board approval, she was started on therapy with SCF on a compassionate use basis. SCF therapy was initiated at 20  $\mu\text{g}/\text{kg}$  (1400  $\mu\text{g}$ ) per day. Some pruritis, erythema, and induration were noted at the injection sites; this was well controlled with systemic antihistamines. After one month of therapy, the dose was slowly increased to 50  $\mu\text{g}/\text{kg}$  (3500  $\mu\text{g}$ ) per day. After several days on this dose, the patient experienced significant urticaria at the injection site and difficulty breathing. The dose was reduced to 35  $\mu\text{g}/\text{kg}$  per day, and she experienced no further anaphylactic-type symptoms. Her major concern was the marked hyperpigmentation at the injection sites. She noted this at the initial injection sites on her posterior forearms within one month of initiating SCF therapy. Hyperpigmentation was still present 7 weeks after arm injections were discontinued following 13 weeks of subcutaneous SCF injection every other day (alternating daily between

Accepted for publication September 20, 2002.

From Duke University Medical Center, Durham, North Carolina.  
Reprints: James M. Grichnik MD, PhD, Box 3135 DUMC, Durham, NC 27710 (e-mail: grich001@mc.duke.edu).



Stem cell factor–induced hyperpigmentation: marked cutaneous hyperpigmentation in the location of injections in the patient’s posterior left-upper arm (A)(right-upper arm was essentially equivalent in appearance) and upper buttocks (B). Left-lower buttock was treated for 4 weeks with topical steroid, but this did not appear to markedly decrease the development of hyperpigmentation (C)(compared with the right-lower buttock without steroid).

arms)(Figure, A). Secondary to cosmetic concerns, the injection location was then changed to the buttocks area. The hyperpigmentation continued after 7 weeks of daily SCF injections alternating between buttocks (Figure, B). In addition to SCF, erythropoietin also was added to the patient’s treatment, starting just one week prior to our consultation. Erythropoietin had been part of her medication regimen in the past for approximately 5 months without any associated pigmentary side effects.

The hyperpigmentation present since the initiation of SCF therapy was of significant concern. Although SCF certainly has a direct effect on the melanocyte, it is possible that the clinical hyperpigmentation noted at the injection site is a combination of direct (SCF) and indirect (mast

cell–released factors) stimulation of the melanocytes. SCF is known to promote mast cell hyperplasia<sup>10</sup> and mast cell release of inflammatory factors.<sup>11</sup> The patient did try topical clobetasol for 4 weeks, along with SCF injection in a new area on the left-lower buttock; however, marked reduction of the hyperpigmentation was not noted (Figure, C). Over time, the areas of hyperpigmentation that were not continuing to be injected with SCF gradually faded.

#### Comment

We present a patient with extensive hyperpigmentation in response to SCF. Previous reports described less extensive areas of hyperpigmentation (3 to 5 cm in diameter).<sup>10</sup> The dermatologic effects of SCF have been well described as a reaction localized to

injection sites. Erythema, pruritis, swelling, and hyperpigmentation have been reported.

Most patients have a pruritic wheal-and-flare response at the injection site approximately 90 to 120 minutes after subcutaneous injection.<sup>3,12</sup> Higher doses produce generalized rash, urticaria, cough, and throat tightness, likely due to mast cell degranulation,<sup>1</sup> as in our patient. Histologically, evidence of dermal mast cell degranulation has been reported.<sup>13</sup> Mast cells clearly play a role in the urticarial response, but their role in the hyperpigmentary response is less certain.

SCF has been noted to drive melanocyte proliferation and differentiation in culture.<sup>14</sup> SCF injection activates melanocytes in human skin xenografts, with an increase in cell number, size, and dendricity.<sup>15</sup> An inhibitor of the SCF receptor appears to have opposite manifestations.<sup>15</sup> Thus, melanocytes have the capacity to directly respond to SCF.

In vivo, the hyperpigmentary response may be a combination of both direct melanocytic stimulation and indirect effects due to mast cell–released factors. It has been proposed that inflammatory mediators and cytokines released during inflammation play an important role in the melanocytic response to inflammatory dermatoses,<sup>16</sup> presenting as either hypopigmentation or hyperpigmentation.<sup>17</sup> Histamine has been reported to stimulate normal human melanocytes in vitro.<sup>18</sup> Prostaglandin D<sub>2</sub> (PGD<sub>2</sub>) has been shown to potentiate melanogenesis in the murine system.<sup>19</sup> As topical steroids deplete cutaneous mast cells<sup>20</sup> and have been found to inhibit melanoblast proliferation,<sup>21</sup> using a topical steroid might reduce the hyperpigmentation from SCF-induced release of mast cell factors. However, after 4 weeks of topical clobetasol, no marked reduction in hyperpigmentation was apparent in our patient.

SCF was first purified in 1989, and since that time many potential uses have been hypothesized, including treatment of bone marrow failure syndromes and recovery from chemotherapy.<sup>22</sup> In the future, SCF and other cytokines may have utility in the treatment of melanocytic disease processes.

Much can be learned from SCF and its effects, as a number of diseases have been described with increased serum SCF concentrations that correlate with disease severity. Mycosis fungoides,<sup>23</sup> systemic sclerosis,<sup>24</sup> and the hyperpigmentation of dermatofibromas<sup>25</sup> may all be influenced by SCF. As serum SCF rises, pigmentation and pruritis worsen and the disease progresses.<sup>23,24</sup> Further characterization of SCF will be necessary to tailor therapy in those diseases with manifestations secondary to SCF and in those in which SCF may be therapeutic.

To our knowledge, this is the first report of extensive hyperpigmentation secondary to SCF injections. As clinicians, it is important to recognize SCF-induced cutaneous effects, including manifestations due to both mast cells and melanocytes. Hyperpigmentation can be a major cosmetic concern, and this needs to be taken into consideration when the location for subcutaneous injections is chosen.

*Acknowledgments*—SCF was provided on a compassionate use basis by Amgen Inc., Thousand Oaks, California. Funds for research have been provided by Duke Comprehensive Cancer Center benefactors, especially Rebecca Hundley, Carolyn Holding, Carma Ames, and gifts given in honor of James Matt. This work is supported by research grant R29 CA79036-05 from the National Institutes of Health, Bethesda, Md (Dr. Grichnik).

## REFERENCES

1. Morstyn G, Brown S, Gordon M, et al. Stem cell factor is a potent synergistic factor in hematopoiesis. *Oncology*. 1994;51:205-214.
2. Bernstein A, Forrester L, Reith AD, et al. The murine W/c-kit and Steel loci and the control of hematopoiesis. *Semin Hematol*. 1991;28:138-142.
3. Glaspy JA, Shpall EJ, LeMaistre CF, et al. Peripheral blood progenitor cell mobilization using stem cell factor in combination with filgrastim in breast cancer patients. *Blood*. 1997;90:2939-2951.
4. Dianzani I, Garelli E, Crescenzo N, et al. Diamond-Blackfan anemia: expansion of erythroid progenitors in vitro by IL-9, but exclusion of a significant pathogenic role for the IL-9 gene and the hematopoietic gene cluster on chromosome 5q. *Exp Hematol*. 1997;25:1270-1277.
5. de Vries P, Brasel KA, Eisenman JR. The effect of recombinant mast cell growth factor on purified murine hematopoietic stem cells. *J Exp Med*. 1991;173:1205-1211.
6. Bodine DM, Seidel NE, Zsebo KM. In vivo administration of SCF to mice increases the absolute number of pluripotent hematopoietic stem cells. *Blood*. 1993;82:445-455.
7. Lyman SD, Williams DE. Biological activities and potential therapeutic uses of steel factor. a new growth factor active on multiple hematopoietic lineages. *Am J Pediatr Hematol Oncol*. 1992;14:1-7.
8. Olivieri NF, Grunberger T, Ben-David Y. Diamond-Blackfan anemia: heterogeneous response of hematopoietic progenitor cells in vitro to the protein product of the mouse steel locus. *Blood*. 1991;78:2211-2215.
9. Grichnik JM, Crawford J, Jiminez F, et al. Human recombinant SCF induces melanocytic hyperplasia in susceptible patients. *J Amer Acad Dermatol*. 1995;33:577-583.

10. Costa JJ, Demetri GD, Harrist TJ, et al. Recombinant human stem cell factor (kit ligand) promotes human mast cell and melanocyte hyperplasia and functional activation in vivo. *J Exp Med*. 1996;183:2681-2686.
11. Columbo M, Horowitz EM, Botana EM, et al. The human recombinant c-kit receptor ligand, rhSCF, induces mediator release from human cutaneous mast cells and enhances IgE-dependent mediator release from both skin mast cells and peripheral blood basophils. *J Immunol*. 1992;149:599-608.
12. Costa JJ. Updates on cells and cytokines: the therapeutic use of hematopoietic growth factors. *J Allergy Clin Immunol*. 1998;101:1-6.
13. Dvorak AM, Costa JJ, Monahan-Earley RA, et al. Ultrastructural analysis of human skin biopsy specimens from patients receiving recombinant human stem cell factor: subcutaneous injection of rhSCF induces dermal mast cell degranulation and granulocyte recruitment at the injection site. *J Allergy Clin Immunol*. 1998;101:793-806.
14. Funasaka Y, Boulton T, Cobb M, et al. c-KIT kinase induces a cascade of protein tyrosine phosphorylation in normal human melanocytes in response to mast cell growth factor and stimulates mitogen-activated protein kinase but is down-regulated in melanomas. *Mol Biol Cell*. 1992;3:197-209.
15. Grichnik JM, Burch JA, Burchette J, et al. The SCF/KIT pathway plays a critical role in the control of normal human melanocyte homeostasis. *J Invest Dermatol*. 1998;111:233-238.
16. Morrelli JG, Norris DA. Influence of inflammatory mediators and cytokines on human melanocyte function. *J Invest Dermatol*. 1993;100(suppl 2):191S-195S.
17. Ruiz-Maldonado R, Orozco-Covarrubias M. Post-inflammatory hypopigmentation and hyperpigmentation. *Semin Cutan Med Surg*. 1997;16:36-43.
18. Tomita Y, Maeda K, Tagami H. Histamine stimulates normal human melanocytes in vitro: one of the possible inducers of hyperpigmentation in urticaria pigmentosa. *J Dermatol Sci*. 1993;6:146-154.
19. Nordlund, JJ, Collins CE, Rheins LA. Prostaglandin E2 and D2 but not MSH stimulate the proliferation of pigment cells in the pinnal epidermis of the DBA/2 mouse. *J Invest Dermatol*. 1986;86:433-437.
20. Lavker RM, Schechter NM. Cutaneous mast cell depletion results from topical corticosteroid usage. *J Immunol*. 1985;135:2368-2373.
21. Hirobe T. Hydrocortisone is involved in regulating the proliferation and differentiation of mouse epidermal melanoblasts in serum-free culture in the presence of keratinocytes. *Eur J Cell Biol*. 1996;71:387-394.
22. Smith MA, Pallister CJ, Smith JG. Stem cell factor: biology and relevance to clinical practice. *Acta Haematol*. 2001;105:143-150.
23. Yamamoto T, Katayama I, Nishioka K. Increased serum level of stem cell factor in association with disease progression of hyperpigmented mycosis fungoides. *Br J Dermatol*. 1999;140:765-766.
24. Yamamoto T, Sawada Y, Katayama I, et al. Local expression and systemic release of stem cell factor in systemic sclerosis with diffuse hyperpigmentation. *Br J Dermatol*. 2001;144:199-200.
25. Shishido E, Kadono S, Manaka I, et al. The mechanism of epidermal hyperpigmentation in dermatofibroma is associated with stem cell factor and hepatocyte growth factor expression. *J Invest Dermatol*. 2001;117:627-633.