

α_1 -Antitrypsin Deficiency Panniculitis

Jason McBean, BA; Amy Sable, MD; Jennifer Maude, MD; Leslie Robinson-Bostom, MD

GOAL

To understand the diagnosis and clinical and histologic manifestations of α_1 -antitrypsin deficiency panniculitis (A1ADP)

OBJECTIVES

Upon completion of this activity, dermatologists and general practitioners should be able to:

1. Describe the cutaneous manifestations of A1ADP.
2. Describe the histopathologic features of A1ADP.
3. Discuss treatment for A1ADP.

CME Test on page 226.

This article has been peer reviewed and approved by Michael Fisher, MD, Professor of Medicine, Albert Einstein College of Medicine. Review date: February 2003.

This activity has been planned and implemented in accordance with the Essential Areas and Policies of the Accreditation Council for Continuing Medical Education through the joint sponsorship of Albert Einstein College of Medicine and Quadrant HealthCom, Inc. The Albert Einstein College of

Medicine is accredited by the ACCME to provide continuing medical education for physicians.

Albert Einstein College of Medicine designates this educational activity for a maximum of 1 category 1 credit toward the AMA Physician's Recognition Award. Each physician should claim only those credits that he/she actually spent in the activity.

This activity has been planned and produced in accordance with ACCME Essentials.

Mr. McBean and Drs. Sable, Maude, and Robinson-Bostom report no conflict of interest. The authors report off-label use of dapsone. Dr. Fisher reports no conflict of interest.

α_1 -Antitrypsin deficiency panniculitis (A1ADP) is a rare form of panniculitis that affects children and adults. Clinical and histologic features, precipitating factors, and treatments are discussed.

Accepted for publication January 31, 2003.

From Brown Medical School, Providence, Rhode Island. Mr. McBean is a medical student, Dr. Sable is a Resident at Rhode Island Hospital, Dr. Maude is a Clinical Instructor, and Dr. Robinson-Bostom is an Assistant Professor of Dermatology. Reprints: Leslie Robinson-Bostom, MD, Department of Dermatology, Brown Medical School, Rhode Island Hospital, 593 Eddy St, APC 10, Providence, RI 02903 (e-mail: lrobinson-bostom@lifespan.org).

α_1 -Antitrypsin, a serine protease inhibitor synthesized in the liver, regulates the action of proteolytic enzymes including trypsin, collagenase, elastase, factor VIII, chymotrypsin, and kallikrein. A deficiency of this protein is hypothesized to lead to inadequate inhibition of proteases released by neutrophils and monocytes, which in turn results in unchecked inflammation and tissue necrosis.¹ The systemic sequelae of this phenomenon include panacinar emphysema, hepatitis, cirrhosis, hemorrhagic diathesis, and panniculitis.² Panniculitis most commonly occurs in patients with the severe homozygous deficiency PiZZ phenotype, resulting

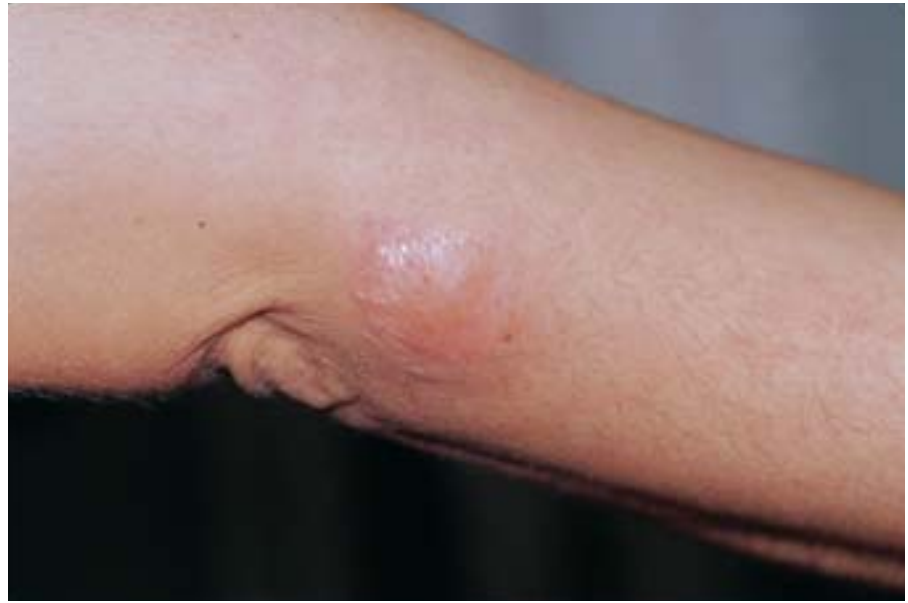

Figure 1. Tender indurated nodule on the medial area of the left elbow.

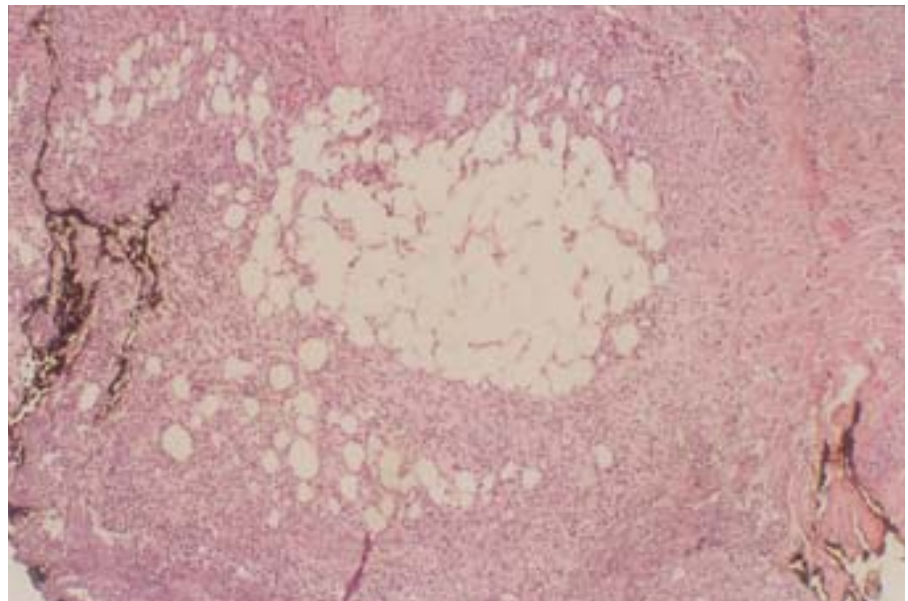


Figure 2. Lobular and septal panniculitis with normal fat lobules adjacent to necrotic lobules (H&E, original magnification $\times 10$).

in serum α_1 -antitrypsin levels that are 10% of normal. The lesions may mimic cellulitis and are most frequently found on the trunk and proximal extremities. Characteristic microscopic features include neutrophils between collagen bundles in reticular dermis, septal panniculitis with liquefactive necrosis, and collagenolysis with large areas of normal fat lobules adjacent to necrotic fat.³

Case Report

After falling down the stairs at home, a previously healthy 40-year-old woman presented to the emergency department with a tender edematous

25-cm hematoma on the right lateral thigh. The patient was treated empirically for an infected hematoma; use of oral antibiotics resulted in partial improvement. Subsequently, atraumatic indurated plaques and nodules developed on the extremities; these plaques and nodules were minimally responsive to oral and intravenous antibiotics. The hematoma was incised and drained. Culture results were negative for bacterial and fungal growth. Serous fluid drained from a left-buttock nodule that had spontaneously ulcerated. The patient was admitted to our hospital for further diagnosis and management.

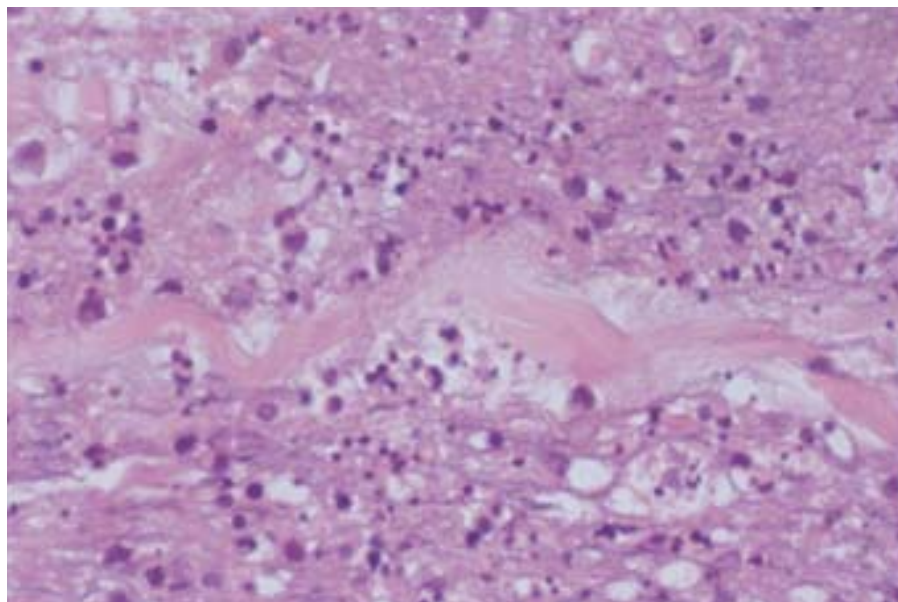


Figure 3. Pools of neutrophils with liquefactive necrosis and collagenolysis (H&E, original magnification $\times 20$).

The patient was comfortable and nontoxic. Her temperature was 99.8°F, and her heart rate was 88 bpm. Distributed over the right axilla, the medial area of the left elbow, the left ankle, the distal area of the right tibia, and the lateral area of the right thigh were multiple, deep, red, tender, indurated, 4- to 25-cm nodules and plaques (Figure 1). On the left buttock was an ulcerated 5-cm nodule.

A biopsy of the right axillary lesion was performed. Results of histologic examination showed normal epidermis and dermis. Mixed lobular and septal panniculitis included normal fat lobules adjacent to necrotic fat lobules (Figure 2). The infiltrate was composed of lymphocytes, histiocytes, and pools of neutrophils with suppuration, liquefactive necrosis, and collagenolysis (Figure 3). Neutrophils were splayed between collagen bundles (Figure 4). Granulomata were not evident, and there was no evidence of vasculitis. Periodic acid–Schiff, Gram, and acid-fast bacillus stains were negative for microorganisms. Refractile material was not evident under polariscopic examination. The microscopic differential diagnosis included infections, factitial panniculitis, subcutaneous Sweet syndrome, pancreatic fat necrosis, and α_1 -antitrypsin deficiency panniculitis (A1ADP).

Levels of antineutrophil cytoplasmic antibodies (p-ANCA, c-ANCA), C3, C4, and CH50 were normal. Cryoglobulins were not detected. Complete blood cell count and amylase and lipase levels were normal. Erythrocyte sedimentation rate was elevated (52 mm/h).

Serum α_1 -antitrypsin level was 37.0 mg/dL (reference range, 84–218 mg/dL) with a ZZ pheno-

type. Results of a chest radiograph, liver function tests, and pulmonary function tests were normal.

Given the clinical and pathologic findings and the results from the genetic α_1 phenotyping, α_1 -antitrypsin deficiency was diagnosed. The patient, treated with dapsone, improved dramatically.

Comment

α_1 -Antitrypsin, a polypeptide glycoprotein synthesized by hepatocytes, inhibits collagenase, elastase, factor VIII, chymotrypsin, and kallikrein.¹

α_1 -Antitrypsin is an acute-phase reactant that increases in serum concentration with stress from illness or trauma. Protease activation in the absence of α_1 -antitrypsin may trigger a cascade of inflammatory events that ultimately damage the tissues they are meant to protect.² Speculation is that absence of α_1 -antitrypsin allows inflammation to continue unabated and thus leads to panniculitis.

α_1 -Antitrypsin deficiency most frequently causes severe and rapidly progressive panacinar emphysema. This deficiency also is associated with hepatitis, cirrhosis, vasculitis, acquired angioedema, Marshall syndrome, and severe psoriasis.⁴ Recently, α_1 -antitrypsin deficiency was used as a model for conformational diseases (including liver cirrhosis) and neurodegenerative disorders (including Alzheimer disease and spongiform encephalopathies).⁵

Serum concentration of α_1 -antitrypsin is determined by inheritance of autosomal codominant alleles—M, S, and Z being the most common.⁶ Most cases of A1ADP occur in individuals with a severe homozygous deficiency (ZZ phenotype).³ Ninety-five percent of the US population shares

the normal protease inhibitor MM phenotype designated type M. SZ heterozygotes have one third of the normal inhibitor level and a relatively low risk of developing emphysema.⁶ Prevalence of the SZ phenotype ranges from 1 in 180 to 1 in 2500 individuals, depending on geographic location.⁷ Type Z, an α_1 -antitrypsin variant, differs from the M protein by a single amino acid substitution (lysine for glutamic acid).¹ This substitution results in a changed conformation leading to inhibition of α_1 -antitrypsin release from hepatocytes and decreased serum levels in patients with the protease inhibitor ZZ phenotype. Homozygous deficiency occurs in about 1 in 2500 individuals; heterozygous deficiency occurs in about 1 in 50.

The case reported here demonstrates many important features of A1ADP. First, our patient linked the onset of her symptoms to her fall down the stairs and her resulting injury of the right lower extremity. Another reviewer found that 6 of 18 cases of A1ADP were precipitated by trauma,⁸ and an investigator reported the case of a patient who had subclinical α_1 -antitrypsin deficiency and who developed panniculitis after trauma induced by cryosurgery.⁹

Second, our case demonstrates the typical clinical characteristics of A1ADP, including location on the proximal area of the lower extremities and axilla and drainage of serous fluid. Lesions of this disease begin as tender, erythematous, indurated subcutaneous nodules that may be widely disseminated on the trunk or extremities. These lesions spontaneously ulcerate and drain oily, serosanguineous fluid.¹ As reported in a review, 16 patients developed such lesions predominantly on the trunk and proximal area of the extremities.⁸

Third, our patient was diagnosed with a secondarily infected hematoma and cellulitis; repeated trials of antibiotics failed. Antibacterial treatment is completely ineffective in the management of A1ADP. Failure of multiple trials of oral antibiotics and intravenous antibiotics exemplifies the difficulties encountered in making the diagnosis of A1ADP.

Integral to the diagnosis of our patient's condition was the right axillary skin biopsy and laboratory evaluation of serum α_1 -antitrypsin level. Foci of fat necrosis adjacent to large areas of normal fat and acute lobular panniculitis with a large number of neutrophils are characteristic findings.

Other histologic findings should be addressed. Geller and Su³ described the earliest histopathologic findings of A1ADP as splaying of neutrophils between collagen bundles in the reticular dermis. Degeneration of collagen within the dermis, progressive dermal necrosis, and subsequent involvement

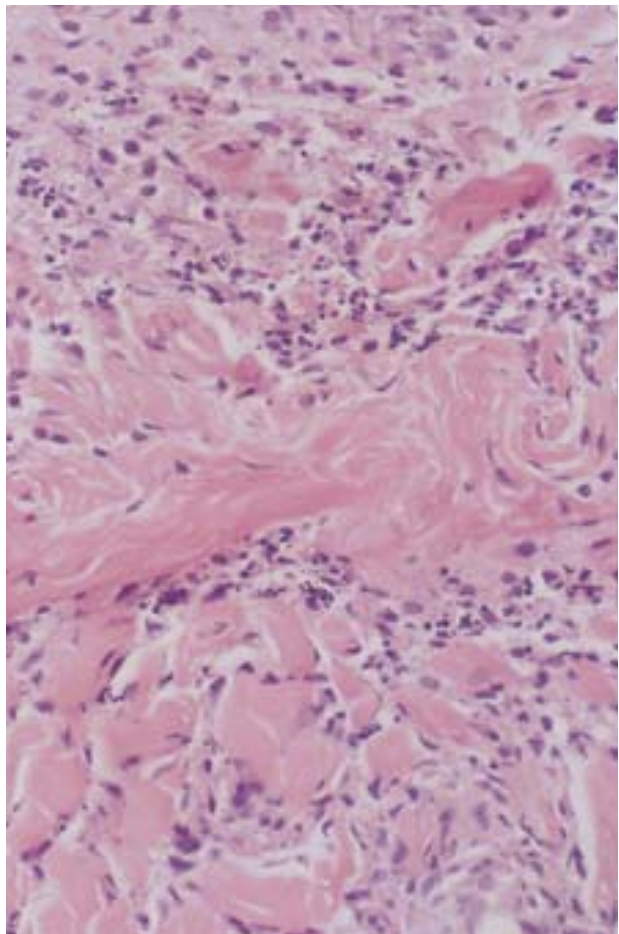


Figure 4. Neutrophils splayed between collagen bundles (H&E, original magnification $\times 20$).

of fibrous septa and subcutaneous fat are additional features of A1ADP. Therefore, histologic examination is an important diagnostic tool.

The cornerstone of the diagnosis in our patient's case was the finding of a low level of α_1 -antitrypsin (37.0 mg/dL) and P1 typing of ZZ. Given the availability of the assay and the prolonged diagnostic challenge marked by multiple unsuccessful trials of antibiotics, running the assay earlier in the workup may be beneficial in cases with a high index of suspicion.

Treatment of A1ADP should include avoidance of trauma and surgical debridements—frequent precipitating factors of panniculitis.¹⁰ Dapsone, seemingly the treatment of choice, has been anecdotally effective in a number of cases of A1ADP. For homozygous patients who have severe forms of the disease and who present with severe emphysema and liver failure, supplemental infusion of exogenous α_1 protease inhibitor concentrate has been suggested as the most important therapeutic possibility.⁹

A1ADP is difficult to diagnose but should be considered when a patient with recurrent painful indurated plaques presents after sustaining a localized trauma.

REFERENCES

1. Edmonds BK, Hodge JA, Rietschel RL. Alpha 1-antitrypsin deficiency-associated panniculitis: case report and review of the literature. *Pediatr Dermatol*. 1991;8:296-299.
2. Hendrick SJ, Silverman AK, Solomon AR, et al. Alpha 1-antitrypsin deficiency associated with panniculitis. *J Am Acad Dermatol*. 1988;18(4 pt 1):684-692.
3. Geller JD, Su WP. A subtle clue to the histopathologic diagnosis of early alpha 1-antitrypsin deficiency panniculitis. *J Am Acad Dermatol*. 1994;31(2 pt 1):241-245.
4. Freedberg IM, Eisen AZ, Wolff K, et al, eds. *Fitzpatrick's Dermatology in General Medicine*. Vol 1. 5th ed. New York, NY: McGraw-Hill; 1999.
5. Carrell RW, Lomas DA. Alpha 1-antitrypsin deficiency—a model for conformational diseases. *N Engl J Med*. 2002;346:45-53.
6. Phelps RG, Shoji T. Update on panniculitis. *Mt Sinai J Med*. 2001;68:262-267.
7. Chng WJ, Henderson CA. Suppurative panniculitis associated with alpha 1-antitrypsin deficiency (PiSZ phenotype) treated with doxycycline. *Br J Dermatol*. 2001;144:1282-1283.
8. Smith KC, Pittelkow MR, Su WP. Panniculitis associated with severe alpha 1-antitrypsin deficiency: treatment and review of the literature. *Arch Dermatol*. 1987;123:1655-1661.
9. Linares-Barrios M, Conejo-Mir IS, Artola Igarza JL, et al. Panniculitis due to alpha 1-antitrypsin deficiency induced by cryosurgery. *Br J Dermatol*. 1988;138:552-553.
10. Requena L, Sanchez Yus E. Panniculitis, part II: mostly lobular panniculitis. *J Am Acad Dermatol*. 2001;45:325-361.

DISCLAIMER

The opinions expressed herein are those of the authors and do not necessarily represent the views of the sponsor or its publisher. Please review complete prescribing information of specific drugs or combination of drugs, including indications, contraindications, warnings, and adverse effects before administering pharmacologic therapy to patients.

FACULTY DISCLOSURE

The Faculty Disclosure Policy of the Albert Einstein College of Medicine requires that faculty participating in a CME activity disclose to the audience any relationship with a pharmaceutical or equipment company that might pose a potential, apparent, or real conflict of interest with regard to their contribution to the activity. Any discussions of unlabeled or investigational use of any commercial product or device not yet approved by the US Food and Drug Administration must be disclosed.