



Robotic vesicovaginal fistula repair: A systematic, endoscopic approach

⬇ Although traditionally rare, this is a challenging repair that you may begin to encounter more often. Here, steps to an expert approach to fistulas resulting from surgical interventions.

Lennox Hoyte, MD

In modern times in the United States, the vesicovaginal fistula (VVF) arises chiefly as a sequela of gynecologic surgery, usually hysterectomy. The injury most likely occurs at the time of dissection of the bladder flap off of the lower uterine segment and upper vagina.¹ With increasing use of endoscopy and electrosurgery at the time of hysterectomy,² the occurrence of VVF is likely to increase. Because of this, fistulas stemming from benign gynecologic surgical activity tend to occur above the trigone near the vaginal cuff.

Current technique of fistula repair involves either a vaginal approach, with the Latsko procedure,³ or an abdominal approach, involving a laparotomy; laparoscopy also is used with increasing frequency.⁴

Vaginal versus endoscopic approach. The vaginal approach can be straightfor-

ward, such as in cases of vault prolapse or a distally located fistula, or more difficult if the fistula is apical in location, especially if the apex is well suspended and the vagina is of normal length. I have found the abdominal approach to be optimal if the fistula is near the cuff and the vagina is of normal length and well suspended.

Classical teaching tells us that the first repair of the VVF is likely to be the most successful, with successively lower cure rates as the number of repair attempts increases. For this reason, I advocate the abdominal approach in most cases of apically placed VVFs.

Surgical approach

Why endoscopic, why robotic? Often, repair of the VVF is complicated by:

- the challenge of locating the defect in the bladder
- the technical difficulty in oversewing the bladder, which often must be done on the underside of the bladder, between the vaginal and bladder walls.

To tackle these challenges, an endoscopic approach promises improved visualization, and the robotic approach allows for surgical closure with improved visibility characteristic of endoscopy, while preserving the manual dexterity characteristic of open surgery.

IN THIS ARTICLE

Stenting the fistula
page 22

Dissecting the vaginal wall
page 24

Key takeaways
page 28

ON THE WEB

Watch the videos that accompany this article in the Video Library, at obgmanagement.com



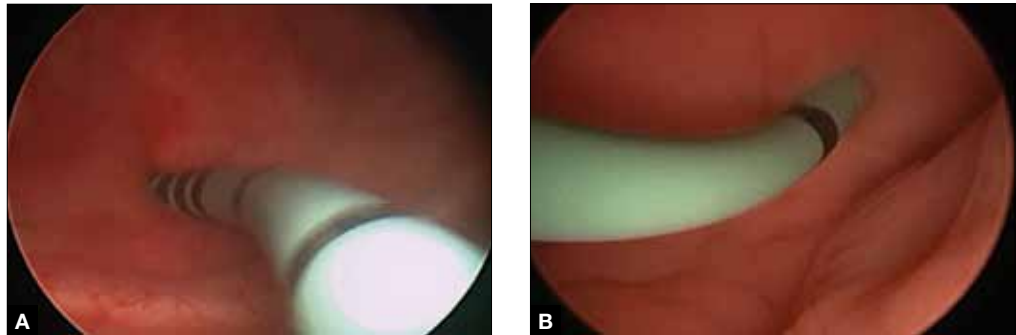
Dr. Hoyte is Director, Urogynecology and Female Pelvic Reconstructive Surgery, University of South Florida College of Medicine; Medical Director, Urogynecology and Robotic Surgery, Tampa General Hospital; and Chief Medical Information Officer, University of South Florida Physicians Group, Tampa, Florida.

The author reports being a consultant, proctor, and course director for Intuitive Surgical.

CONTINUED ON PAGE 22



FIGURE 1 Stent insertion



Cystoscopically place a 6 French blue stent into the bladder side of the fistula. (A) The stent as seen from inside the bladder. (B) The stent as seen from the vaginal side.

Timing. It is believed that, in order to improve chances of successful surgical repair, the fistula should be approached either immediately (ie, within 1 to 2 weeks of the insult) or delayed by 8 to 12 or more weeks after the causative surgery.⁵

Preparation. Vesicovaginal fistulas can rarely involve the ureters, and this ureteric involvement needs to be ruled out. Accordingly, the workup of the VVF should begin with a thorough cystoscopic evaluation of the bladder, with retrograde pyelography to evaluate the integrity of the ureters bilaterally.

During this procedure, the location of the fistulous tract should be meticulously mapped. Care should be taken to document the location and extent of the fistula, as well as to identify the presence of multiple or separate tracts. If these tracts are present, they also need also to be catalogued. In my practice, the cystoscopy/retrograde pyelogram is performed as a separate surgical encounter.

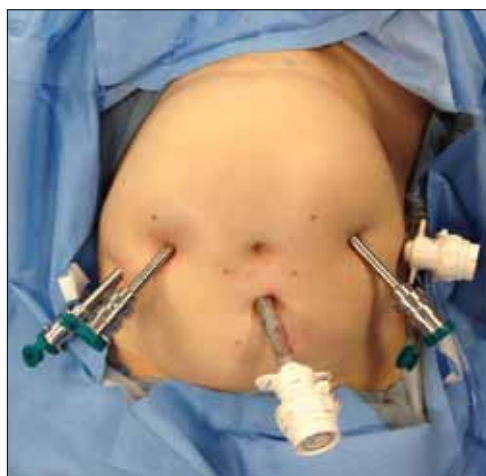FAST TRACK

Meticulous cystoscopic mapping of the fistulous tract is imperative presurgically

Surgical technique

After the fistula is mapped and ureteric integrity is confirmed, the definitive surgical repair is performed. The steps to the surgical approach are straightforward.

FIGURE 2 Ideal port placement



Place the camera port supraumbilically, with two 8-mm robot ports to the left side of the umbilicus and one to the right. Separate each port by approximately 10 cm. Place an assistant port to the far right for passing and retrieving sutures.

1. Insert stents into the fistula and bilaterally into the ureters

Stenting the fistula permits rapid identification of the fistula tract without the need to enter the bladder separately. The ureteric stents you use should be one color, and the fistula stent should be a second color. I use 5 French yellow stents to cannulate the ureters and a 6 French blue stent for the fistula itself. Insert the fistula stent from the bladder side of the fistula. It should exit through the vagina (FIGURES 1A and 1B). In addition, place a 3-way Foley catheter for drainage and irrigate the bladder when indicated.

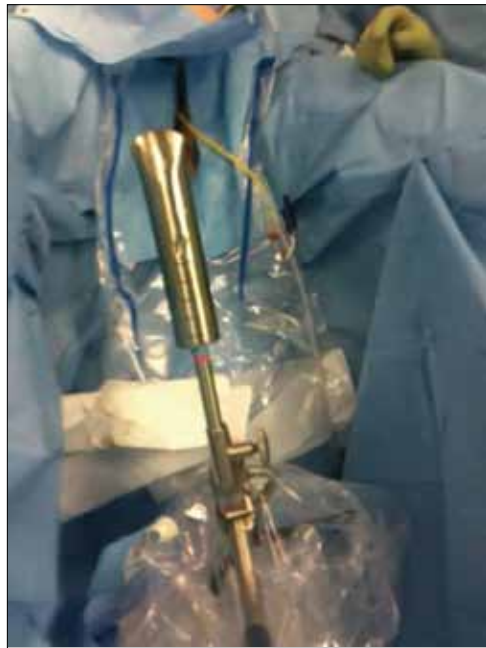2. Place the ports for optimal access

A 0° camera is adequate for visualization. Port placement is similar to that used for

CONTINUED ON PAGE 24



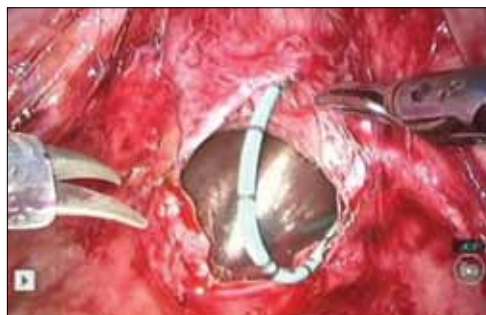FIGURE 3 Stent and uterine positioning



The rounded and flattened tip of the stent should have an extended handle available for manipulation by an assistant or for attachment to an external uterine positioning system.

robotic sacral colpopexy; I use a supraumbilically placed camera port and three 8-mm robot ports (two on the left and one on the right of the umbilicus). Each port should be

FIGURE 4 Visualization of the fistula stent



The blue stent in the fistula should be visible at the anterior vaginal wall. The larger silver stent, shown here in the vagina, also acts to preserve the pneumoperitoneum.

separated by about 10 cm. An assistant port is placed to the far right, for passing and retrieving sutures (FIGURE 2). An atraumatic grasper, monopolar scissors, and bipolar Maryland-type forceps are placed within the ports to begin the surgical procedure.

3. Place a vaginal stent to aid dissection

The stent should be a sterile cylinder and have a diameter of 2 cm to 5 cm (to match the vaginal caliber). The tip should be rounded and flattened, with an extended handle available for manipulating the stent. The handle can be held by an assistant or attached to an external uterine positioning system (FIGURE 3); I use the Uterine Positioning System™ (Cooper Surgical, Trumbull, Connecticut).

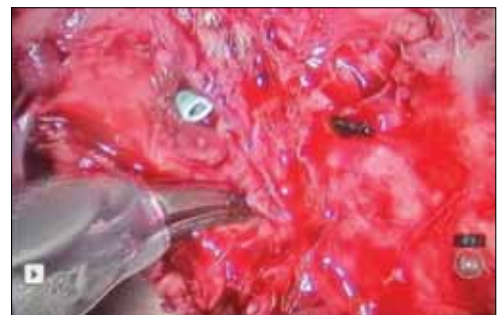4. Incise the vaginal cuff

Transversely incise the vaginal cuff with the monopolar scissors (VIDEO 1). This allows free entry into the vagina at the apex. The blue stent in the fistula should be visible at the anterior vaginal wall, as demonstrated in FIGURE 4.

5. Dissect the vaginal wall

Dissect the anterior vaginal wall down to the fistula, and dissect the bladder off of the vaginal wall for about 1.5 cm to 2 cm around the fistula tract (FIGURE 5 and VIDEO 2).

FIGURE 5 Dissect the vaginal wall



Dissect the anterior vaginal wall down to the fistula, and dissect the bladder off of the vaginal wall for about 1.5 cm to 2 cm around the fistula tract.

WATCH VIDEO 1!



Use this QR code to download the video to your Smartphone,* or go to obgmanagement.com

*Free QR readers are available at the iPhone App Store, Android Market, and BlackBerry App World.

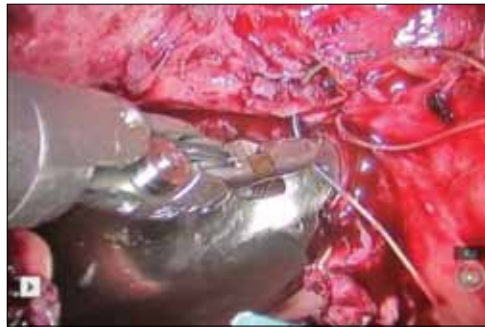
WATCH VIDEO 2!



Use this QR code to download the video to your Smartphone, or go to obgmanagement.com



FIGURE 6 Close the bladder



Stitch the bladder in a running fashion using three layers of 3-0 rapid absorbable synthetic suture. Keep the closure line free of tension.

6. Cut the stent

Cut the stent passing thru the fistula, to move it out of the way.

7. Close the bladder

Stitch the bladder in a running fashion using three layers of 3-0 rapid absorbable synthetic suture (FIGURE 6 and VIDEO 3). I prefer polyglactin 910 (Vicryl; Ethicon, Somerville, New Jersey) because it is easier to handle.

8. Close the vaginal side of the fistula

Stitch the vaginal side of the fistula in a running fashion with 2-0 absorbable synthetic suture.

9. Verify closure

Check for watertight closure by retrofilling the bladder with 100 mL of sterile milk (obtained from the labor/delivery suite). Observe the suture line for any evidence of milk leakage. (Sterile milk does not stain the

tissues, and this preserves tissue visibility. For this reason, milk is preferable to indigo carmine or methylene blue.)

10. Remove all stents from the bladder

Cystoscopically remove all stents.

11. Close the laparoscopic ports

12. Follow up to ensure surgical success

Leave the indwelling Foley catheter in place for 2 to 3 weeks. After such time, remove the catheter and perform voiding cystourethrogram to document bladder wall integrity.

Discussion

I have described a systematic approach to robotic VVF repair. The robotic portion of the procedure should require about 60 to 90 minutes in the absence of significant adhesions. The technique is amenable to a laparoscopic approach, when performed by an appropriately skilled operator.

Final takeaways. Important takeaways to this repair include:

- Stent the fistula to make it easy to find intraoperatively.
- Enter the vagina from above to rapidly locate the fistula tract.
- Use sterile milk to fill the bladder to look for leaks. This works without staining the tissues.
- Minimize tension on the bladder suture line. ☹

References

1. Forsgren C, Lundholm C, Johansson AL, Cnattingius S, Altman D. Hysterectomy for benign indications and risk of pelvic organ fistula disease. *Obstet Gynecol.* 2009;114(3):594-599.
2. Turner LC, Shepherd JP, Wang L, Bunker CH, Lowder JL. Hysterectomy surgical trends: a more accurate depiction of the last decade? *Am J Obstet Gynecol.* 2013;208(4):277.e1-e7.
3. Crosby EC, Berger MB, Delancey JO. Vaginal approach to vesicovaginal fistula and vaginal vault prolapse preserving sexual function by latzko repair and sacrospinous suspension. *Female Pelvic Med Reconstr Surg.* 2012;18(5):306-307.
4. Zhang Q, Ye Z, Liu F, Qi X, Shao C, Zhang D. Laparoscopic transabdominal transvesical repair of supratrigonal vesicovaginal fistula. *Int Urogynecol J.* 2013;24(2):337-342.
5. Lee R, Symmonds R, Williams T. Current status of genitourinary fistula. *Obstet Gynecol.* 1988;72(3 Pt 1):313-319.

WATCH VIDEO 3!



Use this QR code to download the video to your Smartphone, or go to obgmanagement.com



Watch the videos that accompany this article

1. Incise the vaginal cuff
2. Dissect the vaginal wall
3. Close the bladder

These videos were provided by Lennox Hoyte, MD.

View them in the Video Library at obgmanagement.com