

Photo Recall Effect in Association With Cefazolin

Luis A. Garza, MD, PhD; Elisa K. Yoo, MD; Jacqueline M. Junkins-Hopkins, MD; Abby S. VanVoorhees, MD

Patients in remission from local dermatitis secondary to external beam radiation treatments occasionally experience recurrence with systemic chemotherapy, a reaction termed radiation recall. Chemotherapy-induced photo recall from a prior exposure to the sun also has been reported. Rare reports describe photo recall effects from more commonly used medications. We report the case of a patient who developed a photo recall reaction after treatment with cefazolin. Results of the shave biopsy were consistent with a mild phototoxic eruption.

Cutis. 2004;73:79-80, 85.

Case Report

A 34-year-old woman was admitted to the hospital for removal of a meningioma after seeking attention for blurred vision. Magnetic resonance imaging revealed compression of the optic nerve by a mass in the sella turcica. The tumor was removed successfully by performing a right frontotemporal craniotomy.

Postoperatively, the patient was given acetaminophen, cefazolin, codeine, dexamethasone, ondansetron, phenytoin, and ranitidine. She had not taken any of these medications preoperatively.

On the first postoperative day, the patient noted marked erythema of her upper chest, shoulders, and arms in a sun-exposed pattern, sparing the breasts and the "strap lines" of her tank top (Figure). This rash was in the same distribution as that of a severe sunburn our patient had sustained several weeks earlier while wearing a tank top with straps. The sunburn had completely resolved before admission. Since admission, the patient had worn only the typical patient gown, and she did not have a bed near

a window. She denied any sun exposure since admission or wearing any garments matching the sun-protected areas.

The patient was given 2 doses of diphenhydramine and switched from phenytoin to valproic acid. However, the erythema on her chest persisted. Forty-eight hours later, cefazolin was discontinued, and a biopsy was performed. On discontinuation of the cefazolin, the erythema decreased markedly in 24 hours, with complete resolution over the next 48 hours. The patient was discharged several days later with no additional changes to her medication regimen, including no changes to ranitidine.

Results of the biopsy showed a mild, perivascular, lymphocytic infiltrate with rare apoptotic keratinocytes, consistent with a mild phototoxic eruption or sunburn.

Comment

Oncologists have noted that radiodermatitis occasionally recurs with exposure to chemotherapeutic agents. This recall dermatitis recapitulates the original insult. It has been described as edematous, erythematous, desquamated, macular, papular, vesiculated, or ulcerated, with or without pruritus.¹ The length of quiescence before recurrence has been reported up to years, though most cases arise within weeks to months of the initial exposure. Recall reactions are not limited to the skin and also have been reported as oropharyngeal mucositis, esophagitis, and pneumonitis.²

Although the original insult may include radiation from external beam therapy, it also has been reported from sun exposure.³ The precipitating agent initially was limited to chemotherapeutic agents, such as methotrexate.⁴ Only recently have scattered reports described other agents.⁵⁻⁸ To our knowledge, this report is the second to describe recall dermatitis associated with cefazolin therapy,⁵ and the second highlighting the role of antibiotics in this reaction.⁸

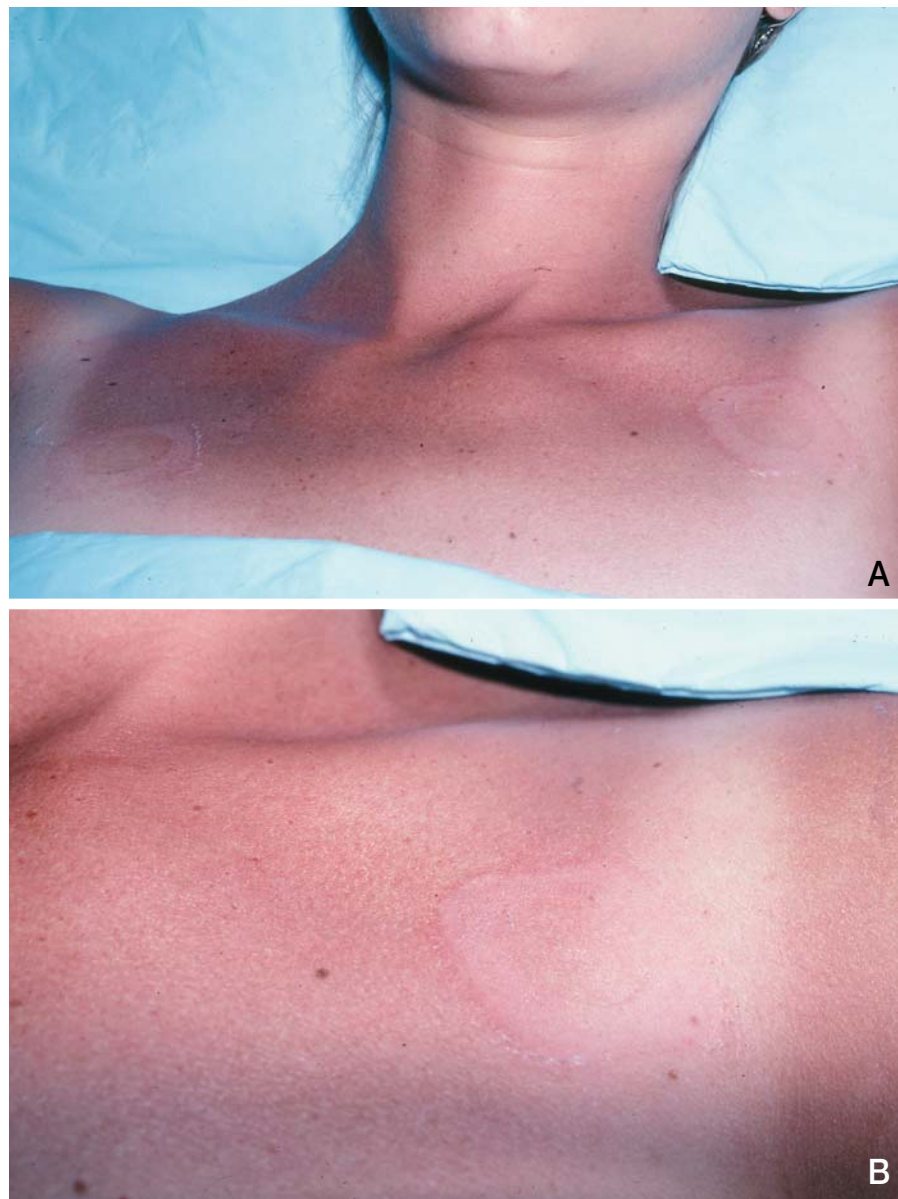
Flax and Uhle⁵ described a patient who experienced a photo recall effect while taking cefazolin

Accepted for publication July 16, 2003.

From the Department of Dermatology, University of Pennsylvania School of Medicine, Philadelphia.

The authors report no conflict of interest.

Reprints: Abby VanVoorhees, MD, Department of Dermatology, 2nd Floor, Rhodes Pavilion, HUP, 3400 Spruce St, Philadelphia, PA 19104 (e-mail: abby.vanvoorhees@uphs.upenn.edu).



Upper chest of the patient with the diffuse erythema sparing the “strap lines” of her tank top (A and B).

and gentamicin. The pruritic, erythematous, and maculopapular rash appeared 48 hours after dosing and spared the areas covered by clothing. Likewise, our patient also was taking cefazolin, and its discontinuation led to the immediate resolution of her rash. We therefore propose that in the Flax and Uhle’s patient, the cefazolin was the medication responsible for the rash. Interestingly, although their patient⁵ presented with a maculopapular pattern not typical of a radiation recall reaction at the site of sun damage, our patient showed a diffuse erythema more characteristic of the recall phenomenon.

Several types of photo-related processes have been described. These include phototoxicity, photoallergy, polymorphic light eruption, actinic

prurigo, and hydroa vacciniforme. Excluding a photoallergic response, all of these photosensitivities occur within hours. While a photoallergic response can occur sometime after sun exposure, the delay is seldom as long as a week, and the response is more commonly papular, vesicular, or eczematolike. Therefore, the timing of our patient’s rash is more characteristic of radiation recall, where an initial dermatitis secondary to radiation remits and then suddenly recurs with chemotherapy. We propose that our patient’s sun damage was “recalled” by one of her medications.

The mechanism for a photo recall effect of cefazolin is unknown. Moreover, the mechanism for

CONTINUED ON PAGE 85

CONTINUED FROM PAGE 80

the more classic radiation recall effect is also unknown. Current hypotheses to explain radiation recall center around subcritical damage to stem cell populations in the skin during localized radiation. Although healing occurs, there is believed to be long-lived increased susceptibility to a second insult.⁹ The mechanism for this damage is thought to be a result of DNA damage or a limited number of residual stem cells, or both. Thus, it is believed that systemic chemotherapy selectively affects this damaged population of stem cells. Experimental data, however, have failed to support this hypothesis.¹⁰ A more plausible model hypothesizes that areas of previous damage up-regulate immunomodulatory elements like vascular adhesion factors, which selectively attract inflammatory cells to recently healed areas.⁸

Given the frequency of cefazolin use, it is important for dermatologists to be aware of this uncommon reaction, which, traditionally, has been associated with chemotherapeutic agents.

REFERENCES

1. Burstein HJ. Side effects of chemotherapy, case 1: radiation recall dermatitis from gemcitabine. *J Clin Oncol*. 2000;18:693-694.
2. Schweitzer VG, Juillard GJ, Bajada CL, et al. Radiation recall dermatitis and pneumonitis in a patient treated with paclitaxel. *Cancer*. 1995;76:1069-1072.
3. Moller H. Reactivation of acute inflammation by methotrexate. *J Invest Dermatol*. 1969;52:437-441.
4. Vogler WR, Huguley CM Jr, Kerr W. Toxicity and anti-tumor effect of divided doses of methotrexate. *Arch Intern Med*. 1965;115:285-293.
5. Flax SH, Uhle P. Photo recall-like phenomenon following the use of cefazolin and gentamicin sulfate. *Cutis*. 1990;46:59-61.
6. Shelley WB, Shelley ED, Campbell AC, et al. Drug eruptions presenting at sites of prior radiation damage (sunlight and electron beam). *J Am Acad Dermatol*. 1984;11:53-57.
7. Abadir R, Liebmann J. Radiation reaction recall following simvastatin therapy: a new observation. *Clin Oncol (R Coll Radiol)*. 1995;7:325-326.
8. Krishnan RS, Lewis AT, Kass JS, et al. Ultraviolet recall-like phenomenon occurring after piperacillin, tobramycin and ciprofloxacin therapy. *J Am Acad Dermatol*. 2001;44:1054-1058.
9. Gabel C, Eifel PJ, Tornos C, et al. Radiation recall reaction to idarubicin resulting in vaginal necrosis. *Gynecol Oncol*. 1995;57:266-269.
10. Kitani H, Kosaka T, Fujihara T, et al. The "recall effect" in radiotherapy: is subeffective, repairable damage involved? *Int J Radiat Oncol Biol Phys*. 1990;18:689-695.