

Anorectal Melanoma—3 Case Reports and a Review of the Literature

Abrar Maqbool, MD; Rebecca Lintner, MD; Aqiba Bokhari, MD; Tariq Habib, MD; Irfan Rahman, MD; Babar K. Rao, MD

Anorectal melanoma is an uncommon disease. Histologically, the tumor may mimic adenocarcinomas, small cell carcinomas, and sarcomas; grossly, the lesion often mimics hemorrhoids. We report 3 cases of anorectal melanoma: a 40-year-old woman with anorectal melanoma with local recurrence after an abdominoperineal resection (APR); a 30-year-old woman with anorectal melanoma and multiple liver metastases returning with multiple masses in the rectum and 2 nodules above and below the left clavicle after receiving chemotherapy; and a 62-year-old woman with inguinal node metastases. The histologic findings in all 3 cases revealed malignant tumor composed of atypical melanocytes diagnosed as malignant melanoma of the rectum. In the first case, APR with pararectal lymphadenectomy was performed. Histopathology revealed nodal metastasis. The patient was noncompliant with chemotherapy and died after several months. In the second case, chemotherapeutic treatment was begun. Seven months after receiving chemotherapy, the patient returned with multiple metastases. The final case was lost to follow-up after referral to an oncologist. Anorectal melanoma is highly aggressive and unresponsive to both radical surgery and local control. Although supplemental therapy may improve quality of life and prolong survival, the 5-year survival rate is 10% with a mean survival time of 15 to 25 months. In the 3 cases presented, metastatic

disease was present at the time of diagnosis. At this stage, APR with lymphadenectomy followed by some form of adjuvant therapy is our recommended treatment.

Cutis. 2004;73:409-413.

Case Reports

Patient 1—A 40-year-old woman came to the emergency department complaining of rectal pain and an accompanying sensation of fullness in her rectum for 2 months. She reported having intermittent bloody stools, as well as diarrhea alternating with constipation, for the previous 6 months. She also admitted to a history of weight loss and reduced appetite.

Results of the physical examination were unremarkable. The anorectal inspection revealed prolapse of the rectum with strangulated hemorrhoids. Digital rectal examination could not be performed because of pain. During vaginal examination, palpation revealed a firm, slightly tender growth extending from the rectum to the anal verge. Laboratory data revealed low hemoglobin and hematocrit levels. The patient's serum carcinoembryonic antigen level was 1.5 ng/mL (reference range, <3.0). Abdominal ultrasound showed an 11.2×5.8-cm rectal mass. No enlarged lymph nodes or focal lesions in other organs were noted. There were no metastases detected in the liver or in the pararectal or paraaortic lymph nodes. Results of a computed tomography scan were consistent with the ultrasound findings. Examination under anesthesia showed a fungiform growth in the lateral wall of the rectum extending into the anal canal. A biopsy of the rectal mass was performed.

The biopsy specimens showed a malignant tumor composed of fibrovascular tissue invaded by malignant atypical melanocytes. The cells were arranged in sheets and trabeculae of round- to spindle-shaped cells, with prominent nuclei and nucleoli. There were 2 to 3 mitotic figures per high-power field, and scattered melanin pigment was present both intracellularly and extracellularly. These cells were found positive for S-100 protein

Accepted for publication October 14, 2003.

Dr. Maqbool is from the Department of Surgery, Rawalpindi General Hospital, Pakistan. Drs. Lintner, Bokhari, Habib, Rahman, and Rao are from the Division of Dermatology, University of Medicine and Dentistry, Robert Wood Johnson Medical School, New Brunswick, New Jersey.

The authors report no conflict of interest.

Reprints: Babar Rao, MD, Robert Wood Johnson Medical School, 125 Paterson St, Robert Wood Johnson Medical Center, CAB 2300, New Brunswick, NJ 08901 (e-mail: raoskin@aol.com).

staining. A diagnosis of malignant melanoma of the rectum was made.

Abdominoperineal resection (APR) with pararectal lymphadenectomy was performed. Histopathology results revealed effacement of the lymph node architecture by infiltrating sheets of neoplastic melanocytes within the sinuses. Postoperatively, the patient developed serosanguineous discharge from the perineal wound, which resolved in one week with sitz baths. She was referred to an oncologist for further management, but was non-compliant. A physical examination 4 months later was unremarkable. Ultrasound at that time revealed a 3.0×2.0-cm lymph node along the left iliac vessels. Three months later (7 months postoperative), the patient returned with foul-smelling vaginal discharge. She was found to have a local recurrence and again was referred to the oncology unit for further management. However, the patient was lost to follow-up and died several months later.

Patient 2—A 30-year-old woman presented with a 6-month history of rectal bleeding. Physical examination showed a cauliflower mass in the rectum 3 cm above the dentate line. The rest of the examination was unremarkable. Laboratory data demonstrated a hemoglobin level of 15 g/dL and a serum carcinoembryonic antigen level of 10 ng/mL (reference range, <3.0). The patient's white blood cell count was 5600/μL. Ultrasound revealed a 5.9×5.8-cm mass in the rectum with multiple liver metastases. Results of an incisional biopsy of the mass confirmed the diagnosis of malignant melanoma of the rectum. An excision of the tumor

produced a 5.3×5.3-cm cauliflower mass (Figure 1). Biopsy results of the cauliflower mass showed sheets of round to polyhedral cells with large vesicular nuclei, prominent nucleoli, and brown (melanin) pigment in the cytoplasm (Figure 2). Both lateral margins of the muscularis propria were invaded by the tumor.

The patient was referred for chemotherapy. Seven months after receiving chemotherapeutic treatment, she returned with multiple masses in the rectum and 2 nodules above and below the left clavicle (Figure 3). Further examination confirmed metastatic melanoma. The patient was later lost to follow-up.

Patient 3—A 62-year-old woman presented with a mass protruding from her anus accompanied by intermittent constipation and difficulty sitting for one year (Figure 4). She denied rectal bleeding.



Figure 1. A 5.3×5.3-cm cauliflower mass.

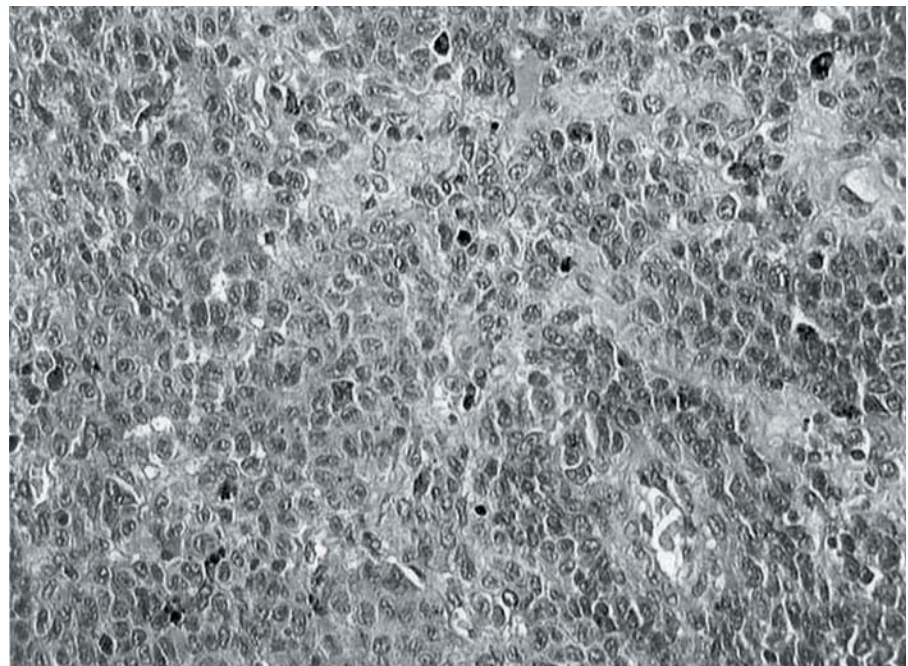


Figure 2. Sheets of round to polyhedral cells with large vesicular nuclei, prominent nucleoli, and brown (melanin) pigment in the cytoplasm (H&E, original magnification ×40).

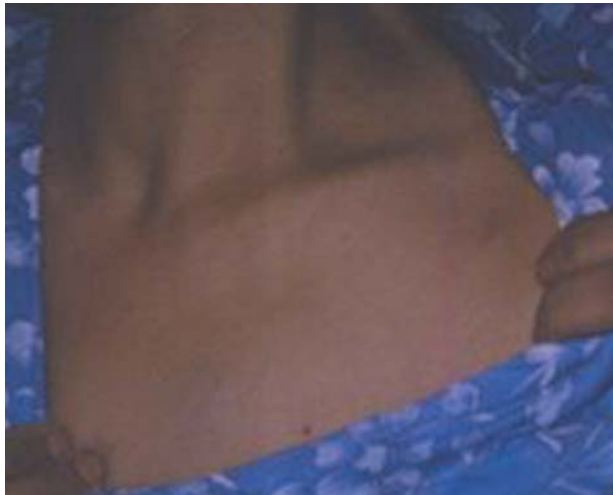

Figure 3. Two nodules above and below the left clavicle.

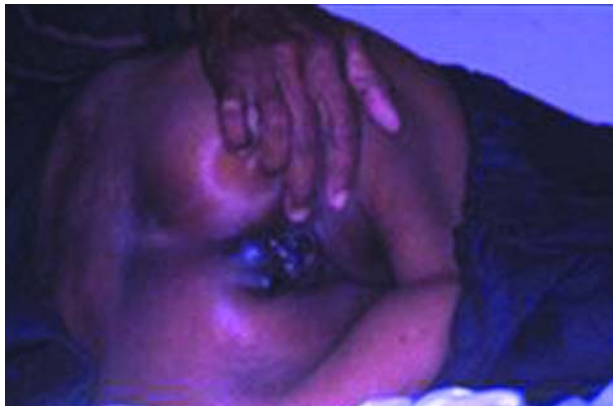

Figure 4. Lesion protruding from the anus.

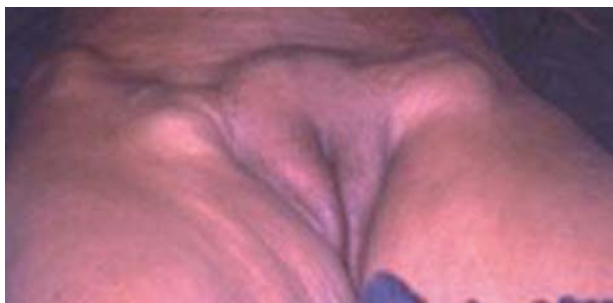

Figure 5. Bilateral enlarged inguinal lymph nodes.

Physical examination revealed bilateral enlarged inguinal lymph nodes, as well as black masses extending around the anal verge and continuing well into the rectum (Figure 5).

Biopsy results from the anal growth and inguinal lymph nodes revealed a black aspirate with clusters of atypical, pleomorphic melanocytes with large, eosinophilic nuclei consistent with malignant

melanoma of the rectum with metastasis to the inguinal lymph nodes. The patient was referred to an oncologist for further treatment and was later lost to follow-up.

Comment

Anorectal melanomas represent less than 3% of all melanomas and less than 1% of all malignant tumors of the anorectum.¹ Although an uncommon cancer, melanoma of the anus is the third most common site for primary melanoma, ranking behind cancer of the skin and eye, respectively. The first case of anorectal melanoma was described by Moore in 1857. The incidence of anorectal melanoma continues to rise, and increasing numbers of cases continue to be reported in the literature.²⁻⁴

Malignant anorectal melanoma arises from the melanocytic cells in the anal mucosa. The tumor often invades the underlying lamina propria, filling it with proliferating melanoma cells. The proliferation of malignant cells often forms a bulky tumor that can project into the anal canal. Because the anus has a rich vascular and lymphatic supply, the tumor is highly aggressive and the disease is often advanced by the time of diagnosis.⁵ The tumor often metastasizes to the lymph nodes. Rectal tumors often metastasize to the pelvic nodes, and anal tumors such as that in patient 3 often metastasize to the inguinal lymph nodes.⁶ The mean survival time has been reported to range from 15 to 25 months.^{4,7,8}

In a review of 117 cases of anorectal melanoma listed in the National Cancer Institute's Surveillance, Epidemiology, and End Results database from 1973 through 1992, Cagir et al⁴ found that the female-to-male incidence ratio of anorectal melanoma was 1:1.72 and the mean age was 66 years. When broken down by gender, the mean age for men was younger (57 years) than for women (71 years). The age difference was found to be significant by statistical analysis.⁴ In a study of the population of Queensland, New Zealand, the incidence rate of anorectal melanoma was found to be 0.028 per 105 people per year.⁸ In the United States, the incidence rate was found to be 0.017 per 105 people per year among the white population. In Northern Pakistan, the incidence rate was found to be 0.010 per 105 people per year.⁸ These studies indicate that the incidence rates are not significantly different ($P=1.00$, Fisher exact test), and illustrate that the incidence rates of anorectal melanoma do not correlate with the incidence rates of cutaneous melanoma, which has one of the highest rates in the world among the Queensland population. This implies that neither skin pigmentation nor sun exposure is causative or protective

for anorectal melanoma,⁸ indicating that there is no clear-cut association between anorectal melanoma and cutaneous melanoma.

The 3 cases presented occurred in Pakistan. Ahmad et al⁹ found that anorectal melanoma diagnosed at the Armed Forces Institute of Pathology, Rawalpindi, constituted 14.2% of all primary malignant melanomas. This rate is much higher than in western countries, which report an occurrence of less than 3%.¹ The same study⁹ also found that the anorectum was the most common site of noncutaneous melanomas (45.8%). This distribution differs from that reported in western countries, where the eye is the most common site of noncutaneous melanomas (59%).¹⁰

Common symptoms of anorectal melanoma, such as rectal bleeding and/or tenesmus, often overlap with those of hemorrhoids.¹¹ Other symptoms include an asymptomatic mass in the anorectal area, a change in bowel habits, and pruritus.¹² Unfamiliarity with rectal lesions, combined with the overlapping of symptoms of the more common diagnosis of hemorrhoids, can lead to delays in both diagnosis and subsequent therapy.¹³

Surgery is the primary treatment option, including local excision, combined local excision and groin lymph node dissection, as well as local tumor destruction by cryosurgery or fulguration. Posterior pelvic exenteration also has been suggested.¹⁵ Prognosis generally is poor due to the advanced stage of disease that is typically found at the time of diagnosis.¹¹ More aggressive surgical procedures with an APR have shown to improve local control and may enhance survival.¹ However, some studies suggest there is no prolongation in survival when excision and APR are performed.¹² Even if survival is not prolonged, it has been shown that APR is better at controlling local and regional disease as well as palliating discomfort associated with large lesions.^{12,14} Chemotherapy, chemoimmunotherapy, or local radiation therapy when used as palliative treatment also may provide further alleviation of symptoms and control tumor growth.⁵ Even with aggressive therapy, a diagnosis of anorectal melanoma bodes a poor prognosis. As a rule, 50% of affected patients have metastatic lesions at the time of initial diagnosis, and 10% have a 5-year survival rate.¹⁵

Debate is ongoing as to the efficacy of sentinel lymph node biopsy in the treatment of melanoma. The current belief is that sentinel lymph node biopsy results allow the identification of early nodal metastases that would not have been detected with clinical staging (palpation) or elective lymph node dissection.¹⁶ Another debatable

treatment is the use of interferon alfa-2b. Interferon alfa-2b is the only US Food and Drug Administration–approved agent for the adjuvant therapy of patients at high-risk for developing a melanoma. Kirkwood et al¹⁷ studied the use of high-dose interferon alfa-2b in the Eastern Cooperative Oncology Group Trial EST1684, which demonstrated a disease-free and better overall survival. However, the E1690 study by Kirkwood et al¹⁸ showed prolongation of a disease-free interval but did not demonstrate a long-term survival benefit. The third study by Kirkwood et al¹⁹ was the E1694. In this randomized study, the control group received a ganglioside vaccine versus high-dose interferon alfa-2b. The study demonstrated an increased disease-free interval and increased overall survival versus the vaccine.¹⁹

In 2001, Dubois et al¹⁶ conducted a formal literature review on the risks and benefits of performing a sentinel lymph node biopsy in patients with stage I or II melanoma and prescribing adjuvant interferon alfa-2b therapy in patients with stage II or III disease. After rating 104 clinical scenarios, the panel concluded that the sentinel lymph node biopsy procedure was suitable for primary melanomas deeper than 1.0 mm and for tumors 1 mm or less, or when histologic ulceration was present and/or classified as Clark's level 4 or higher.¹⁶ Interferon alfa-2b therapy was suitable for patients with regional nodal and/or in-transit metastasis and for node-negative patients with primary melanomas deeper than 4 mm. In patients with ulcerated intermediate primary tumors (2.01–4.0 mm in depth), interferon alfa-2b therapy was deemed uncertain; for node-negative patients with nonulcerated tumors less than 4.0 mm deep, it was deemed inappropriate.¹⁶ At this time, no trials have been published concerning the treatment of mucosal melanoma with new modalities and therapies, such as sentinel lymph node biopsy and high-dose interferon. A prospective multicenter trial would benefit the assessment of these new treatments in a disease that has a very poor outcome despite aggressive surgery and chemotherapy.

Anorectal melanoma remains a difficult cancer to both diagnose and treat. Disease is often advanced at the initial diagnosis as demonstrated by the 3 presented cases. Differing opinions exist as to the ideal treatment of the disease, with no one study suggesting a definitive treatment protocol. The 3 presented cases were advanced at the time of diagnosis, one with distant metastases. Moreover, the patients were noncompliant with the suggested therapies. At this time, based on reports of possible prolonged and enhanced survival for patients with

no evidence of distant metastases, we recommend APR followed by some form of adjuvant therapy together with close follow-up for treatment of anorectal melanoma.²⁰ For patients presenting with distant metastases on initial examination, we recommend palliative treatment with chemotherapy, chemoimmunotherapy, or local radiation therapy.

REFERENCES

- Schuchter LM, Green R, Fraker D. Primary and metastatic diseases in malignant melanoma of the gastrointestinal tract. *Curr Opin Oncol*. 2000;12:181-185.
- Braastad FW, Dockerty MB, Dixon CF. Melano-epithelioma of the anus and rectum. *Surgery*. 1949;25:82-90.
- Dube P, Elias D, Bonvalot S, et al. Primary anorectal melanoma. apropos of 19 cases [in French]. *J Chir*. 1997;134:3-8.
- Cagir B, Whiteford MH, Topham A, et al. Changing epidemiology of anorectal melanoma. *Dis Colon Rectum*. 1999;42:1203-1208.
- Ozguroglu M, Ozaras R, Tahan V, et al. Anorectal melanoma metastatic to the breast. *J Clin Gastroenterol*. 1999;29:197-199.
- Balch C, Houghton A, Sober A, et al, eds. *Mucosal Melanomas in Cutaneous Melanoma*. St. Louis, Mo: Quality Medical Publishing; 1998:195-220.
- Ross M, Pezzi C, Pezzi T, et al. Patterns of failure in anorectal melanoma. a guide to surgical therapy. *Arch Surg (United States)*. 1990;125:313-316.
- Miller BJ, Rutherford LF, McLeod GR, et al. Where the sun never shines: anorectal melanoma. *Aust N Z J Surg*. 1997;67:846-848.
- Ahmad M, Mamoon N, Khan AH. Anorectal melanoma in northern Pakistan. *J Pak Med Assoc*. 1992;42:155-157.
- Chang AE, Karnell LH, Menck HR. The National Cancer Data Base report on cutaneous and noncutaneous melanoma: a summary of 84,836 cases from the past decade. The American College of Surgeons Commission on Cancer and the American Cancer Society. *Cancer*. 1998;83:1664-1678.
- Molino D, Perrotti P, Antropoli C, et al. Primary anorectal melanoma [in Italian]. *Chir Ital*. 2000;52:329-334.
- Slingluff CL, Vollmer RT, Seigler HF. Anorectal melanoma: clinical characteristics and results of surgical management in twenty-four patients. *Surgery*. 1990;107:1-9.
- Felz MW, Winburn GB, Kallab AM, et al. Anal melanoma: an aggressive malignancy masquerading as hemorrhoids. *South Med J*. 2001;94:880-885.
- Thibault C, Sagar P, Nivatvongs S, et al. Anorectal melanoma—an incurable disease? *Dis Colon Rectum*. 1997;40:661-668.
- Rogers RS III, Gibson LE. Mucosal, genital, and unusual clinical variants of melanoma. *Mayo Clin Proc*. 1997;72:362-366.
- Dubois RW, Swetter SM, Atkins M, et al. Developing indications for the use of sentinel lymph node biopsy and adjuvant high-dose interferon alfa-2b in melanoma. *Arch Dermatol*. 2001;137:1217-1224.
- Kirkwood JM, Strawderman MH, Ernstoff MS, et al. Interferon alfa-2b adjuvant therapy of high-risk resected cutaneous melanoma: the Eastern Cooperative Oncology Group Trial EST 1684. *J Clin Oncol*. 1996;14:7-17.
- Kirkwood JM, Ibrahim JG, Sondak VK, et al. High- and low-dose interferon alfa-2b in high-risk melanoma: first analysis of intergroup trial E1690/S9111/C9190. *J Clin Oncol*. 2000;18:2444-2458.
- Kirkwood JM, Ibrahim JG, Sosman JA, et al. High-dose interferon alfa-2b significantly prolongs relapse-free and overall survival compared with the GM2-KLH/qs-21 vaccine in patients with resected stage IIb-III melanoma: results of Intergroup Trial E1694/S9512/C509801. *J Clin Oncol*. 2000;19:2370-2380.
- Brady MS, Kavolius JP, Quan SH. Anorectal melanoma. a 64-year experience at Memorial Sloan-Kettering Cancer Center. *Dis Colon Rectum*. 1995;38:146-151.