

Cutaneous and Pulmonary Sarcoidosis in Association With Tattoos

Maeran Chung Landers, MD, PhD; Michael Skokan, MD; Sandra Law, BS; Frances J. Storrs, MD

Sarcoidosis encompasses a heterogeneous spectrum of clinical presentations, including sarcoidosis in association with tattoos. We report the development of cutaneous and pulmonary sarcoidosis in a patient with long-standing eyebrow tattoos whose cutaneous sarcoidosis almost completely resolved when treated with tacrolimus 0.1% ointment. A 70-year-old woman with a 3-year history of an erythematous eruption circumscribing her eyebrow tattoos presented with a chronic, nonproductive cough of 8 months' duration. Skin biopsy results demonstrated naked tubercles consistent with sarcoidosis. Results of radiographs and a computed tomography scan of the chest revealed multiple pulmonary nodules with mediastinal and hilar adenopathy. The results of transbronchial biopsy were consistent with the diagnosis of pulmonary sarcoidosis. Initial treatment with oral prednisone only improved the pulmonary sarcoidosis. The cutaneous sarcoidosis almost completely resolved after the addition of tacrolimus 0.1% ointment.

Cutis. 2005;75:44-48.

Sarcoidosis is a disease that encompasses an expansive array of clinical presentations.¹ One unusual clinical presentation is that of sarcoidosis in tattoos. Historically, it has been believed that noncaseating granulomas may be a foreign body reaction to materials such as talc, titanium, and lead carbonate, which are often found in tattoos. Tattoos also can result in allergic granulomas caused by zirconium or beryllium. Red pigments, specifically mercuric sulfide, are the most common source of tattoo-related allergic reactions. Rarely,

Accepted for publication May 4, 2004.

Drs. Landers and Storrs and Ms. Law are from the Department of Dermatology, Oregon Health & Science University, Portland. Dr. Skokan is from the Pulmonary Division, Oregon Clinic, Portland. The authors report no conflict of interest.

Reprints: Frances J. Storrs, MD, Department of Dermatology, Oregon Health & Science University, 3181 SW Sam Jackson Park Rd, OP 06, Portland, OR 97239 (e-mail: storrsf@ohsu.edu).




Figure 1. Erythematous brown plaques with rolled borders and slightly atrophic centers circumscribing eyebrow tattoos.

tattoo-associated cutaneous sarcoidosis has been associated with the development of systemic sarcoidosis. We report the development of cutaneous and pulmonary sarcoidosis in a patient with long-standing eyebrow tattoos.

Case Report

A 70-year-old woman presented with a 3-year history of an asymptomatic, erythematous, somewhat scaly eruption circumscribing eyebrow tattoos that had been applied 25 years earlier. In 1999, the patient had noticed a small, slowly enlarging erythematous plaque adjacent to her left eyebrow tattoo. Several months later, the patient noted a similar erythematous plaque adjacent to her right eyebrow tattoo. The eruptions eventually completely circumscribed both eyebrow tattoos (Figure 1). The patient had been concealing the eruption with makeup for 3 years. The patient had used hydrocortisone 1% cream for several months without improvement. She had no prior history of skin disease.

The patient also reported a mild cough that had lasted 8 months. The dry nonproductive cough was

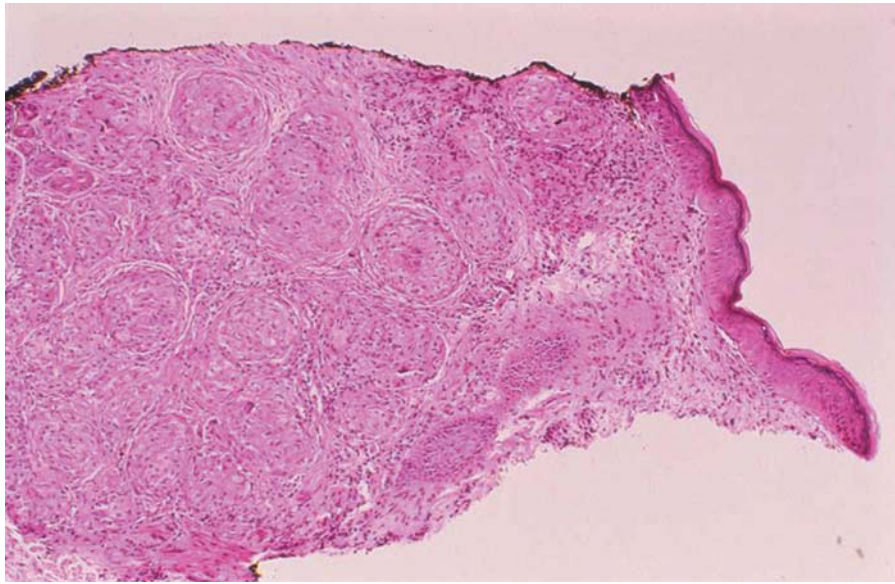


Figure 2. Skin biopsy specimen showing features of sarcoidosis with noncaseating granulomas and large, pale-staining, epithelioid histiocytes (H&E, original magnification $\times 25$).

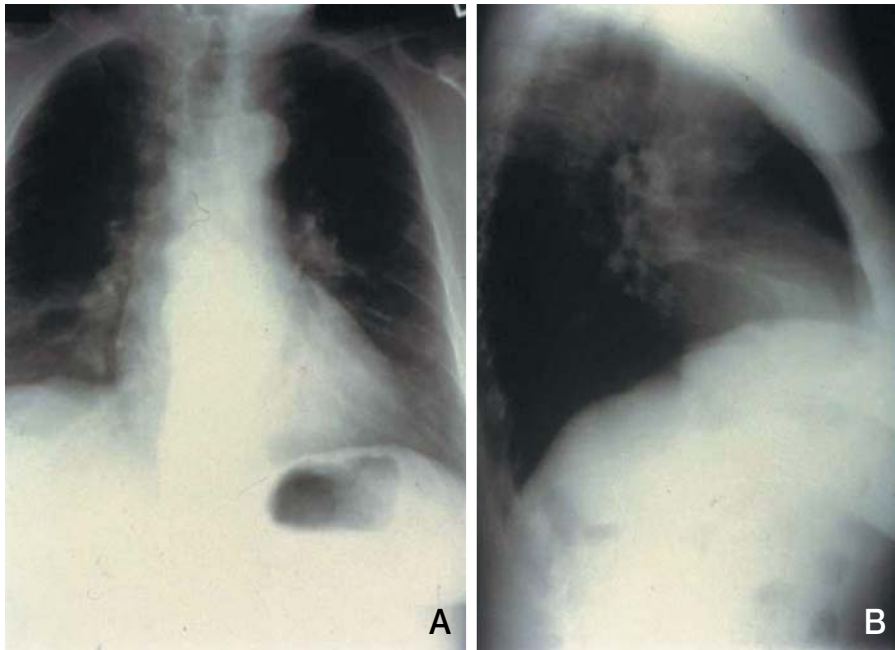


Figure 3. Results of postero-anterior (A) and lateral (B) chest radiographs reveal multiple pulmonary nodules, bilateral hilar enlargement, and no pleural effusion.

persistent and occurred daily without any triggering or exacerbating factors. There was no significant medical or surgical history of dyspnea, hemoptysis, postnasal drip, or gastroesophageal reflux disease. She denied smoking and occupational exposures to asbestos. The patient had no constitutional symptoms such as fevers, chills, weight loss, or fatigue. She reported taking no medications and having no known allergies.

The findings of the visual cutaneous examination included nonscaly, erythematous brown plaques with rolled borders surrounding the eyebrow tattoos bilaterally. The centers of the

plaques were slightly atrophic. No other abnormal findings were noted. Skin biopsy results revealed noncaseating granulomas with large, pale-staining, epithelioid histiocytes (Figure 2). Results of acid-fast bacillus and Gomori methenamine-silver staining procedures were negative for organisms. There was no evidence of foreign body material on examination under polarizing light. The histopathologic differential diagnosis included sarcoidosis, foreign body reaction, and allergic granulomas.

Imaging studies, including posteroanterior and lateral chest radiographs (Figure 3) and computed tomography scan of the chest, were performed.

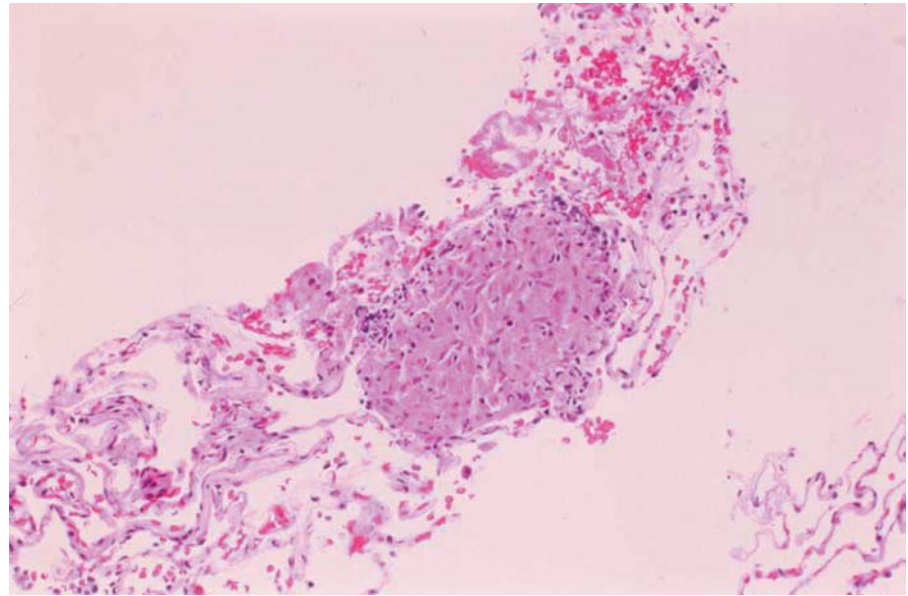


Figure 4. Transbronchial lung biopsy specimen showing features of sarcoidosis with noncaseating granulomas (H&E, original magnification $\times 50$).

The chest radiographs revealed multiple nondiscrete nodules, 4 in the right lung field and 3 in the left lung field. No pleural effusion was seen. The hila were enlarged, and the radiographic appearance suggested mediastinal adenopathy. The computed tomography scan of the chest with contrast revealed multiple, noncalcified, parenchymal nodules. The nodules were peripherally located, with 5 in the right lung and 6 in the left lung. Hilar and mediastinal adenopathy also was noted. Results of a transbronchial lung biopsy demonstrated noncaseating granulomas consistent with the diagnosis of sarcoidosis (Figure 4). Results of special staining procedures were negative for acid-fast bacilli and fungi. There was no evidence of pigment or foreign material in the granulomas. Results of laboratory studies, including complete blood count, chemistry panel, and liver and renal function tests, were all within reference range, as were the results of pulmonary function tests.

The patient was treated with oral prednisone 20 mg/d for pulmonary sarcoidosis. Four weeks after starting prednisone, her nonproductive cough had improved. A repeat computed tomography scan of the chest performed 3 months after the initiation of prednisone therapy showed a reduction in the size of the pulmonary nodules. At 3 months, the dose of prednisone was reduced to 10 mg/d for maintenance. The patient had discontinued the hydrocortisone 1% cream, and the oral prednisone did not significantly improve the cutaneous manifestations. Therefore, in addition to prednisone 10 mg/d for the pulmonary sarcoidosis, the patient was prescribed tacrolimus 0.1% ointment to be applied twice a day




Figure 5. Nearly complete clinical clearing of erythematous brown plaques circumscribing the eyebrow tattoos after 6 months of treatment with tacrolimus 0.1% ointment applied twice a day.

to the eyebrows.² After 6 months of treatment with tacrolimus 0.1% ointment, clinical clearing was nearly complete (Figure 5). Results of a subsequent biopsy of the eyebrows demonstrated sparse sarcoidal tubercles and scarring alopecia (Figure 6). The patient was prescribed maintenance treatment with tacrolimus 0.1% ointment only.

Comment

Sarcoidosis comprises a spectrum of clinical presentations including papular, annular, hypopigmented, ulcerative, verrucous, and subcutaneous,

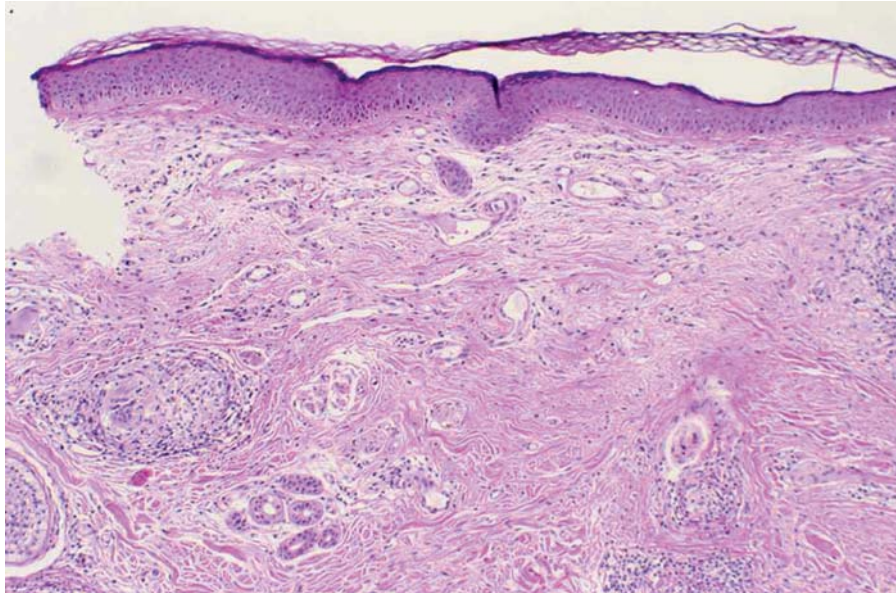


Figure 6. Skin biopsy specimen showing features of sarcoidosis with sparse non-caseating granulomas and scarring alopecia (H&E, original magnification $\times 25$).

as well as lupus pernio and scar manifestations.¹ We present this case report of pulmonary and cutaneous sarcoidosis associated with tattoos because of its unique clinical presentation.

The relationship of tattoo-related sarcoidosis to the development of systemic sarcoidosis is difficult to resolve. Cutaneous sarcoidosis may be seen in relation to scarring processes, and tattoos may be considered to be scar-inducing conditions. Sarcoidosis in tattoos is thought to be a variant of scar sarcoidosis due to the Köbner phenomenon. Scar sarcoidosis is most frequently seen in patients with chronic systemic sarcoidosis. The development of both scar- and tattoo-associated sarcoidosis simultaneously with pulmonary sarcoidosis in one patient supported the hypothesis that granulomas in long-standing tattoos may be a manifestation of the Köbner phenomenon in the setting of systemic sarcoidosis.³

Cutaneous and systemic sarcoidosis have been reported in the context of tattoos in a number of case reports.³⁻¹¹ Careful evaluation to rule out systemic sarcoidosis is therefore essential and should include complete history, physical examination, review of systems, blood tests, chest radiograph, and, if appropriate, ophthalmologic examination. Abnormal chest imaging results should be followed up with pulmonary function testing. The most common manifestation of systemic sarcoidosis associated with tattoos has been pulmonary sarcoidosis; however, there also have been reports of erythema nodosum,⁵ arthritis,⁵ and uveitis.¹²

The first case of tattoo-associated sarcoidosis was reported in 1939.¹³ The patient had no evidence of

systemic sarcoidosis, but results of a patch test were positive for mercury. Similar allergic reactions to green¹⁴ and red¹⁵ tattoo pigments have been reported. These cases are thought to represent sarcoidosislike histology and allergic hypersensitivity reactions to tattoo pigments. In contrast, cutaneous sarcoidosis has been reported in the context of blue,⁴ red,^{5,7,11} and black⁶ tattoo pigments in the setting of systemic sarcoidosis. A case report found the presence of red tattoo pigment in both cutaneous and lung granulomas,⁷ suggesting that a particular tattoo pigment may have been responsible for the development of systemic sarcoidosis.

The latency period between the placement of the tattoo and the development of cutaneous or systemic sarcoidosis is variable. In this case, there was a 25-year interval between the placement of the eyebrow tattoos and the diagnosis of cutaneous and pulmonary sarcoidosis. Previous case reports have described latency periods of 1 year,⁷ 10 years,⁴ 12 years,⁹ 15 years,^{3,5,6} 25 years,¹¹ and 45 years.⁸ The wide spectrum of time from tattoo placement to the diagnosis of sarcoidosis highlights the complexity of this association and a possible altered reactivity of the patient to tattoos.

In our patient, the eyebrow tattoos had been placed 25 years earlier. Originally brown, brown-black, or black, the tattoos are currently black. Brown tattoo pigments generally comprise inorganic iron oxides with combinations of red and yellow oxides. Black tattoo pigments are composed of either iron oxide or carbon-based black. Tattoo pigments are suspended in hydrating fluids. Twenty-five years ago, the gold standard of hydrating fluids

was Listerine® Antiseptic. Today, hydrating fluids may include ethanol, isopropyl alcohol, witch hazel, rose water, glycerol, propylene glycol, distilled water, synthetic gelatins, dexpanthenol, and other healing extracts (M. J. Haake, oral communication, August 9, 2002). Because the patient was unable to locate the tattoo artist, she could not ascertain the precise composition of her eyebrow tattoos.

Foreign bodies in granulomatous cutaneous lesions have been reported in patients with systemic sarcoidosis.¹⁶ In 22% of patients with granulomatous cutaneous involvement, examination of the lesions under polarized light demonstrated the presence of foreign particles. Three different clinical forms of cutaneous sarcoidosis with foreign material were observed, including papular sarcoidosis on the knees, scar sarcoidosis, and subcutaneous sarcoidosis. The papular and scar sarcoidosis were associated with Lofgren syndrome. In the tattoo process, talc has often been used to enhance tattoo color. The presence of foreign material in our patient's tattoos was not seen on examination under polarized light. Energy-dispersive x-ray spectroscopy was not performed to investigate the distinct components of the tattoo pigment and the presence of foreign material.

The primary treatment of cutaneous and pulmonary sarcoidosis in the setting of tattoos has been prednisone. In one previous case report of tattoo-associated sarcoidosis with pulmonary involvement, the cutaneous eruption resolved with oral steroid therapy.^{4,5} Our patient was treated with prednisone 20 mg/d for 3 months and then with prednisone 10 mg/d for maintenance. Despite no initial improvement with prednisone 20 mg/d for 3 months, clinical improvement was noted after 6 months of therapy with prednisone 10 mg/d and tacrolimus 0.1% ointment twice a day. Previous case reports demonstrated complete resolution of cutaneous and pulmonary sarcoidosis at 4 months with prednisolone 15 mg/d⁴ and at one year with prednisolone 40 mg/d.⁵

This case illustrates the concomitant development of cutaneous and systemic sarcoidosis in a patient with 25-year-old eyebrow tattoos. Owing to the increasing prevalence of tattoos for both decorative and cosmetic purposes, we anticipate that dermatologists will face more patients with this unusual constellation of clinical findings. A full medical evaluation for systemic sarcoidosis should be

performed in patients who present with tattoo-associated cutaneous sarcoidosis. The relationship between tattoos and cutaneous sarcoidosis is still unclear; however, it may comprise scar with Köbner phenomenon, foreign body granulomatous reactions, or both. Treatment with prednisone and tacrolimus 0.1% ointment can be effective in these patients.

REFERENCES

1. English JC III, Patel PJ, Greer KE. Sarcoidosis. *J Am Acad Dermatol.* 2001;44:725-743.
2. Katoh N, Mihara H, Yasuno H. Cutaneous sarcoidosis successfully treated with topical tacrolimus. *Br J Dermatol.* 2002;147:154-156.
3. Murdoch SR, Fenton DA. Sarcoidosis presenting as nodules in both tattoos and scars. *Clin Exp Dermatol.* 1997;22:254-255.
4. Collins P, Evans AT, Gray W, et al. Pulmonary sarcoidosis presenting as a granulomatous tattoo reaction. *Br J Dermatol.* 1994;130:658-662.
5. Sowden JM, Cartwright PH, Smith AG, et al. Sarcoidosis presenting with a granulomatous reaction confined to red tattoos. *Clin Exp Dermatol.* 1992;17:446-448.
6. Jones MS, Maloney ME, Helm KF. Systemic sarcoidosis presenting in the black dye of a tattoo. *Cutis.* 1997;59:113-115.
7. Hanada K, Chiyoya S, Katabira Y. Systemic sarcoid reaction to tattoo. *Clin Exp Dermatol.* 1985;10:479-484.
8. Weidman AI, Andrade R, Franks AG. Sarcoidosis: report of a case of sarcoid lesions in a tattoo and subsequent discovery of pulmonary sarcoidosis. *Arch Dermatol.* 1966;94:320-325.
9. Kennedy C. Sarcoidosis presenting in tattoos. *Clin Exp Dermatol.* 1976;1:395-399.
10. Dickinson JA. Sarcoid reactions in tattoos. *Arch Dermatol.* 1969;100:315-319.
11. Blobstein SH, Weiss HD, Myskowski PL. Sarcoid granulomas in tattoos. *Cutis.* 1985;36:423-424.
12. Rorsman H, Brehmer-Andersson E, Dahlquist I, et al. Tattoo granuloma and uveitis. *Lancet.* 1969;2:27-28.
13. Madden JF. Reactions in tattoos. *Arch Dermatol.* 1939;40:256-262.
14. Lowenthal LJA. Reactions in green tattoos. *Arch Dermatol.* 1960;82:237-243.
15. Goldstein N. Mercury-cadmium sensitivity in tattoos: a photoallergic reaction in red pigment. *Ann Intern Med.* 1967;67:984-989.
16. Marcoval J, Mana J, Moreno A, et al. Foreign bodies in granulomatous cutaneous lesions of patients with systemic sarcoidosis. *Arch Dermatol.* 2001;137:427-430.