

Hydroquinone 4%, Tretinoin 0.05%, Fluocinolone Acetonide 0.01%: A Safe and Efficacious 12-Month Treatment for Melasma

Helen Mary Torok, MD; Terry Jones, MD; Phoebe Rich, MD; Stacy Smith, MD; Eduardo Tschen, MD

This article describes a long-term, multicenter, open-label, 12-month study of once-daily fluocinolone acetonide 0.01%, hydroquinone 4%, tretinoin 0.05% (Tri-Luma® Cream, hereinafter called TC [triple combination]) application in the treatment of melasma. A total of 228 patients with facial melasma were enrolled and treated; 173 patients (76%) completed the study. Most patients had 1 to 2 courses of treatment lasting approximately 6 months in total.

TC cream showed a favorable safety profile: only 3 patients (1%) withdrew from the study due to treatment-related adverse events (AEs). A total of 129 patients (57%) experienced at least one treatment-related AE. Most AEs were expected application-site reactions that were mild and transient in nature and did not require remedial therapy. There were no cases of skin atrophy or skin thinning and only 6 cases of

telangiectasia (5 mild and 1 moderate), most of which had improved by the end of the study. Results of the efficacy assessments were positive, with both the patient and the physician assessing melasma to be either completely or nearly cleared by the end of the study in more than 90% of cases. In this study, a once-daily application of TC cream over an extended period of 12 months showed no notable safety concerns and offered an effective treatment for melasma.

Cutis. 2005;75:57-62.

Melasma (also known as *chloasma* or *mask of pregnancy*) is an acquired, often symmetrical hyperpigmentation characterized by light to dark brown patches on sun-exposed areas, predominantly on the face (lower cheeks, upper lips, nose, and chin). This chronic condition can be recurrent and may cause considerable embarrassment and emotional distress in patients who are affected.¹⁻³

Although the true incidence of melasma is unknown, it is a very common occurrence. Almost 90% of affected patients are women. It commonly occurs in women who are pregnant or using oral contraceptives or hormone replacement therapy; also, it can often be seen in women without a predisposing factor. The disease may affect any racial group or skin type but is more commonly found in darker skinned individuals, such as Hispanics, Asians, or other racial groups.⁴⁻⁶

The etiology of melasma is poorly understood. Factors involved in the pathogenesis include genetic

Accepted for publication April 21, 2004.

Dr. Torok is from HMT Dermatology Associates, Inc, Medina, Ohio.

Dr. Jones is from J&S Studies, Bryan, Texas. Dr. Rich is from Northwest Cutaneous Research Specialists, Portland, Oregon.

Dr. Smith is from Therapeutics, Inc, La Jolla, California.

Dr. Tschen is from Academic Dermatology Associates, Albuquerque, New Mexico.

The clinical study was supported by Hill Pharmaceuticals.

Dr. Torok is a consultant and advisory board member for Galderma Pharmaceuticals. Dr. Smith is on the speakers bureau for Galderma Pharmaceuticals. Drs. Jones, Rich, and Tschen report no conflict of interest.

Reprints: Helen M. Torok, MD, Trilium Creek Dermatology Center, 5783 Wooster Pike Rd, Medina, OH 44256 (e-mail: helenmtorok@aol.com).

influences, exposure to UV radiation, pregnancy, and hormone therapy. Other implicated factors include the use of certain cosmetics, phototoxic drugs, and anticonvulsant medications.¹ The treatment of melasma remains a challenge, even if key treatment elements are followed (eg, use of sunblocks, avoidance of the sun).⁷⁻⁸

Hydroquinone (HQ) is the most commonly used treatment for melasma but has a relatively low efficacy as monotherapy, and recurrences are common. HQ is a hydroxyphenol that is thought to work by blocking the synthesis of melanin via the inhibition of tyrosinase.⁹⁻¹¹ This compound has been used for more than 30 years and is considered the gold standard. Various clinical studies have shown the usefulness of HQ for lightening skin in patients with melasma.^{7,12-14} HQ is commercially available in concentrations from 2% to 5%; higher concentrations are typically more irritating, with only modest increases in efficacy.^{2,12,15} Although improvement in melasma can be seen after just 8 to 12 weeks of therapy with HQ, maximal efficacy may not be seen for many months.⁷ In addition, HQ is an unstable compound that quickly loses its efficacy if antioxidants are not added to the preparation. Hence, combination treatments containing HQ are difficult to prepare.

Tretinoin, a topical retinoic acid, also has been shown to be effective in the treatment of melasma.^{16,17} It is widely believed to work by stimulating cell turnover, thus promoting the rapid loss of pigment via epidermopoiesis.¹⁸ In addition, it may have an inhibitory effect on tyrosinase. When used alone, tretinoin tends to be effective but may require 6 months of treatment or longer.¹⁶ As a result, tretinoin is commonly combined with one or more other agents to accelerate the beneficial effect. Tretinoin also has the potential to induce DNA synthesis of epidermal and dermal cells. This is thought to be helpful in counteracting the atrophogenic effects of topical steroids by increasing skin thickness.¹⁹

In 1975, Kligman and Willis²⁰ published impressive studies using topical combination therapy for depigmenting human skin, consisting of HQ 5%, tretinoin 0.1%, and dexamethasone 0.1%, a topical corticosteroid. Following these findings, articles were published proposing various other combination therapies for melasma.^{2,12,21,22} These combinations always included HQ and tretinoin and also generally included a corticosteroid. Other corticosteroids were tried, including hydrocortisone and betamethasone^{2,21,22}; it is thought that they may inhibit melanin synthesis through a depression of the general activity of the cell. Moreover, corticosteroids

may reduce the irritation or inflammation caused by HQ and tretinoin.²

Recently, a stable fixed combination therapy was developed containing fluocinolone acetonide (FA), a low-potency (group VI) corticosteroid.²³ The formula of this triple-combination (TC) therapy consists of FA 0.01%, HQ 4%, tretinoin 0.05% (Tri-Luma[®] Cream). This combination has been shown to be safe and effective in the treatment of melasma for up to 8 weeks.²³

Some authors have expressed concern regarding the risk for skin atrophy and telangiectasia after long-term topical administration of corticosteroids.²¹ This risk may be reduced in combination therapy because it has been shown that tretinoin prevents corticosteroid-induced atrophy without lessening the anti-inflammatory effect.^{22,24} To answer those concerns and because melasma is a long-term recurring disease, a 12-month multicenter study was conducted to confirm the safety and efficacy of TC in the treatment of melasma.

Methods

The study was conducted in accordance with the principles of the Declaration of Helsinki and its amendments, and in compliance with regulatory requirements. Patients provided written informed consent before study procedures.

Patients—To be included in the study, patients of either gender had to be at least 18 years of age and have melasma. Patients were excluded if they had facial skin conditions that may have interfered with study objectives or evaluations, were immunocompromised or under immunosuppressive treatment, or had contraindications for corticosteroid treatment. Patients also were excluded if they had exposure to the sun on a regular basis, had consistent irritation of the exposed skin, or both.

Women of childbearing potential had to use effective methods of birth control during treatment, with a negative urine pregnancy test result at initiation and completion of each treatment period.

Methods—After washing, patients applied the TC cream once daily approximately 30 minutes before bedtime. A sunscreen with a sun protection factor of 30 and both UVA and UVB protection was provided for daily use. Protective clothing and avoidance of sun exposure to the face was recommended; cosmetics and mild moisturizer were allowed.

Patients were evaluated on a monthly basis until there was a satisfactory resolution of their melasma (severity score of 0 or 1), at which time point the treatment was stopped, but sunscreen use was continued. Then, patients were followed up every 2 months while off treatment. If the melasma

Patient Demographics

Characteristic	N=228
Mean age, y (SD)	45.1 (9.2)
Gender, n (%)	
Male	6 (3)
Female	222 (97)
Race, n (%)	
White	148 (65)
Black	16 (7)
Asian	12 (5)
Other	52 (23)
Skin phototype, n (%)	
I	28 (12)
II	72 (32)
III	64 (28)
IV	64 (28)
V	0

worsened as confirmed by physician evaluation, patients were re-treated with TC cream for 8 weeks. Thus, each patient may have received several courses of treatment during the 12-month study.

Safety—Safety was assessed throughout the study by adverse event (AE) reporting and laboratory test results. Anticipated skin changes, including erythema, skin peeling, burning, or stinging, were specifically solicited by the investigator at each visit. In addition, patients were examined at each visit, with special attention given to the presence of telangiectasia, rosacea, dermatitis, atrophy, or worsening pigmentation. A complete blood cell count, serum chemistries, and urinalysis were performed at selected sites each time treatment was initiated and completed.

Efficacy—To assess efficacy, the degree of pigmentation of the target melasma lesion was scored at each visit by the investigator using the following scale: 0=melasma lesion approximately equivalent to surrounding normal skin or with minimal residual hyperpigmentation, 1=mild (slightly darker than the surrounding normal skin), 2=moderate (moderately darker than the surrounding normal skin), and 3=severe (markedly darker than the surrounding normal skin).

An investigator static global assessment of melasma was performed at each treatment visit using the following scale: 0=completely cleared, no evidence of hyperpigmentation; 1=nearly cleared, only minor visual evidence of hyperpigmentation; and 2=significant evidence of hyperpigmentation.

A patient static global assessment of melasma, which included an assessment of all treated areas, was performed at each treatment visit as follows: 1=completely cleared, 2=nearly cleared, and 3=significant hyperpigmentation present.

Statistics—Regression analyses and longitudinal analyses were used to examine long-term safety and selected efficacy evaluations. All patients who received the study drug were included in the analyses (intent-to-treat population).

Results

Patients—A total of 228 patients were enrolled, and 173 patients (76%) completed the study. The

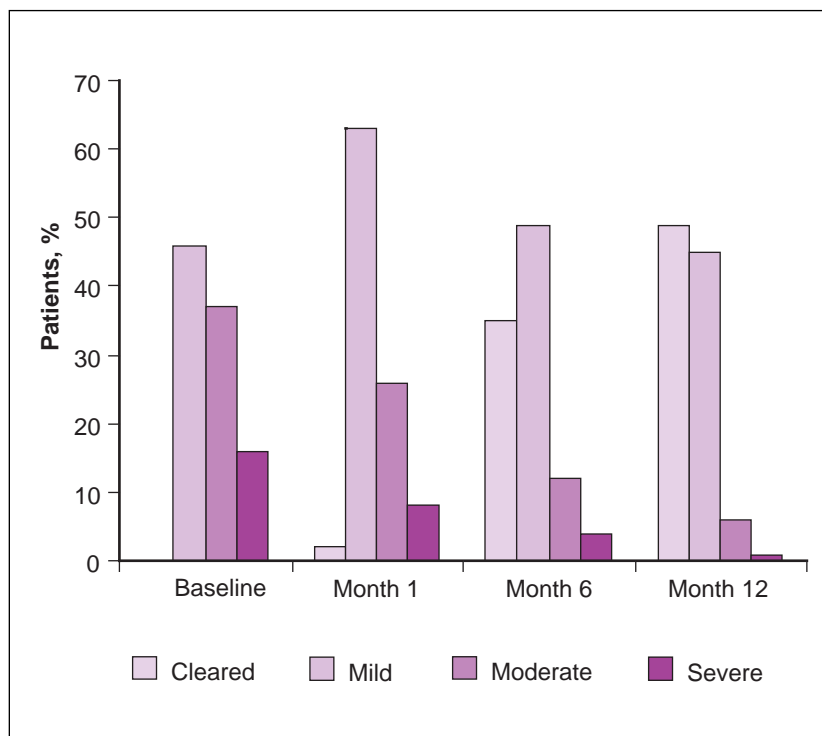


Figure 1. Degree of pigmentation of the target melasma lesion.

most common reasons for discontinuation were loss to follow-up and patient request. Patient demographics are detailed in the Table.

Most patients (174 [76%]) had only 1 or 2 courses of treatment, lasting between 173 to 177 days. Both the duration of each course and the interval between courses decreased in those patients requiring more than 2 courses of therapy.

Safety—One hundred twenty-nine (57%) patients experienced treatment-related AEs. The most frequently reported AEs were application-site desquamation and application-site erythema, both occurring in approximately one third of patients. Most of these treatment-related AEs were mild and transient, did not require remedial therapy, and did not result in withdrawal from the study. The incidence of application-site AEs tended to increase as the number of courses of treatment increased and as the days of TC treatment increased. This trend continued up to approximately 6 months of treatment, after which time, the number of AEs stabilized.

Treatment-related AEs tended to have a lower incidence in black patients and in patients with skin phototype IV.

No cases of skin atrophy or skin thinning, rosacea, or hypopigmentation were reported throughout the study. Incidences of other anticipated AEs were as follows: acne/acne break outs occurred in 23 patients (10%), perioral dermatitis in 2 patients (1%), hyperpigmentation in 11 patients (5%), and facial telangiectasia in 6 patients (3%). All cases of telangiectasia were limited to treatment areas and probably related to treatment with the TC cream. Five of the cases of telangiectasia were mild, and 1 was moderate. In 4 cases, telangiectasia had resolved or improved by the end of the study; 2 cases (both mild) were

unchanged at the end of the study. All but one case (having occurred after 195 days of treatment) were reported during the first treatment period.

Overall, the TC cream was well tolerated by patients, and only 6 patients (3%) had AEs leading to the discontinuation of treatment. Three of these

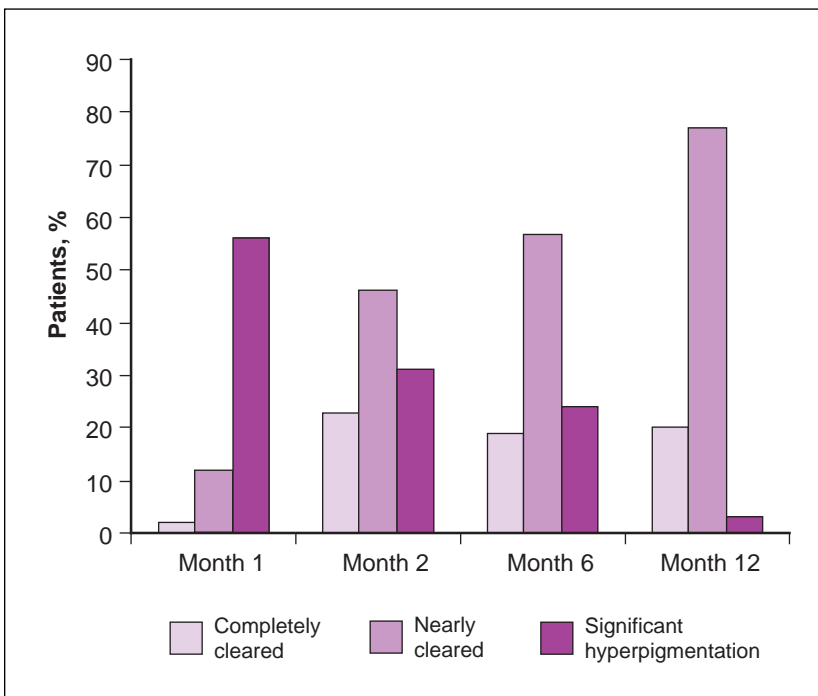


Figure 2. Investigator static global assessment of melasma.

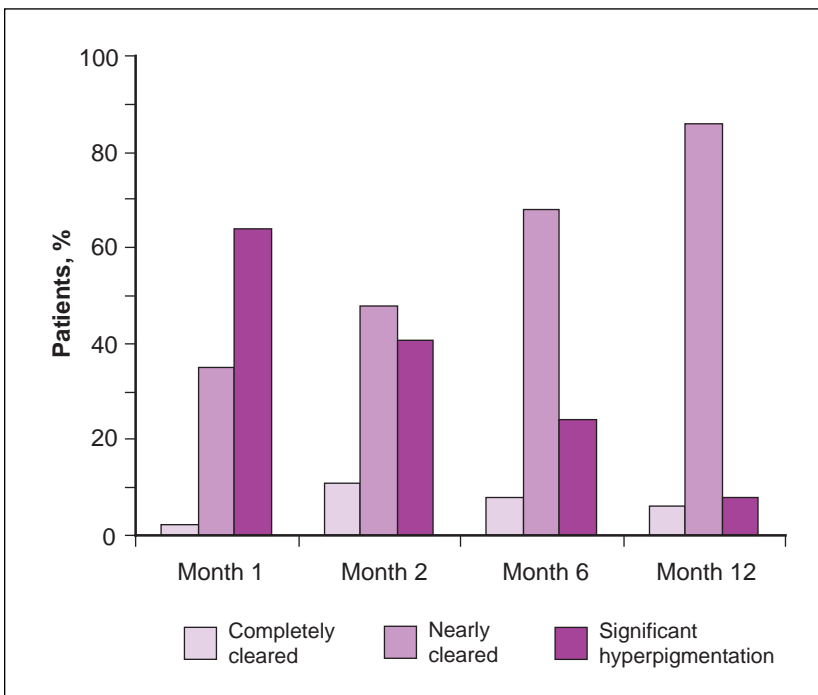


Figure 3. Patient static global assessment of melasma.

AEs were considered possibly related to study drug (irregular menstrual periods, peeling of the face, and hyperpigmentation), and 3 AEs were considered unlikely to be related to study drug (breast lump in 1 case and pregnancy in 2 cases).

TC cream was not associated with any serious AEs or laboratory changes.

The physician assessment of melasma severity showed that most of the patients in the study had mild (46.5%) or moderate (37.3%) melasma at baseline, while only a small proportion (16.2%) were graded as severe. Figure 1 shows the changes in proportion of patients in each severity class over time. At 6 months, 84% of patients were either cleared or had mild lesions. By 12-months, the proportion of patients in these severity classes reached 94%.

The physician static global assessment of melasma showed similar results, with 76% of patients completely or nearly cleared of lesions at 6 months, increasing to 97% by month 12 (Figure 2).

Results of the patient static global assessment paralleled the findings of the physician static global assessment. Overall, patients viewed their treatment as a success; 92.3% of patients had completely or nearly cleared lesions by month 12 (Figure 3).

Comment

TC cream showed a favorable safety profile in this study. On average, patients were exposed to more than 5 months of therapy. A total of 129 patients (57%) experienced at least one treatment-related AE during this study, yet most of these were mild application-site reactions, such as desquamation, erythema, and dryness, which might be expected from a treatment containing tretinoin and HQ. Only 3 patients (1%) withdrew from the study because of treatment-related AEs.

Some authors have expressed concern regarding the risk for skin atrophy and telangiectasia after long-term topical administration of corticosteroids.²⁵ No cases of skin atrophy or skin thinning were detected in the present study. This may be due to the presence of tretinoin, which has been shown to prevent corticosteroid-induced atrophy without lessening the anti-inflammatory effect.^{23,26} Six cases of telangiectasia (3%) were reported, with only 2 remaining at the conclusion of the study.

This modest number of AEs is weighed against the increased efficacy seen with long-term therapy. By all 3 measures of efficacy, physician assessment of melasma severity, physician static global assessment of melasma, and patient static global assessment, the additional months of therapy yielded substantial increases in improvement of melasma.

In conclusion, TC cream applied once daily and used with concomitant sun protective measures was a safe and effective long-term treatment for melasma.

Acknowledgments—The authors would like to thank Helen Baldwin and Patrick Göritz at Galderma Laboratories for their assistance in writing this publication.

REFERENCES

1. Grimes PE. Melasma: etiologic and therapeutic considerations. *Arch Dermatol.* 1995;131:1453-1457.
2. Katsambas A, Antoniou C. Melasma: classification and treatment. *J Eur Acad Dermatol Venereol.* 1995;4:217-223.
3. Sanchez NP, Pathak MA, Sato S, et al. Melasma: a clinical, light microscopic, ultrastructural, and immunofluorescence study. *J Am Acad Dermatol.* 1981;4:698-710.
4. Taylor SC. Epidemiology of skin diseases in people of color. *Cutis.* 2003;71:271-275.
5. Vasquez M, Maldonado H, Benmaman C, et al. Melasma in men. *Int J Dermatol.* 1988;27:25-27.
6. Halder RM, Nootheti PK. Ethnic skin disorders overview. *J Am Acad Dermatol.* 2003;48:S143-S148.
7. Sanchez JL, Vazquez M. A hydroquinone solution in the treatment of melasma. *Int J Dermatol.* 1982;20:55-58.
8. Vazquez M, Sanchez JL. The efficacy of a broad-spectrum sunscreen in the treatment of melasma. *Cutis.* 1983;32:92, 95-96.
9. Denton CR, Lerner AB, Fitzpatrick TB. Inhibition of melanin formation by chemical agents. *J Invest Dermatol.* 1952;18:119-135.
10. Jimbow K, Obata H, Pathak MA, et al. Mechanism of depigmentation by hydroquinone. *J Invest Dermatol.* 1974;62:436-449.
11. Penney KB, Smith CJ, Allen JC. Depigmenting action of hydroquinone depends on disruption of fundamental cell processes. *J Invest Dermatol.* 1984;82:308-310.
12. Pathak MA, Fitzpatrick TB, Kraus EW. Usefulness of retinoic acid in the treatment of melasma. *J Am Acad Dermatol.* 1986;15:894-899.
13. Pathak MA, Fitzpatrick TB, Paresch JA. Treatment of melasma with hydroquinone. *J Invest Dermatol.* 1993;76:324-329.
14. Haddad AL, Matos LF, Brunstein F, et al. A clinical, prospective, randomized, double-blind trial comparing skin whitening complex with hydroquinone vs. placebo in the treatment of melasma. *Int J Dermatol.* 2003;42:153-156.
15. Engasser PG, Maibach HJ. Cosmetics and dermatology: bleaching creams. *J Am Acad Dermatol.* 1981;5:143-147.
16. Griffiths CE, Finkel LJ, Ditre CM, et al. Topical tretinoin (retinoic acid) improves melasma. a vehicle-controlled, clinical trial. *Br J Dermatol.* 1993;129:415-421.
17. Kimbrough-Green CK, Griffiths CE, Finkel LJ, et al. Topical retinoic acid (tretinoin) for melasma in black

- patients. a vehicle-controlled clinical trial. *Arch Dermatol*. 1994;130:727-733.
18. Craven NM, Griffiths CE. Topical retinoids and cutaneous biology. *Clin Exp Dermatol*. 1996;21:1-10.
 19. McMichael AJ, Griffiths CE, Talwar HS, et al. Concurrent application of tretinoin (retinoic acid) partially protects against corticosteroid-induced epidermal atrophy. *Br J Dermatol*. 1996;135:60-64.
 20. Kligman AM, Willis I. A new formula for depigmenting human skin. *Arch Dermatol*. 1975;111:40-48.
 21. Gano SE, Garcia RL. Topical tretinoin, hydroquinone, and betamethasone valerate in the therapy of melasma. *Cutis*. 1979;23:239-241.
 22. Kang WH, Chun SC, Lee S. Intermittent therapy for melasma in Asian patients with combined topical agents (retinoic acid, hydroquinone and hydrocortisone): clinical and histological studies. *J Dermatol*. 1998;25:587-596.
 23. Taylor SC, Torok H, Jones T, et al. Efficacy and safety of a new triple-combination agent for the treatment of facial melasma. *Cutis*. 2003;72:67-72.
 24. Berardesca E, Maibach H. Ethnic skin: overview of structure and function. *J Am Acad Dermatol*. 2003;48 (suppl 6):S139-S142.
 25. Giannotti B, Melli MC. Current approaches to the treatment of melasma. *Clin Drug Invest*. 1995;10:57-64.
 26. Kligman LH, Schwartz E, Lesnik RH, et al. Topical tretinoin prevents corticosteroid-induced atrophy without lessening the anti-inflammatory effect. *Curr Probl Dermatol*. 1993;21:79-88.