

Eruptive Syringomas: An Unusual Presentation on the Buttocks

Charles L. Powell, MD; CDR Eric P. Smith, MC, USNR; Bradley S. Graham, MD

Syringomas are benign, eccrine, sweat gland tumors. Eruptive syringomas are rare variants that typically develop on the body's anterior surface. We present the case of a 21-year-old black man with multiple, eruptive, asymptomatic syringomas on his buttocks that had persisted for 3 months. This case is unusual in that the patient's age, race, and sex and the location of the lesions are not considered typical for eruptive syringomas. We also present a review of eruptive syringomas and recent literature.

Cutis. 2005;76:267-269.

Case Report

A 21-year-old black man presented with a 3-month history of an asymptomatic eruption on his buttocks. The patient denied prior irritation or trauma to the site.

He was not taking any medications and had no other health problems. Findings of the cutaneous examination included numerous 3-mm, symmetric, hyperpigmented papules on the buttocks and upper posterior thighs (Figure 1). The long axis of the lesions tended to be arranged along the skin tension lines, as seen in pityriasis rosea. The other findings of the cutaneous examination were unremarkable. The lesions were discrete, widespread, and without scale, and they did not blanch. Darier sign was absent. The initial

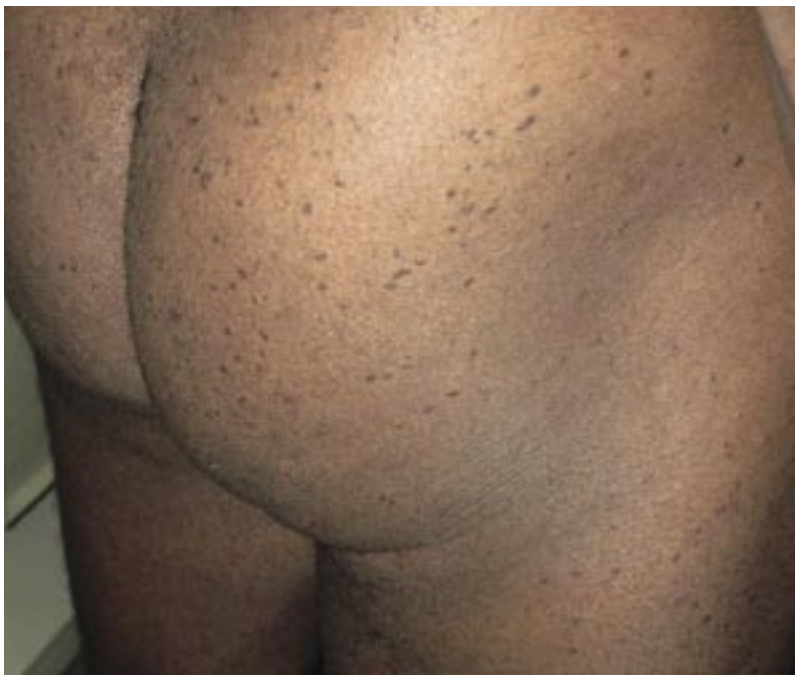

Figure 1. Multiple, symmetric, hyperpigmented papules on the buttocks.

diagnosis was mastocytosis or eruptive xanthomas. Results of a punch biopsy showed histopathologic features of syringomas; these findings were consistent with the clinical presentation of eruptive syringomas. The patient was offered a trial of carbon dioxide laser resurfacing, which he declined.

Comment

Syringomas were first described by Biesiadecki¹ and Kaposi² in the 19th century. Several years after the first description of syringomas, an infrequent variant termed *eruptive hidradenoma* (syringoma) was reported.³ Since then, 4 clinical variants have been described: a localized form, a familial form, a form associated with Down syndrome, and a generalized form that encompasses multiple and eruptive syringomas.⁴⁻⁷ Syringomas are described as uncommon, benign, appendicular sweat gland tumors arising

Accepted for publication June 30, 2004.

Dr. Powell is in private practice, Dallas, Texas. Dr. Smith is from the Pensacola Naval Hospital, Florida. Dr. Graham is in private practice, Tyler, Texas.

The authors report no conflict of interest.

Reprints: Charles L. Powell, MD, 1110 Cottonwood Lane, Suite 200, Irving, TX 75038

(e-mail: cpowell@healthcareassociates.com).

from the intraepidermal portion of the eccrine ducts.^{8,9} Several reports have broadened our understanding of these lesions. Even though most enzymatic studies suggest an eccrine origin, difficulties in distinguishing between eccrine and apocrine ducts suggest the possibility of an apocrine nature.^{4,6,7,10-12} Reports support the theory that some syringomas are under hormonal control via cell membrane receptors.^{13,14} Some authors question the neoplastic nature of syringomas, claiming that some cases represent a hyperplastic response of the eccrine duct to an inflammatory reaction.¹⁵

A review of the literature reveals generalizations about eruptive syringomas. Typical lesions are asymptomatic, flesh-colored, slightly hyperpigmented papules 3 to 5 mm in diameter.^{4,8} Variations from this typical picture have included differences in colors (red, tan, and yellow) and size (<1 cm); some cases have been associated with pruritus.^{4,8,16} Eruptive syringomas are most commonly described as successive crops of papules on the anterior surfaces of the body.¹⁷ Typical locations include the anterior trunk, neck, axilla, shoulder, and abdomen. Although the lesions are usually in a symmetric pattern, as in our case, unilateral involvement has been described.^{8,13,17-19}

Eruptive syringomas tend to be more prevalent in women and whites.^{4,8,10,20} However, one report claims a higher incidence of eruptive syringomas in African Americans than in whites.¹⁰ The reported differences in frequency among various racial groups may reflect the geographic locations and the populations studied. Eruptive syringomas have been described in all age groups. It has been reported that eruptive syringomas that develop after puberty are not found in normal apocrine gland locations.⁸

The differential diagnosis of eruptive syringomas includes lichen planus, verruca planus, acanthosis nigricans, steatocystoma multiplex, eruptive

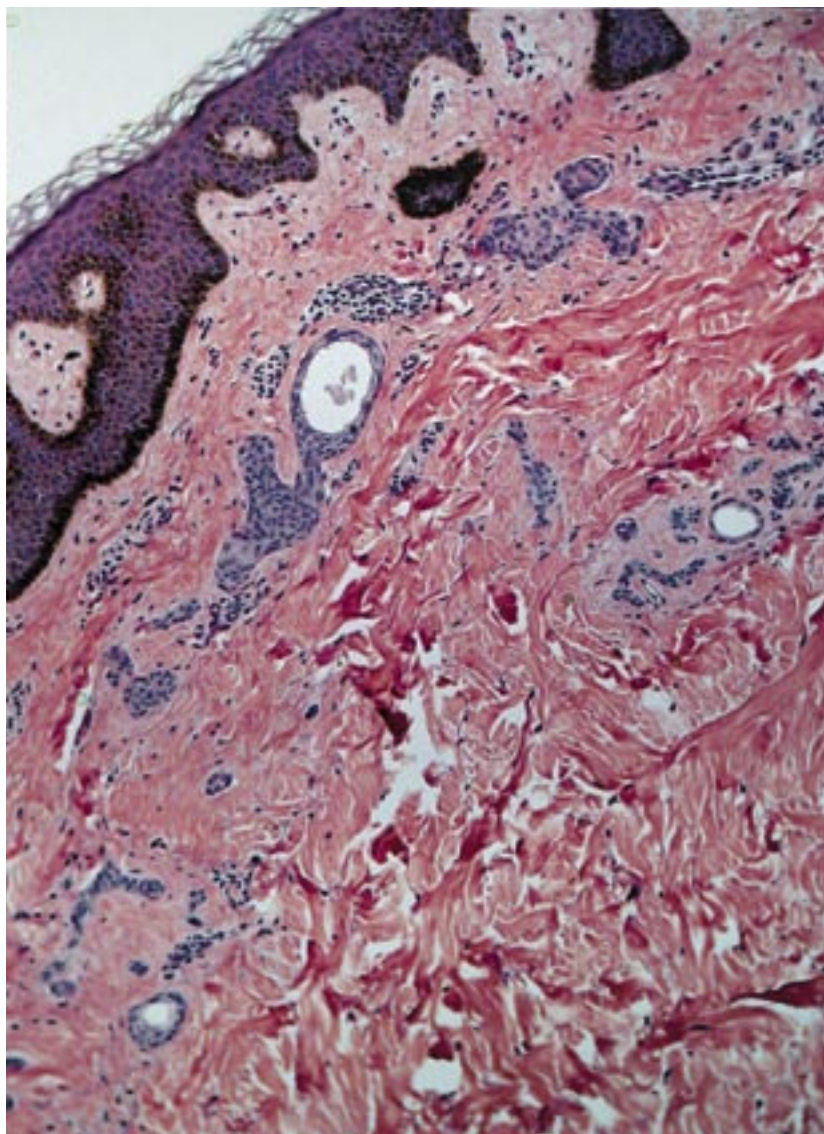


Figure 2. Amorphous, pale-staining, hyaline material within the lumen of a duct with rows of epithelial cells elongating to a typical commalike tail (H&E, original magnification $\times 400$).

vellus hair cysts, and secondary syphilis.^{8,13,15,17} Because of this broad clinical differential diagnosis, histologic examination is usually required for definitive diagnosis.⁸ The histopathologic findings include multiple small ducts and epithelial cords within the superficial dermis.^{5,8} These ducts are often lined with 2 layers of cuboidal to flattened epithelial cells, with the outer layer creating a commalike tail (Figure 2).^{4,5,8,10,21}

The treatment of syringomas is primarily for cosmetic reasons unless pruritus is present.¹⁰ Agents found to be ineffective include oral antihistamines, topical corticosteroids, topical retinoids, and topical antifungal agents.^{16,22} Therapies that have shown some success include

dermabrasion, electrodesiccation and curettage, and scissor excision. Scarring is a concern with these treatments.^{16,23-25} Newer therapies with less potential for scarring include carbon dioxide laser resurfacing and application of topical atropine (for pruritic cases).^{5,26} Some cases regress spontaneously.¹⁷

To our knowledge, the case we describe is only the second known case report of eruptive syringomas of the buttocks.²⁷ The rarity of this disorder and lack of unifying clinical characteristics make histopathologic examination important in the majority of cases.

REFERENCES

1. Biesiadecki A. *Lymphangioma Tuberosum Multiplex: Untersuchungen aus dem Pathologisch Anatomischen*. Vienna, Austria: Wilhelm Braumuller; 1882:387-393.
2. Kaposi M. Lymphangioma tuberosum multiplex. In: Fagge CH, trans-ed. *Hebra on Diseases of the Skin*. London, England: New Sydenham Society; 1872:386.
3. Jacquet L, Darier J. Hidradenomes eruptifs, I: epitheliomes adenoids des glandes sudoripares ou adenomas sudoripares. *Ann Dermatol Venereol*. 1887;8:317-323.
4. Friedman SJ, Butler DF. Syringoma presenting as milia. *J Am Acad Dermatol*. 1987;16:310-314.
5. Frazier CC, Comacho AP, Cockerell CJ. The treatment of eruptive syringomas in an African American patient with a combination of trichloroacetic acid and CO₂ laser destruction. *Dermatol Surg*. 2001;27:489-492.
6. Crespo EA, Sanz TA, Crespo EV. Syringoma eruptivo familiar. *Actas Dermo-Sif*. 1987;5:309-311.
7. Hashimoto A, Blum D, Fukaya T, et al. Familial syringoma. *Arch Dermatol*. 1985;121:756-760.
8. Soler-Carrillo J, Estrach T, Mascaro J. Eruptive syringoma: 27 new cases and review of the literature. *J Eur Acad Dermatol Venereol*. 2001;15:242-246.
9. Winkelmann RK, Gottlieb BF. Syringoma: an enzymatic study. *Cancer*. 1963;16:665-669.
10. Horenstein MG, Shea CR. Syringoma [eMedicine website]. Available at: <http://www.emedicine.com/derm/topic414.htm>. Accessed November 10, 2003.
11. Santa Cru DJ. Tumors of sweat gland differentiation. In: Farmer ER, Hood AF, eds. *Pathology of the Skin*. Norwalk, Conn: Appleton & Lange; 1990:631-632.
12. Lever WF, Schaumburg-Lever G. *Histopathology of the Skin*. Philadelphia, Pa: JB Lippincott; 1990:609-611.
13. Timpanidis P, Lakhani S, Groves R. Progesterone receptor-positive eruptive syringoma associated with diabetes. *J Am Acad Dermatol*. 2003;48(suppl 5):S103-S104.
14. Wallace ML, Smoller BR. Progesterone receptor positivity supports hormonal control of syringomas. *J Cutan Pathol*. 1995;22:442-445.
15. Guitart J, Rosenbaum M, Requena L. 'Eruptive Syringoma': a misnomer for a reactive eccrine gland ductal proliferation? *J Cutan Pathol*. 2003;30:202-205.
16. Sanchez TS, Dauden E, Casas AP, et al. Eruptive pruritic syringomas: treatment with topical atropine. *J Am Acad Dermatol*. 2001;44:148-149.
17. Pruzan DL, Esterly NB, Prose NS. Eruptive syringoma. *Arch Dermatol*. 1989;125:1119-1120.
18. Janniger CK, Brodtkin RH. Eruptive syringomas. *Cutis*. 1990;46:247-249.
19. Nguyen D, Patterson J, Wilson B. Syringoma of the moustache area. *J Am Acad Dermatol*. 2003;49:337-339.
20. Weiss E, Paez E, Greenberg AS, et al. Eruptive syringomas associated with milia. *Int J Dermatol*. 1995;34:193-195.
21. Metze D, Jureka W, Gebhart W. Disseminated syringomas of the upper extremities. *Dermatologica*. 1990;180:228-235.
22. Gomez MI, Perez B, Azana JM, et al. Eruptive syringoma: treatment with topical tretinoin. *Dermatology*. 1994;189:105-106.
23. Roenigk HH Jr. Dermabrasion for miscellaneous cutaneous lesions (exclusive of scarring from acne). *J Dermatol Surg Oncol*. 1977;3:322-328.
24. Stevenson TR, Swanson NA. Syringoma: removal by electrodesiccation and curettage. *Ann Plast Surg*. 1985;15:151-154.
25. Karam P, Benedetto AV. Intralesional electrodesiccation of syringomas. *Dermatol Surg*. 1997;23:921-924.
26. Apfelberg DB, Maser MR, Lash H, et al. Super pulse CO₂ laser treatment of facial syringomata. *Lasers Surg Med*. 1987;7:533-537.
27. Paquette DL, Massa MC. An unusual presentation of syringomas of the buttocks. *J Am Acad Dermatol*. 1998;39:1032-1033.