

Drug-Induced Linear Immunoglobulin A Bullous Dermatitis Mimicking Stevens-Johnson Syndrome: A Case Report

Julie E. Cummings, BS; Renee R. Snyder, MD; Erica B. Kelly, MD; Sharon S. Raimer, MD

GOAL

To understand drug-induced linear immunoglobulin A (IgA) bullous dermatosis (LABD) to better manage patients with the condition

OBJECTIVES

Upon completion of this activity, dermatologists and general practitioners should be able to:

1. Discuss the misdiagnosis of drug-induced LABD.
2. Recognize drugs associated with drug-induced LABD.
3. Describe treatment of bullous eruptions in patients with drug-induced LABD.

CME Test on page 200.

This article has been peer reviewed and approved by Michael Fisher, MD, Professor of Medicine, Albert Einstein College of Medicine. Review date: February 2007.

This activity has been planned and implemented in accordance with the Essential Areas and Policies of the Accreditation Council for Continuing Medical Education through the joint sponsorship of Albert Einstein College of Medicine and Quadrant HealthCom, Inc. Albert

Einstein College of Medicine is accredited by the ACCME to provide continuing medical education for physicians.

Albert Einstein College of Medicine designates this educational activity for a maximum of 1 AMA PRA Category 1 Credit™. Physicians should only claim credit commensurate with the extent of their participation in the activity.

This activity has been planned and produced in accordance with ACCME Essentials.

Ms. Cummings and Drs. Snyder, Kelly, and Raimer report no conflict of interest. The authors discuss off-label use of pentoxifylline and prednisone. Dr. Fisher reports no conflict of interest.

Linear immunoglobulin A (IgA) bullous dermatosis (LABD) is a rare autoimmune disorder characterized by vesicubullous mucocutaneous eruptions. LABD also has been reported as a drug-induced reaction. Idiopathic LABD and drug-induced LABD

are clinically indistinguishable and can resemble bullous pemphigoid, dermatitis herpetiformis, or bullous erythema multiforme. LABD is diagnosed with direct immunofluorescence (DIF), and idiopathic LABD can be distinguished from drug-induced LABD with a careful medication history. We present the case of a 54-year-old man with drug-induced LABD after ingestion of rimantadine, zanamivir, and azithromycin for presumed influenza. The patient's bullous eruption resolved with discontinuation of the offending medications and treatment with prednisone and pentoxifylline.

Cutis. 2007;79:203-207.

Accepted for publication July 31, 2006.

Ms. Cummings is a medical student, Dr. Kelly is Clinical Assistant Professor, and Dr. Raimer is Professor, all at the University of Texas Medical Branch, Galveston. Dr. Snyder is a dermatologist, private practice, Austin, Texas.

Reprints: Julie E. Cummings, BS, 1213 19th St, Galveston, TX 77550 (e-mail: jecummin@utmb.edu).

Linear immunoglobulin A (IgA) bullous dermatosis (LABD) is a rare autoimmune disorder characterized by vesiculobullous mucocutaneous eruptions. Defined diagnostic criteria for LABD are subepidermal bullae and a continuous band of homogeneous IgA deposited along the basement membrane.¹ Idiopathic LABD and drug-induced LABD are clinically indistinguishable because of a morphologically heterogeneous presentation consisting of tense vesicles arranged in a herpetiform, rosettelike, or arciform pattern with erythematous papules or urticarial plaques resembling bullous pemphigoid, dermatitis herpetiformis, or bullous erythema multiforme. A thorough history of drug intake to differentiate idiopathic LABD from drug-induced LABD and direct immunofluorescence (DIF) in any bullous eruption is advisable to prevent misdiagnosis and unwarranted treatment.²

Case Report

A 54-year-old man with a 3-week history of a non-specific illness consisting of fever, malaise, myalgia, and minor respiratory symptoms was seen as an outpatient and prescribed a 7-day course of rimantadine and a 5-day course of zanamivir for presumed influenza. The patient noted no significant improvement and returned to his primary care physician after he completed the course of treatment. A persistent fever was present with no signs of skin eruption or pruritus. Azithromycin was prescribed. After 3 days, the patient developed a generalized papulovesicular eruption. He was instructed to discontinue the medication and was given methylprednisolone intramuscularly and fexofenadine hydrochloride. The following day, the patient awoke unable to swallow, secondary to oral swelling and odynophagia. Vesicles and bullae in a generalized distribution were present on the skin. The patient was transferred to our institution and admitted to the burn unit. Physical examination revealed generalized erythema and a widespread bullous eruption on the trunk, extremities, and scrotum, and several erosions in the intertriginous areas (Figure 1). The eyelids were edematous and erythematous and the palpebral conjunctivae injected. The oral and genital mucosae were eroded. Intubation was necessary because of respiratory compromise caused by mucosal involvement. Nikolsky sign was negative. The suspected diagnosis at the time of presentation was Stevens-Johnson syndrome versus toxic epidermal necrolysis. Biopsy specimens were taken for frozen section and hematoxylin and eosin staining. Biopsy specimens of perilesional skin were tested with DIF studies.

Histopathologic and DIF Findings—Results of the frozen section biopsies revealed subepidermal

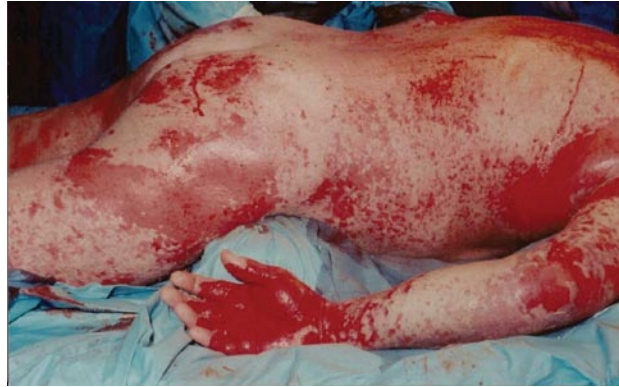

Figure 1. Patient one day after admission to the burn unit. Generalized erythema and a widespread bullous eruption on the trunk, extremities, and scrotum, and several erosions in the intertriginous areas were present.

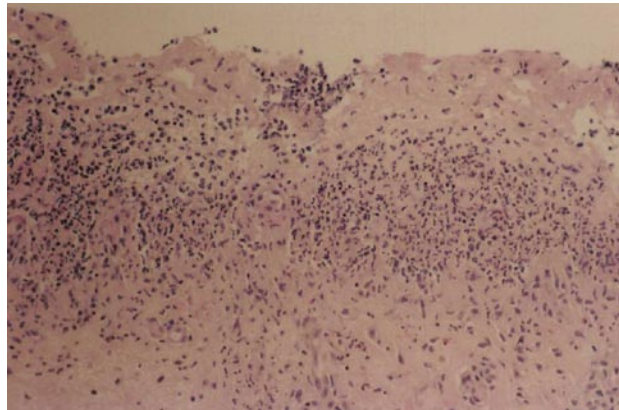


Figure 2. Results of the frozen section biopsies revealed subepidermal bullae with a fairly dense neutrophilic infiltrate and few eosinophils. Neutrophils also were distributed in the dermoepidermal junction and papillary dermis (original magnification $\times 10$).

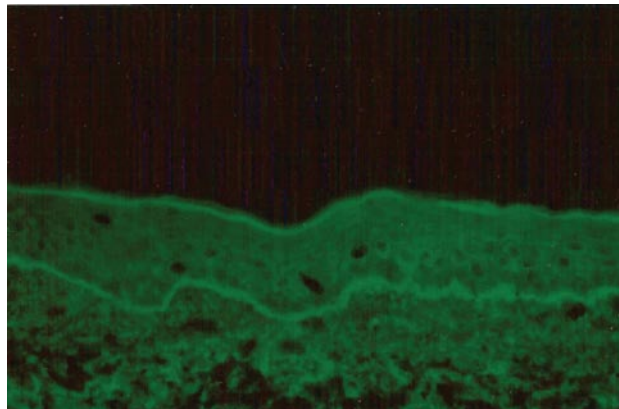


Figure 3. Direct immunofluorescence of the skin revealed a homogeneous linear pattern of immunoglobulin A deposition at the basement membrane zone (original magnification $\times 10$).

Autoimmune Blistering Diseases and the Triggering Drugs

Linear Immunoglobulin A Bullous Dermatitis	Pemphigus	Bullous Pemphigoid
Vancomycin ³	Cephalosporin ²³	Penicillamine ³⁵
Amiodarone hydrochloride ⁴	Rifampin ²⁴	Furosemide ³⁶
Ampicillin/Sulbactam ⁵	Heroin ²⁵	Amoxicillin ³⁷
Benazepril hydrochloride ⁶	Phenobarbital ²⁶	Phenacetin ³⁸
Candesartan cilexetil and eprosartan ⁷	Pentachlorophenol ²⁷	Sulfasalazine ³⁹
Captopril ^{4,8,9}	Carbamazepine ²⁸	Bumetanide ⁴⁰
Carbamazepine ¹⁰	Montelukast sodium ²⁹	Spirolactone ⁴¹
Diclofenac ¹¹	Penicillamine ³⁰	Chloroquine ⁴²
Furosemide ¹²	Captopril ³¹	
Gemcitabine hydrochloride ¹³	Penicillin and its derivatives ³²	
Interleukin 2 ¹⁴	Indapamide ³³	
Lithium carbonate ¹⁵	Piroxicam olamine ³⁴	
Naproxen ¹⁶		
Penicillin ¹⁷		
Phenytoin ^{8,18}		
Piroxicam olamine ^{19,20}		
Somatostatin analogue ⁸		
Sulfamethoxazole-trimethoprim ²¹		
Tea tree oil ²²		
Vigabatrin ²¹		

bullae with a fairly dense neutrophilic infiltrate and few eosinophils. Neutrophils also were visualized, distributed in the dermoepidermal junction and papillary dermis (Figure 2). Necrotic keratinocytes were not visualized. DIF of the skin revealed a homogeneous linear pattern of IgA deposition at the basement membrane zone (BMZ)(Figure 3).

The patient was treated with prednisone 80 mg daily. An initial attempt to taper the steroids on day 6 of treatment resulted in the development of new vesiculobullous lesions. At that time, pentoxifylline 400 mg 3 times daily was added and the eruption stabilized. On the 16th day of

the patient's hospital course, he showed no evidence of active disease, mucous membranes were uninvolved, and his oral discomfort had resolved. The acute bullous eruption that resolved after the discontinuation of all new medications and steroid therapy led to the diagnosis of drug-induced LABD mimicking Stevens-Johnson syndrome.

Comment

Drug-Induced LABD—Vancomycin is the drug most frequently associated with drug-induced LABD.³ Other drugs that have been reported include amiodarone hydrochloride,⁴ ampicillin/sulbactam,⁵

benazepril hydrochloride,⁶ candesartan cilexetil and eprosartan,⁷ captopril,^{4,8,9} carbamazepine,¹⁰ diclofenac,¹¹ furosemide,¹² gemcitabine hydrochloride,¹³ interleukin 2,¹⁴ lithium carbonate,¹⁵ naproxen,¹⁶ penicillin,¹⁷ phenytoin,^{8,18} piroxicam olamine,^{19,20} somatostatin analogue,⁸ sulfamethoxazole-trimethoprim,²¹ tea tree oil,²² and vigabatrin.²¹ The Table outlines autoimmune blistering diseases and the triggering drugs.

The mechanism by which the offending drug induces the production of autoantibodies toward BMZ components, including the anchoring filament protein laminin, is unknown.²¹ It is thought that after the drug is bound to the BMZ, a change in its 3-dimensional structure takes place that causes antigenicity. Target antigens are known to be heterogeneous; immune electron microscopy has shown localization of the IgA1 subclass in the lamina lucida, lamina densa, and sublamina densa.²¹

The eruption of LABD usually favors the trunk, proximal extremities, and acral regions, with mucous membrane involvement in 40% of reported cases.² Our patient presented with an acute severe generalized blistering disease involving the mucous membranes, which showed linear IgA deposition along the BMZ on DIF. The eruption occurred in relation to the ingestion of rimantadine, zanamivir, and azithromycin. Ultimately, treatment with prednisone and pentoxifylline resulted in resolution of his symptoms and the diagnosis of drug-induced LABD mimicking Stevens-Johnson syndrome.

REFERENCES

- Chorzelski TP, Jablonska S, Beutner EH. Linear IgA bullous dermatosis. In: Beutner EH, Chorzelski TP, Bean SF, eds. *Immunopathology of the Skin*. New York, NY: Wiley; 1979:315-323.
- Nousari HC, Kimyai-Asadi A, Caeiro JP, et al. Clinical, demographic, and immunohistologic features of vancomycin-induced linear IgA bullous disease of the skin. *Medicine*. 1999;78:1-8.
- Dellavalle RP, Burch JM, Tayal S, et al. Vancomycin-associated linear IgA bullous dermatosis mimicking toxic epidermal necrolysis. *J Am Acad Dermatol*. 2003;48 (suppl 5):S56-S57.
- Primka EJ III, Liranzo MO, Bergfeld WF, et al. Amiodarone-induced linear IgA disease. *J Am Acad Dermatol*. 1994;31:809-811.
- Shimanovich I, Rose C, Sitaru C, et al. Localized linear IgA disease induced by ampicillin/sulbactam. *J Am Acad Dermatol*. 2004;51:95-98.
- Femiano F, Scully C, Gombos F. Linear IgA dermatosis induced by a new angiotensin-converting enzyme inhibitor. *Oral Surg Oral Med Oral Pathol Oral Radiol Endod*. 2003;95:169-173.
- Pena-Penabad C, Rodriguez-Lozano J, del Pozo J, et al. Linear IgA bullous dermatosis induced by angiotensin receptor antagonists. *Am J Med*. 2003;114:163-164.
- Kuechle MK, Stegemeir E, Maynard B, et al. Drug-induced linear IgA bullous dermatosis: report of six cases and review of the literature. *J Am Acad Dermatol*. 1994;30:187-192.
- Friedman IS, Rudikoff D, Phelps RG, et al. Captopril-triggered linear IgA bullous dermatosis. *Int J Dermatol*. 1998;37:608-612.
- Cohen LM, Ugent RB. Linear IgA bullous dermatosis occurring after carbamazepine. *J Am Acad Dermatol*. 2002;46(suppl 2):S32-S33.
- Gabrielsen T, Staerfelt F, Thune PO. Drug-induced bullous dermatosis with linear IgA deposits along the basement membrane. *Acta Derm Venereol*. 1981;61:439-441.
- Cerottini J, Ricci C, Guggisberg D, et al. Drug induced linear IgA bullous dermatosis probably induced by furosemide. *J Am Acad Dermatol*. 1999;41:103-105.
- del Pozo J, Martinez W, Yebra-Pimentel MT, et al. Linear immunoglobulin A bullous dermatosis induced by gemcitabine. *Ann Pharmacother*. 2001;35:891-893.
- Tranvan A, Pezen DS, Medenica M, et al. Interleukin-2 associated linear IgA bullous dermatosis. *J Am Acad Dermatol*. 1996;35(5 pt 2):865-867.
- McWhirter JD, Hashimoto K, Fayne S, et al. Linear IgA bullous dermatosis related to lithium carbonate. *Arch Dermatol*. 1987;123:1120-1122.
- Bouldin MB, Clowers-Webb HE, Davis JL, et al. Naproxen-associated linear IgA bullous dermatosis: case report and review. *Mayo Clin Proc*. 2000;75:967-970.
- Wakelin SH, Allen J, Zhou S, et al. Drug-induced linear IgA disease with antibodies to collagen VII. *Br J Dermatol*. 1998;138:310-314.
- Acostamadiedo JM, Perniciaro C, Rogers R. Phenytoin-induced linear IgA bullous disease. *J Am Acad Dermatol*. 1998;38(2 pt 2):352-356.
- Camilleri M, Pace JL. Linear IgA bullous dermatosis induced by piroxicam. *J Eur Acad Dermatol Venereol*. 1998;10:70-72.
- Plunkett RW, Chiarello SE, Beutner EH. Linear IgA bullous dermatosis in one of two piroxicam-induced eruptions: a distinct direct immunofluorescence trend revealed by the literature. *J Am Acad Dermatol*. 2001;45:691-696.
- Paul C, Wolkenstein P, Prost C, et al. Drug-induced linear IgA disease: target antigens are heterogeneous. *Br J Dermatol*. 1997;136:406-411.
- Perrett CM, Evans AV, Russell-Jones R. Tea tree oil dermatitis associated with linear IgA disease. *Clin Exp Dermatol*. 2003;28:167-170.
- Pellicano R, Iannantuono M, Lomuto M. Pemphigus erythematosus induced by ceftazidime. *Int J Dermatol*. 1993;32:675-676.

24. Gange RW, Rhodes EL, Edwards CO, et al. Pemphigus induced by rifampicin. *Br J Dermatol*. 1976;95:445-448.
25. Downie JB, Dicostanzo DP, Cohen SR. Pemphigus vegetans-Neumann variant associated with intranasal heroin abuse. *J Am Acad Dermatol*. 1998;39(5 pt 2):872-875.
26. Sehgal VN, Srivastava G. Corticosteroid-unresponsive pemphigus vulgaris following antiepileptic therapy. *Int J Dermatol*. 1988;27:258.
27. Lambert J, Schepens P, Janssens J, et al. Skin lesions as a sign of subacute pentachlorophenol intoxication. *Acta Derm Venereol*. 1986;66:170-172.
28. Patterson CR, Davies MG. Carbamazepine-induced pemphigus. *Clin Exp Dermatol*. 2003;28:98-99.
29. Cetkovska P, Pizinger K. Childhood pemphigus associated with montelukast administration. *Clin Exp Dermatol*. 2003;28:328-329.
30. Toth GG, Jonkman MF. Successful treatment of recalcitrant penicillamine-induced pemphigus foliaceus by low-dose intravenous immunoglobulins. *Br J Dermatol*. 1999;141:583-585.
31. Butt A, Burge SM. Pemphigus vulgaris induced by captopril. *Br J Dermatol*. 1995;132:315-316.
32. Duhra P, Foulds IS. Penicillin-induced pemphigus vulgaris. *Br J Dermatol*. 1988;118:307.
33. Bayramgurler D, Ercin C, Apaydin R, et al. Indapamide-induced pemphigus foliaceus. *J Dermatolog Treat*. 2001;12:175-177.
34. Martin RL, McSweeney GW, Schneider J. Fatal pemphigus vulgaris in a patient taking piroxicam. *N Engl J Med*. 1983;309:795-796.
35. Weller R, White MI. Bullous pemphigoid and penicillamine. *Clin Exp Dermatol*. 1996;21:121-122.
36. Baz K, Ikizoglu G, Kaya TI, et al. Furosemide-induced bullous pemphigoid. *J Eur Acad Dermatol Venereol*. 2002;16:81-82.
37. Alcalay J, David M, Ingber A, et al. Bullous pemphigoid mimicking bullous erythema multiforme: an untoward side effect of penicillins. *J Am Acad Dermatol*. 1988;18:345-349.
38. Kashiwara M, Danno K, Miyachi Y, et al. Bullous pemphigoid-like lesions induced by phenacetin: report of a case and an immunopathologic study. *Arch Dermatol*. 1984;120:1196-1199.
39. Quartey-Papafio CM, Hudson PM. Bullous pemphigoid initially localized to sites of burns (scalds) in a patient on sulphasalazine for ulcerative colitis. *Clin Exp Dermatol*. 1994;19:281.
40. Boulinguez S, Bernard P, Bedane C, et al. Bullous pemphigoid induced by bumetanide. *Br J Dermatol*. 1998;138:548-549.
41. Modeste AB, Cordel N, Courville P, et al. Bullous pemphigoid induced by spironolactone [in French]. *Ann Dermatol Venereol*. 2002;129:56-58.
42. Millard TP, Smith HR, Black MM, et al. Bullous pemphigoid developing during systemic therapy with chloroquine. *Clin Exp Dermatol*. 1999;24:263-265.

DISCLAIMER

The opinions expressed herein are those of the authors and do not necessarily represent the views of the sponsor or its publisher. Please review complete prescribing information of specific drugs or combination of drugs, including indications, contraindications, warnings, and adverse effects before administering pharmacologic therapy to patients.

CONFLICT OF INTEREST STATEMENT

The Conflict of Interest Disclosure Policy of Albert Einstein College of Medicine requires that authors participating in any CME activity disclose to the audience any relationship(s) with a pharmaceutical or equipment company. Any author whose disclosed relationships prove to create a conflict of interest, with regard to their contribution to the activity, will not be permitted to present.

The Albert Einstein College of Medicine also requires that faculty participating in any CME activity disclose to the audience when discussing any unlabeled or investigational use of any commercial product, or device, not yet approved for use in the United States.