

Acquired Periungual Fibrokeratoma: A Case Report

Ryan M. Carlson, DO; Kenneth M. Lloyd, MD; Tom E. Campbell, MD

Acquired periungual fibrokeratoma (APF) is an uncommon lesion located around the nail and related to acquired digital fibrokeratoma. Histologic features of APF include a core of thick collagen bundles oriented along the longitudinal axis of the tumor and a very characteristic pseudo-nail plate formation. Different terms have been used to describe these lesions, and there has been no consensus on the terminology for some years. It is now believed that trauma may play a role in the pathogenesis of these periungual lesions.

Cutis. 2007;80:137-140.

Acquired periungual fibrokeratoma (APF) was first coined in 1977 by Cahn.¹ He postulated that APF was the same as garlic-clove fibroma, which was first identified by Steel² in 1965.¹ Additionally, histologic similarities were observed between APF and acquired digital fibrokeratoma.^{3,4} It was decided that the term *garlic-clove fibroma* should be withdrawn and replaced with the more appropriate topographic designation, APF.¹ In this report, we present a classic case of APF and review the clinical features, histology, surgical implications, pathogenesis, and classification system of APF.

Case Report

A 78-year-old white man presented in September 2004 for evaluation of a growth at the base of the nail on the right middle finger. He denied any recent injury; however, he did recall slamming the finger in a car door several decades prior. The lesion was asymptomatic and the patient sought

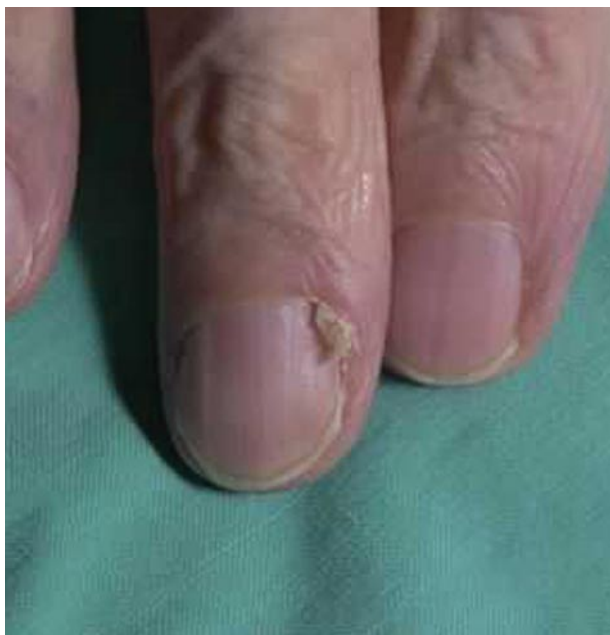

Figure 1. A firm, skin-colored, nontender mass laterally protruding over the nail plate from beneath the cuticle of the proximal nail fold. There was a hyperkeratotic nail-like extension growing from the distal end of the tumor.

treatment because the area was slowly enlarging and becoming unsightly. The patient denied any other significant cutaneous or systemic disease.

Clinical examination revealed a firm, skin-colored, nontender mass laterally protruding over the nail plate from beneath the cuticle of the proximal nail fold. There was a hyperkeratotic nail-like extension growing from the distal end of the tumor. In addition, there was palpable extension of the nodule proximally under the nail fold and an appreciable area of thinning and depression of the proximal nail plate under the lesion (Figure 1).

Two parallel longitudinal incisions on either side of the lesion allowed reflection of the proximal nail fold and proper visualization of the tumor. The mass was bluntly dissected away from its surrounding tissues (Figure 2). Care was taken to avoid damage to the nail matrix. Healing was without complication and healthy

Accepted for publication August 7, 2006.

Dr. Carlson is from Oakwood Southshore Medical Center, Trenton, Michigan. Dr. Lloyd is from Lloyd Dermatology & Laser Center, Youngstown, Ohio. Dr. Campbell is from Forum Health, Youngstown. The authors report no conflict of interest.

Reprints: Kenneth M. Lloyd, MD, Lloyd Dermatology & Laser Center, 8060 Market St, Youngstown, OH 44512 (e-mail: admin@lloyd-derm.com).

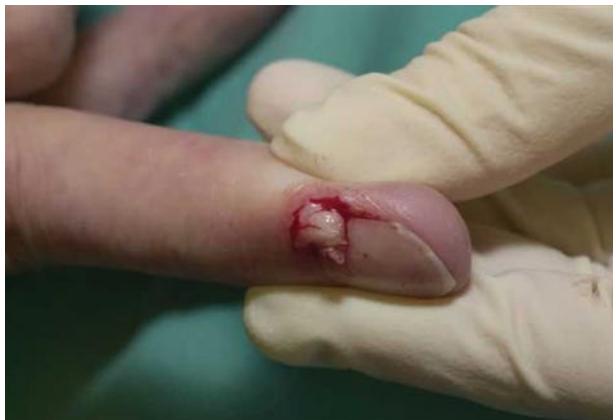

Figure 2. Reflection of the proximal nail fold and careful blunt dissection allowed visualization of the mass in its entirety.

nail contours were apparent 16 weeks after surgery. The surgical specimen was routinely fixed in formalin 10%, paraffin was embedded, and the nail was processed in serial sections. Histologically, sections disclosed hyperkeratosis and acanthosis, with an underlying nodular area of dense fibrosis containing fibroblasts (Figure 3). An area disclosing invagination with a pseudo-nail plate was identified (Figure 4). The region of fibrosis was relatively acellular with scant blood vessels and few inflammatory cells. Serial sections failed to demonstrate any neural structures or foreign bodies, and a CD34 marker was negative.

Comment

In 1977, Cahn¹ described an APF that was histologically congruent with the 10 cases of acquired digital fibrokeratomas first mentioned by Bart et al.³ Additionally, he determined that the tumors

described by Steel² in 1965 as garlic-clove fibromas were actually APFs, confirmed by histology. He stressed that the term *garlic-clove fibroma* should be discarded because APF is a more suitable term. Yasuki⁵ observed that APF essentially is a topographic variant of acquired digital fibrokeratoma.

APFs are rare, nonmalignant, hyperkeratotic, fibrous periungual tumors.^{1,6} They typically present as lesions originating from the proximal nail fold or sometimes from the nail bed^{6,7} but more specifically from the proximal margin of the germinal matrix.^{1,8,9} Similarly, acquired digital fibrokeratomas present as rounded sessile or pedunculated tumors with a hyperkeratotic yet usually smooth surface. They arise most often in adulthood in the proximal or distal interphalangeal joints of the fingers.^{10,11}

In 2002, Saito and Ishikawa⁶ surgically treated 5 patients with APF. In 2 patients, a white cornified object was found protruding from the distal end of the tumor. One object was cone shaped and the other was square shaped, suggesting a pseudonail.⁶ We also observed a pseudonail formation clinically in the shape of a cone, confirmed by histology. Before the work by Saito and Ishikawa,⁶ there were only a few case reports of an accessory nail apparatus.^{8,12} In 1985, Shelley and Phillips¹² reported an APF that clinically resembled a nail plate with a lunula at the proximal portion and histology depicting a true nail fold. Shelley and Phillips¹² added *accessory nail fibroma* to the list of terms for this lesion. Today, it is believed that an accessory germinal matrix is one of the defining characteristics of an APF.⁶ Other investigators believe that changes in pressure around the lesion induce the formation of the accessory germinal matrix.⁶

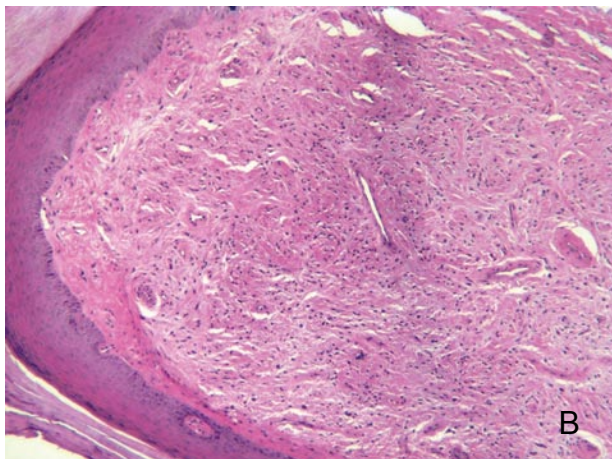
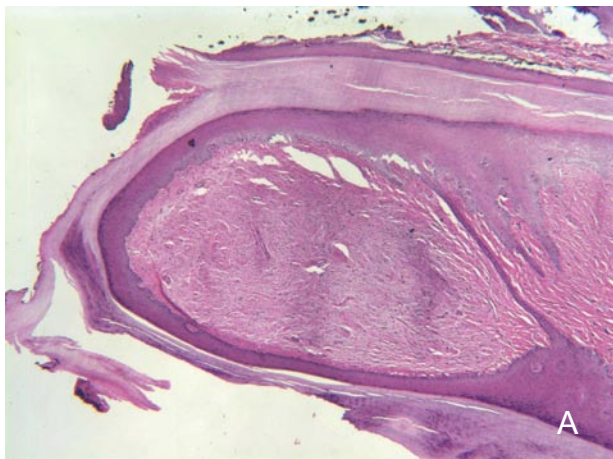


Figure 3. Beneath hyperkeratotic and mildly acanthotic skin, there is a dense core of thick collagen bundles containing fibroblasts (H&E, original magnification $\times 4$)(A). Hyperkeratosis and acanthosis is more evident in this higher power photomicrograph (H&E, original magnification $\times 10$)(B).

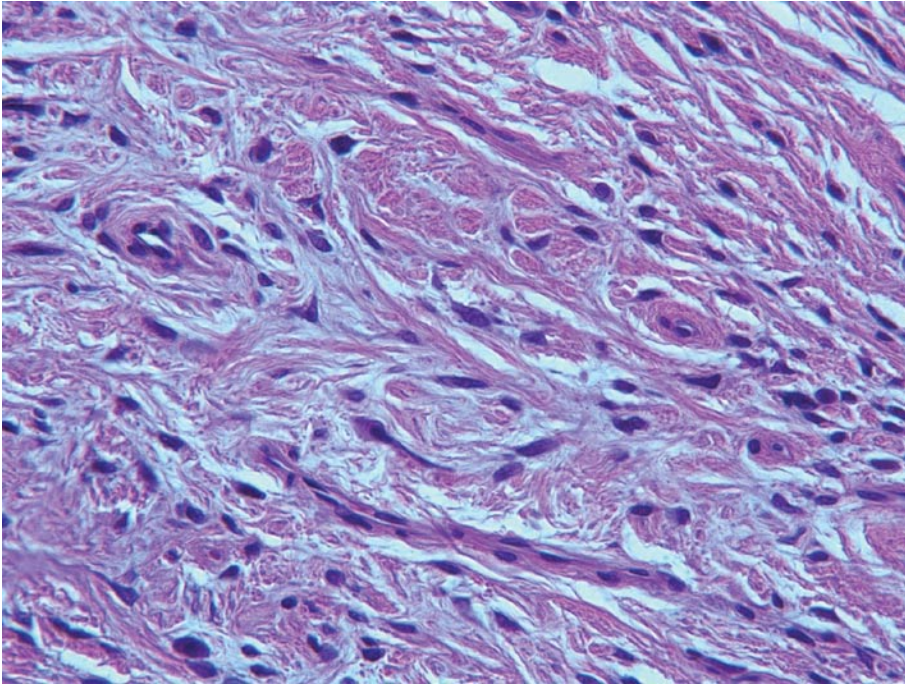


Figure 4. An area disclosing invagination with a pseudo-nail plate was identified (H&E, original magnification $\times 40$).

Several other diagnoses should be considered in a patient with a periungual tumor, such as Koenen tumors of tuberous sclerosis. Koenen tumors are observed in approximately 50% of patients with tuberous sclerosis^{13,14} and present as multiple, asymptomatic, pedunculated, flesh-colored subungual and periungual fibromas that develop underneath the proximal nail fold and rest on the nail plate.¹⁵ Koenen tumors appear most often during puberty.^{1,15} The lesions often present with other neuroendocrine signs of tuberous sclerosis (eg, adenoma sebaceum, shagreen patch). Yasuki⁵ considers the histology of a Koenen tumor to be quite distinct from an APF. The presence of conspicuous, atypical, stellate myofibroblasts within the fibrous core of the lesions associated with tuberous sclerosis allows distinction from APF. Additionally, epidermoid cysts,¹⁶ rudimentary supernumerary digits, endochondromas, neurofibromas, verruca vulgaris, and foreign-body granulomas must be considered in the differential diagnosis of APF. As with Koenen tumors, the histopathology, clinical history of trauma, gross appearance, and genetic background will assist in making a diagnosis of APF.

It is important to preserve the germinal matrix when surgically dissecting the tumor because this is the main source of nail production.⁶ Failing to do so may result in permanent alteration of nail contour and disfigurement. The tumor should be excised in whole with its basal attachment, as local recurrences can occur only when partial excision or curettage is performed.¹² Thus, adequate exposure of the whole

tumor and the surrounding nail matrix is crucial and is accomplished by reflection of the proximal nail fold.^{1,9}

Including the word *acquired* in the terminology of this unusual tumor leads one to believe that there is a precipitating factor; however, the causes for APF remain unclear. Some researchers have speculated that trauma may be involved. A report in 1969 had first suggested that acquired digital fibrokeratoma may be induced by trauma.¹⁰ Trauma to granulation tissue accompanying an ingrown toenail that resulted in the formation of an acquired digital fibrokeratoma was reported in 1974.¹⁷ APF also is thought to result from trauma. The current hypothesis is that these tumors are distinct clinical and histologic entities that represent a reactive hyperplasia initiated by trauma to the tissues.¹

In 1985, Yasuki⁵ devised a classification system for APF. APFs were classified into 2 groups, which were eventually divided into 5 histologic subtypes according to the topographic anatomy of the nail. Type 1 lesions included APFs that involved the nail plate and type 2 lesions derived from the periungual region, thus sparing the nail plate in the early stages.⁵

APF is an unusual fibrous lesion of the finger related to the more common acquired digital fibrokeratoma. APF differs from acquired digital fibrokeratoma by site of origin (ie, near the proximal nail fold), occasional gross and microscopic production of a pseudo-nail plate, and requirement for meticulous surgery both to remove the lesion and preserve nail cosmesis. Both lesions may be related to trauma.

REFERENCES

1. Cahn R. Acquired periungual fibrokeratoma. a rare benign tumor previously described as the garlic-clove fibroma. *Arch Dermatol.* 1977;113:1564-1568.
2. Steel H. Garlic-clove fibroma. *JAMA.* 1965;191:1082-1083.
3. Bart R, Andrade R, Kopf A, et al. Acquired digital fibrokeratomas. *Arch Dermatol.* 1968;97:120-129.
4. Verallo VV. Acquired digital fibrokeratomas. *Br J Dermatol.* 1968;80:730-736.
5. Yasuki Y. Acquired periungual fibrokeratoma—a proposal for the classification of periungual fibrous lesions. *J Dermatol.* 1985;12:349-356.
6. Saito S, Ishikawa K. Acquired periungual fibrokeratoma with accessory germinal matrix. *J Hand Surg.* 2002;6:549-555.
7. Hashiro M, Fujio Y, Tanaka M, et al. Giant acquired fibrokeratoma of the nail bed. *Dermatology.* 1995;190:169-171.
8. Kikuchi I, Ishii Y, Inoue S. Acquired periungual fibroma. *J Dermatol.* 1978;5:235-237.
9. Kojima T, Nagano T, Uchida M. Periungual fibroma. *J Hand Surg.* 1987;12:465-470.
10. Hare P, Smith PA. Acquired (digital) fibrokeratoma. *Br J Dermatol.* 1969;81:667-670.
11. Kint A, Baran R, Keyser H. Acquired (digital) fibrokeratoma. *J Am Acad Dermatol.* 1985;12:816-821.
12. Shelley W, Phillips E. Recurring accessory “fingernail”: periungual fibrokeratoma. *Cutis.* 1985;35:451-454.
13. Juhlin L, Baran R. Hereditary and congenital nail disorders. In: Baran R, Dawber RPR. *Diseases of the Nails and Their Management.* Oxford, England: Blackwell Scientific Publications; 1984:370-424.
14. Nickel WR, Reed WB. Tuberosus sclerosis: special reference to the microscopic alterations in the cutaneous hamartomas. *Arch Dermatol.* 1962;85:209-226.
15. Kint A, Baran R. Histopathologic study of Koenen tumors: are they different from acquired digital fibrokeratoma? *J Am Acad Dermatol.* 1988;18:369-372.
16. Saint Onge RA, Jackson IT. An uncommon sequel to thumb trauma: epidermoid cyst. *Hand.* 1977;9:52-56.
17. Herman PS, Datnow B. Acquired (digital) fibrokeratomas. complication of ingrown toenail. *Acta Derm Venereol.* 1974;54:73-75.