

Immunoglobulin A Pemphigus Involving the Perianal Skin and Oral Mucosa: An Unusual Presentation

Gulsun Erdag, MD; Hina S. Qureshi, MD; Kenneth E. Greer, MD; James W. Patterson, MD

Immunoglobulin A (IgA) pemphigus is a rare autoimmune blistering disease characterized by epidermal acantholysis and neutrophilic infiltrates, as well as intraepidermal IgA deposits. We report an unusual case of IgA pemphigus involving anal/perianal skin and oral mucosa that demonstrated a successful response to dapsone treatment.

Cutis. 2007;80:218-220.

Immunoglobulin A (IgA) pemphigus is a rare variant of pemphigus characterized by in vivo-bound and circulating IgA autoantibodies against cadherins on the keratinocyte cell surface.^{1,2} Clinically, it is characterized by pruritic vesiculopustular eruptions involving the axillae, groin, trunk, proximal extremities, and lower abdomen, and is treated with dapsone. In contrast to pemphigus vulgaris and pemphigus foliaceus, mucosal membranes generally are spared in patients with IgA pemphigus. Two subtypes of IgA pemphigus have been described: (1) subcorneal pustular dermatosis (SPD) and (2) intraepidermal neutrophilic (IEN) dermatosis.³ Histology of the lesions shows SPD and IEN infiltration with or without acantholysis. We report an unusual case of IgA pemphigus (IEN type) that presented with severe involvement of perianal skin and oral mucosa, unusual sites for this disorder. Only rare cases of IgA pemphigus have been reported to involve oral mucosa. To date, no cases of IgA

pemphigus with perianal involvement have been reported in the English language literature.

Case Report

A 56-year-old woman presented with a 5-day history of itchy blisters covering the entire anal and perianal area. She was in good general health and did not have associated systemic symptoms. Her past medical history was insignificant, except for hypertension and gastroesophageal reflux disease. Her medications included lisinopril, ezetimibel simvastatin, and esomeprazole magnesium. Physical examination revealed 2- to 6-mm blisters, some with purulent discharge, on the anal/perianal area, abdomen, calf, scalp, and tongue, and between the breasts (Figure 1). She had severe involvement of the anal/perianal area, where the lesions were florid. A Tzanck smear from the lesions of the anal area showed numerous neutrophils. Pemphigus was clinically suspected. A biopsy specimen from the abdominal lesions was sent for routine histology and immunofluorescence studies.

Hematoxylin and eosin stained sections from the biopsy specimen revealed neutrophilic aggregates, mainly within the epidermis, with rare subepidermal neutrophilic aggregates (Figure 2). Acantholysis was not observed. Direct immunofluorescence of the skin from the abdomen, using the standard laboratory technique, revealed diffuse heavy intercellular IgA deposits in the epidermis (Figure 3). Staining with antibodies to immunoglobulin M, immunoglobulin G, and C3 was negative.

The diagnosis of IgA pemphigus was made. Because of the rapid onset of symptoms and severe involvement of skin, especially perianal skin, treatment with oral dapsone (150 mg daily) and prednisone (60 mg daily) was started. Ninety percent of the patient's lesions improved within 2 weeks of initiating therapy. Both medications were gradually decreased; dapsone was reduced to 50 mg daily at 8 weeks and prednisone was discontinued.

Accepted for publication November 8, 2006.

Dr. Erdag is from the Department of Pathology, Georgetown University Medical Center, Washington, DC. Drs. Qureshi and Patterson are from the Department of Pathology and Dr. Greer is from the Department of Dermatology, all from the University of Virginia Health Sciences, Charlottesville.

The authors report no conflict of interest.

Reprints: Gulsun Erdag, MD, Department of Pathology, Georgetown University, 3900 Reservoir Rd, Washington, DC 20007

(e-mail: gulsun_erdag@yahoo.com).

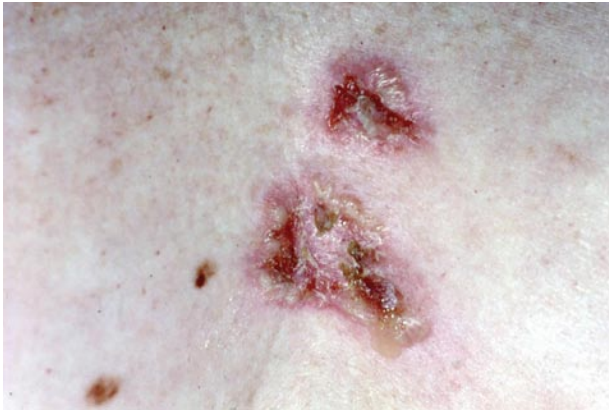

Figure 1. Skin lesions of immunoglobulin A pemphigus. Blisters, some with purulent discharge, were located on the anterior chest.

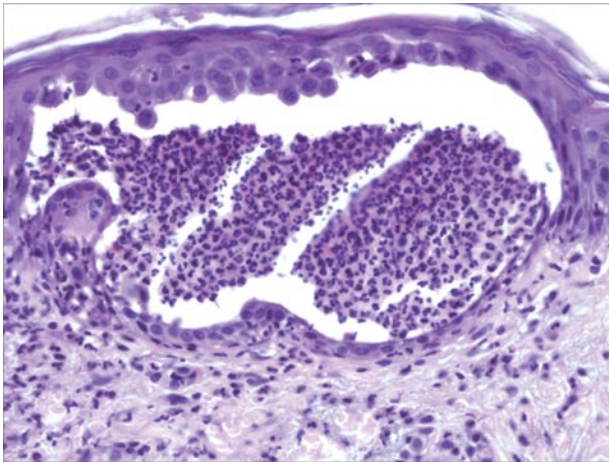


Figure 2. Stained section from a biopsy specimen showed intraepidermal blisters with neutrophils (H&E, original magnification $\times 40$).

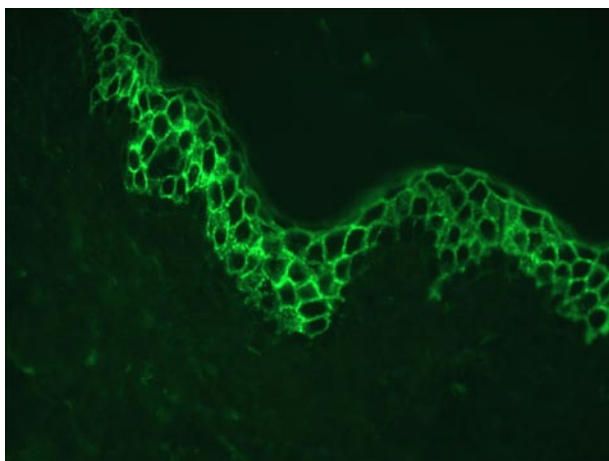


Figure 3. Direct immunofluorescence staining with antibodies to immunoglobulin A (IgA) showed intercellular deposition of IgA (original magnification $\times 40$).

At 8-month follow-up, her lesions had greatly improved, with only a few blisters on her calf.

Comment

IgA pemphigus represents a rare group of autoimmune intraepidermal blistering disorders with bound and circulating IgA antibodies against keratinocyte surface components.¹⁻³ It is classified into 2 distinct subtypes according to clinical and histopathologic features: SPD and IEN dermatosis.⁴ In SPD-type IgA pemphigus, histology shows subcorneal pustules and direct immunofluorescence is positive for IgA localized in the superficial epidermis. The IgA is directed against a desmosomal cadherin, desmocollin 1.⁵ In IEN-type IgA pemphigus, there are intraepidermal pustules and direct immunofluorescence is positive for IgA throughout the epidermis. The antigen bound by IgA is not clearly known, but desmogleins 1 and 3 have been identified in some cases.⁶⁻⁸

In contrast to common forms of pemphigus, the lesions in IgA pemphigus typically spare the mucous membranes and face. The lesions are localized to the axillae and inguinal folds in the SPD type and the trunk and extremities in the IEN type. More than 70 cases of IgA pemphigus in these locations have been reported in the literature. IgA pemphigus is more common in adults, though pediatric cases also have been reported.⁹⁻¹¹ Few cases of a combination of mucosal and skin involvement have been reported.¹¹⁻¹³ Bruckner et al¹³ described IgA pemphigus in a child involving the skin, oral mucosa, and colon. Our case showed severe perianal involvement, an unusual location for IgA pemphigus. The presence of IgA deposits throughout the epidermis confirmed that our case was the IEN type of IgA pemphigus. Although uncommon, anal involvement in pemphigus vulgaris has been reported in patients with severe disease.¹⁴ However, anal mucosa/skin is not a usual location for IgA pemphigus.

IgA pemphigus has a chronic and benign course. Dapsone is the first choice of therapy and the lesions respond well to the treatment.^{1,2} Other therapies, such as etretinate, psoralen plus UVA, or colchicine, also have been successfully used.^{15,16} Rare cases of IgA pemphigus that did not respond to dapsone therapy have been treated with other regimens including isotretinoin, acitretin, adalimumab, mycophenolate, and azithromycin.¹⁷⁻²⁰ Our patient showed an excellent response to dapsone treatment. She was nearly lesion free, with a few blisters on her calf after 8 months, and she did not show any relapse with tapering the dose.

We report a case of IgA pemphigus that presented with severe anal/perianal and oral mucosa

involvement, an unusual location for this disorder. The patient was successfully treated with dapsone.

REFERENCES

1. Huff JC, Golitz LE, Kunke KS. Intraepidermal neutrophilic IgA dermatosis. *N Engl J Med*. 1984;313:1643-1645.
2. Robinson ND, Hashimoto T, Amagai M, et al. The new pemphigus variants. *J Am Acad Dermatol*. 1999;40:649-671.
3. Hashimoto T. Immunopathology of IgA pemphigus. *Clin Dermatol*. 2001;19:683-689.
4. Hisamatsu Y, Amagai M, Garrod DR, et al. The detection of IgG and IgA autoantibodies to desmocollins 1-3 by enzyme-linked immunosorbent assays using baculovirus-expressed proteins, in atypical pemphigus but not in typical pemphigus. *Br J Dermatol*. 2004;151:73-83.
5. Hashimoto T, Kiyokawa C, Mori O, et al. Human desmocollin 1 (Dsc 1) is an autoantigen for the subcorneal pustular dermatosis type of IgA pemphigus. *J Invest Dermatol*. 1997;109:127-131.
6. Wang J, Kwon J, Ding X, et al. Nonsecretory IgA1 autoantibodies targeting desmosomal component desmoglein 3 in intraepidermal neutrophilic IgA dermatosis. *Am J Pathol*. 1997;150:1901-1907.
7. Karpati S, Amagai M, Liu WL, et al. Identification of desmoglein 1 as an autoantigen in a patient with intraepidermal neutrophilic IgA dermatosis type of IgA pemphigus. *Exp Dermatol*. 2000;9:224-228.
8. Ishii N, Ishida-Yamamoto A, Hashimoto T. Immunolocalization of target autoantigens in IgA pemphigus. *Clin Exp Dermatol*. 2004;29:62-66.
9. Gniadecki R, Bygum A, Clemmensen O, et al. IgA pemphigus: the first two Scandinavian cases. *Acta Derm Venereol*. 2002;82:441-445.
10. Suzuki M, Karube S, Kobori Y, et al. IgA pemphigus occurring in a 1-month-old infant. *J Am Acad Dermatol*. 2003;48(suppl 2):S22-S24.
11. Teraki Y, Amagai N, Hashimoto T, et al. Intercellular IgA dermatosis of childhood. *Arch Dermatol*. 1991;127:221-224.
12. Gooptu C, Mendelsohn S, Amagai M, et al. Unique immunobullous disease in a child with a predominantly IgA response to three desmosomal proteins. *Br J Dermatol*. 1999;141:882-886.
13. Bruckner AL, Fitzpatrick JE, Hashimoto T, et al. Atypical IgA/IgG pemphigus involving the skin, oral mucosa, and colon in a child: a novel variant of IgA pemphigus? *Pediatr Dermatol*. 2005;22:321-327.
14. Malik M, El Tal AE, Ahmed AR. Anal involvement in pemphigus vulgaris. *Dis Colon Rectum*. 2006;49:500-506.
15. Yasuda H, Kobayashi H, Hashimoto T, et al. Subcorneal pustular dermatosis type of IgA pemphigus: demonstration of autoantibodies to desmocollin-1 and clinical review. *Br J Dermatol*. 2000;143:144-148.
16. Hodak E, Lapidot M, David M. Effect of colchicines in the subcorneal pustular dermatosis type of IgA pemphigus. *J Am Acad Dermatol*. 1999;40:91-94.
17. Gruss C, Zillikens D, Hashimoto T, et al. Rapid response of IgA pemphigus of subcorneal pustular dermatosis type to treatment with isotretinoin. *J Am Acad Dermatol*. 2000;43(5 pt 2):923-926.
18. Ruiz-Genao DP, Hernandez-Nunez A, Hashimoto T, et al. A case of IgA pemphigus successfully treated with acitretin. *Br J Dermatol*. 2002;147:1040-1042.
19. Howell SM, Bessinger GT, Altman CE, et al. Rapid response of IgA pemphigus of the subcorneal pustular dermatosis subtype to treatment with adalimumab and mycophenolate mofetil. *J Am Acad Dermatol*. 2005;53:541-543.
20. Bliziotis I, Rafailidis P, Vergidis P, et al. Regression of subcorneal pustular dermatosis type of IgA pemphigus lesions with azithromycin. *J Infect*. 2005;51:E31-E34.