

Pulmonary and Cutaneous Sarcoidosis Associated With Interferon Therapy for Melanoma

Fabien Pelletier, MD; Philippe Manzoni, MD; Pascale Jacoulet, MD; Philippe Humbert, MD, PhD; François Aubin, MD, PhD

Interferon alfa is widely used as adjuvant therapy for melanoma. Numerous side effects have been attributed to interferon alfa. Interferon alfa-induced sarcoidosis is an uncommon event. We report the third case of pulmonary and cutaneous sarcoidosis in the course of interferon alfa treatment for melanoma. Most cases of sarcoidosis have been reported during treatment of chronic hepatitis C. The prognosis is good with discontinuation of treatment. Other than interferon therapy, sarcoidosis or granulomatous reactions rarely have been reported in malignant melanoma. We discuss and review the literature on the physiopathology of sarcoidosis brought on by interferon therapy.

Cutis. 2007;80:441-445.

Interferon alfa widely is used as an adjuvant treatment for melanoma. Numerous side effects have been attributed to interferon alfa, including autoimmune disorders such as systemic lupus erythematosus, thyroiditis, and rheumatoid arthritis. Pulmonary complications of interferon alfa are rare. The most common are pneumonitis. Interferon alfa-induced sarcoidosis is an uncommon event that mainly has been described during treatment of chronic hepatitis C. We report the third case of pulmonary and cutaneous sarcoidosis in the course of interferon alfa therapy for melanoma.

Accepted for publication January 17, 2007.

Drs. Pelletier, Humbert, and Aubin are from the Department of Dermatology; Dr. Manzoni is from the Department of Radiology; and Dr. Jacoulet is from the Department of Pneumology, all from the Centre Hospitalier Universitaire de Besançon and l'Université de Franche-Comté, both in France.

The authors report no conflict of interest.

Reprints: Fabien Pelletier, MD, Department of Dermatology, CHU Saint-Jacques, 2 Place Saint-Jacques, 25030 Besançon, Cedex, France (e-mail: fabien.pelletier@univ-fcomte.fr).

Case Report

A 60-year-old man was diagnosed with an inclassable primary melanoma of the left shoulder (T4b N2b M0, stage III of the American Joint Committee on Cancer classification) associated with clinically positive axillary lymph nodes. He had a past medical history of prostate cancer. Results of a computed tomographic (CT) scan of the whole body were normal. After wide excision and lymph node dissection, adjuvant therapy with high-dose interferon alfa was started. He received interferon alfa 20 million IU/m² intravenously 5 consecutive times a week for 4 weeks followed by 10 million IU/m² subcutaneously 3 times a week for 11 months.¹⁻³ During this therapeutic regimen, no other treatment except paracetamol was administered. The patient tolerated the therapy fairly well, except for anorexia and flu-like syndrome. After 7 months of treatment, physical examination revealed a subcutaneous nodule on the left leg. No lymphadenopathy was noted. In addition, the patient experienced mild effort dyspnea and a dry cough. Pulmonary examination revealed bilateral fine crackles occupying the lower parts of both lungs. Laboratory studies disclosed the following values: white blood cells, 3.1×10⁹/L (reference range, 4.5–11.0×10⁹/L); lymphopenia, 0.9×10⁹/L (reference range, 1.0–4.0×10⁹/L); CD4 lymphocyte, 0.5×10⁹/L (reference range, 1.0–4.8×10⁹/L); hemoglobin, 12.1 g/dL (reference range, 14.0–17.5 g/dL); and platelets, 110×10⁹/L-1; (reference range, 150–450×10⁹/L). The patient's CD4/CD8 ratio was lowered; his alanine aminotransferase, aspartate aminotransferase, calcemia, calciuria, and C-reactive protein levels were within reference range; and his serum angiotensin-converting enzyme level was elevated (40.2 nmol/mL/mn; reference range, 12–25 nmol/mL/mn).

CT scan results showed pulmonary interstitial-nodular infiltrates (Figure 1) and lymph node

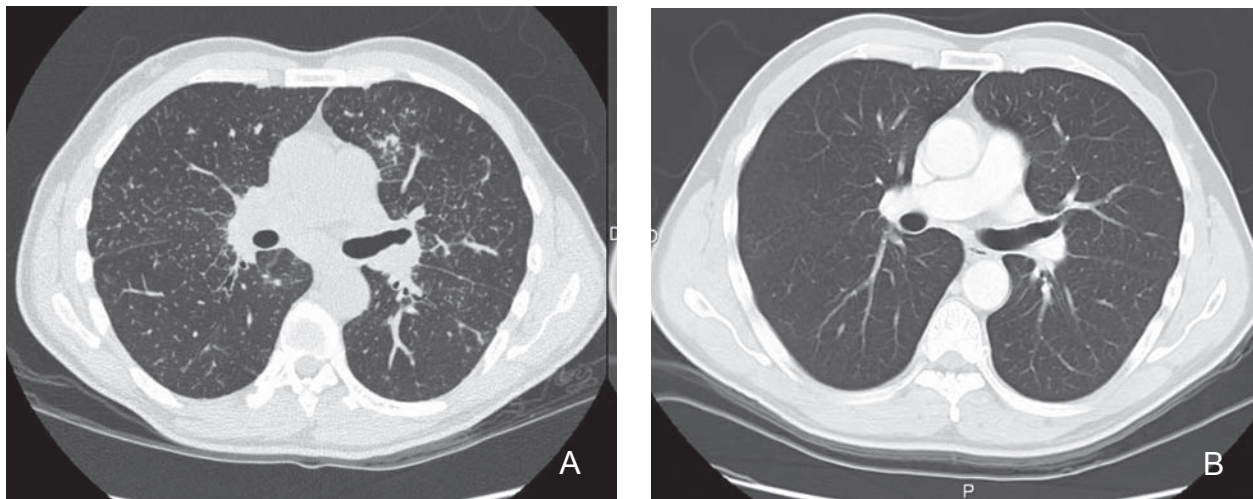


Figure 1. Computed tomographic scan results showed diffuse interstitial-nodular infiltrates (A). Diffuse infiltrates disappeared a year after discontinuation of interferon treatment (B).

swelling in the mediastinum (Figure 2). Bronchoscopy with transbronchial biopsy and bronchoalveolar lavage both were performed. Results of a biopsy of a bronchial specimen showed noncaseating granulomas. Results of a biopsy of a skin specimen revealed noncaseating epithelioid cell granulomas in the deep dermis and hypodermis (Figure 3). Cultures and polymerase chain reaction assays of biopsy specimens failed to detect mycobacteria. Examination of the bronchoalveolar lavage fluid was suggestive of the presence of lymphocytic alveolitis, with an increased CD4/CD8 ratio. The lung function study showed a vital capacity of 4 L and diffusing capacity of 76% of predicted normal values. Ophthalmic evaluation was not modified.

A diagnosis of pulmonary sarcoidosis stage II with Darier-Roussy nodule was made, and interferon therapy was stopped. Corticotherapy was not

indicated owing to satisfactory lung function. Three months later, all the patient's symptoms had disappeared, particularly the dry cough, and the patient had gained weight. Results of a chest x-ray showed a substantial regression of the hilar adenopathy and persistence of interstitial infiltrates in the lung parenchyma. A year later, the patient was asymptomatic; the skin nodule had regressed wholly, and the CT scan results were normal.

Comment

Interferon is commonly used in a wide spectrum of indications for tumoral and nontumoral diseases. The human interferons are classified into 2 groups: type 1 (eg, interferon alfa, interferon beta, interferon tau, interferon omega) and type 2 (interferon gamma). Interferon alfa and interferon beta are the subtypes most extensively studied in human malignancies.

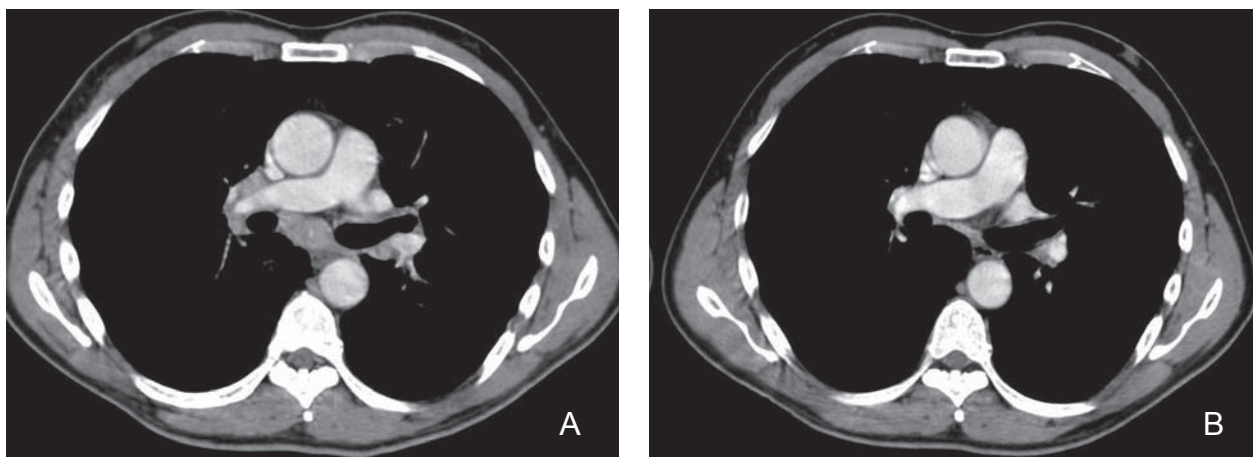


Figure 2. Computed tomographic scan results showed mediastinal and hilar lymphadenopathy (A). No lymph node swelling was observed one year after discontinuation of interferon treatment (B).

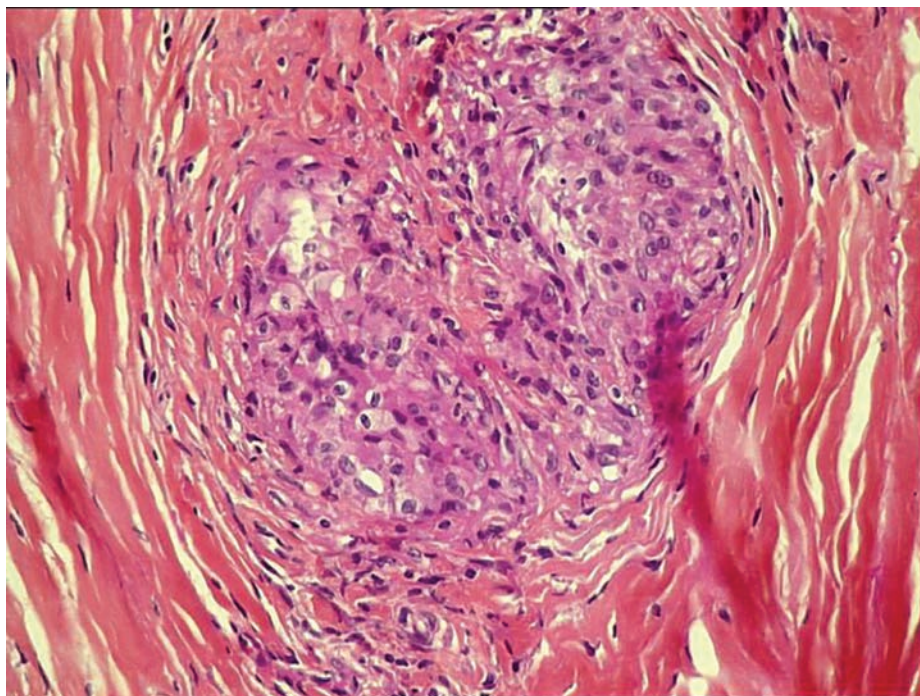


Figure 3. Noncaseating epithelioid cell granuloma (H&E, original magnification $\times 40$).

Both interferon alfa-2a and interferon alfa-2b are used as adjuvant treatment in patients with intermediate- or high-risk malignant melanoma (stages IIB and III of the American Joint Committee on Cancer classification).⁴

The side effects of interferons are numerous. Fever, chills, chest tightness, headaches, and depression are the more common adverse effects. Conlon et al⁵ reported that interferons have multiple effects on the immune system that may either induce or exacerbate autoimmune diseases. Some of their study patients had a preexisting subclinical illness that was either triggered by interferon or caused de novo by the drug.⁵ Reported autoimmune disorders are systemic lupus erythematosus, thyroiditis, hemolytic anemia, rheumatoid arthritis, and idiopathic thrombocytopenic purpura.^{5,6} However, pulmonary toxicity is relatively rare because clinical evidence of pneumonitis occurs in less than 1% of patients.^{5,7}

The development of sarcoidosis while receiving interferon treatment has been described infrequently (~40 observations).⁸ Pulmonary and cutaneous sarcoidosis associated with interferon are the most common, but neurosarcoidosis has been reported.⁹ Most reported cases of sarcoidosis were associated with interferon alfa, but sporadic cases related to interferon beta have been described.^{10,11} Although Abdi et al¹⁰ published a case of sarcoidosis that occurred in the course of treatment of a renal cell carcinoma, most cases (75%) of sarcoidosis induced by interferon alfa therapy have been

reported during treatment of chronic hepatitis C.¹²⁻²¹ In addition, sporadic cases of sarcoidosis have been associated with the treatment of myelogenous leukemia,²² multiple myeloma,¹⁰ multiple sclerosis,²³ and essential thrombocythemia.²⁴

The rarity of interferon-induced sarcoidosis is surprising if one considers the number of patients treated with interferon, which may suggest the intervention of a still unknown genetic background. Considering the dominant role of T_H1 (helper T cell 1) immune responses in the pathogenesis of sarcoidosis, the imputability of interferon alfa is probable because it stimulates helper T cells with a T_H1 profile immune response, which is the key immunologic event of granuloma formation²⁵ in susceptible individuals.¹²

Interferon alfa-induced sarcoidosis mainly involves the lungs and skin. The interval between onset of interferon and sarcoidosis usually varies from 2 weeks to several months, suggesting that interferon-induced granuloma formation is not dose related. However, the fact that pulmonary and cutaneous lesions improved remarkably after interferon discontinuation demonstrates a causal or at least temporal association.²⁶

The prognosis for most patients is good with discontinuation of therapy.²⁷ Most reports suggest that lesions resolve within months, regardless of interferon course.^{21,28,29} However, patients with systemic manifestations may have a more prolonged course of disease that requires discontinuation of interferon and initiation of systemic steroid treatment.

After previous reports by Massaguer et al³⁰ and Toulemonde et al,²⁹ we describe a third case of interferon alfa-induced systemic sarcoidosis occurring during the treatment of melanoma.

Other than with interferon therapy, sarcoidosis or granulomatous reactions rarely have been reported in malignant melanoma. Robert et al³¹ described 7 patients who presented with both granulomatous disease and melanoma; 3 cases were true sarcoidosis and 1 case was typical tumor-associated granuloma (absence of interstitial lung syndrome and subnormal serum angiotensin-converting enzyme level). In 3 cases, granulomatous nodules were not typical for sarcoidosis or for tumor-associated granuloma and were highly suggestive of melanoma metastases.³¹ The pathophysiology of tumor-associated sarcoid reaction remains uncertain, but a hypothesis can be made. The authors suggested that melanoma cells that secrete cytokines may induce granuloma formation or that tumor antigen-driven cell-mediated immune response could result in a sarcoid reaction.³¹

The question of whether a sarcoid reaction associated with cancer may have prognostic significance has been addressed.^{31,32} The authors hypothesized that the granulomatous reaction may confer a protective role through an immune response against tumor antigen, especially for melanoma, which is a highly immunogenic tumor.³¹ However, no conclusion can be drawn from the few cases published in the literature.

Although interferon alfa-induced sarcoidosis is a rare event, physicians should be aware that granulomatous lesions mimicking metastases may occur and should lead to careful histologic evaluation before starting unnecessary or even deleterious chemotherapies.

REFERENCES

1. Kirkwood JM, Ibrahim JG, Sosman JA, et al. High-dose interferon alfa-2b significantly prolongs relapse-free and overall survival compared with the GM2-KLH/QS-21 vaccine in patients with resected stage IIB-III melanoma: results of intergroup trial E1694/S9512/C509801. *J Clin Oncol.* 2001;19:2370-2380.
2. Kirkwood JM, Ibrahim JG, Sondak VK, et al. High- and low-dose interferon alfa-2b in high-risk melanoma: first analysis of intergroup trial E1690/S9111/C9190. *J Clin Oncol.* 2000;18:2444-2458.
3. Kirkwood JM, Strawderman MH, Ernstoff MS, et al. Interferon alfa-2b adjuvant therapy of high-risk resected cutaneous melanoma: the Eastern Cooperative Oncology Group Trial EST 1684. *J Clin Oncol.* 1996;14:7-17.
4. Molife R, Hancock BW. Adjuvant therapy of malignant melanoma. *Clin Rev Oncol Hematol.* 2002;44:81-102.
5. Conlon KC, Urba WJ, Smith JW, et al. Exacerbation of symptoms of autoimmune disease in patients receiving alpha-interferon therapy. *Cancer.* 1990;65:2237-2242.
6. Marzouk K, Saleh S, Kannass M, et al. Interferon-induced granulomatous lung disease. *Curr Opin Pulm Med.* 2004;10:435-440.
7. Okanou T, Sakamoto S, Itoh Y, et al. Side effects of high-dose interferon therapy for chronic hepatitis C. *J Hepatol.* 1996;25:283-291.
8. Salvio A, Mormile M, Giannattasio F, et al. Pulmonary sarcoidosis during interferon therapy: a rare or underestimated event? *Ann Ital Med Int.* 2004;19:58-62.
9. Miwa H, Furuya T, Tanaka S, et al. Neurosarcoidosis associated with interferon therapy. *Eur Neurol.* 2001;45:288-289.
10. Abdi EA, Nguyen GK, Ludwig RN, et al. Pulmonary sarcoidosis following interferon therapy for advanced renal cell carcinoma. *Cancer.* 1987;59:896-900.
11. Bobbio-Pallavicini E, Valsecchi C, Tacconi F, et al. Sarcoidosis following beta-interferon therapy for multiple myeloma. *Sarcoidosis.* 1995;12:140-142.
12. Husa P, Klusakova J, Jancikova J, et al. Sarcoidosis associated with interferon-alpha therapy for chronic hepatitis B. *Eur J Intern Med.* 2002;13:129-131.
13. Cogrel O, Doutre MS, Marliere V, et al. Cutaneous sarcoidosis during interferon alfa and ribavirin treatment of hepatitis C virus infection: two cases. *Br J Dermatol.* 2002;146:320-324.
14. Perez-Alvarez R, Perez-Lopez R, Lombrana JL, et al. Sarcoidosis in two patients with chronic hepatitis C treated with interferon, ribavirin and amantadine. *J Viral Hepat.* 2002;9:75-79.
15. Gitlin N. Manifestation of sarcoidosis during interferon and ribavirin therapy for chronic hepatitis C: a report of two cases. *Eur J Gastroenterol Hepatol.* 2002;14:883-885.
16. Hoffmann RM, Jung MC, Motz R, et al. Sarcoidosis associated with interferon-alpha therapy for chronic hepatitis C. *J Hepatol.* 1998;28:1058-1063.
17. Cacoub P, Sbai A, Frances C, et al. Systemic sarcoidosis during interferon-alfa therapy for chronic hepatitis C virus infection [in French]. *Gastroenterol Clin Biol.* 2000;24:364-366.
18. Rubinowitz AN, Naidich DP, Alinsonorin C. Interferon-induced sarcoidosis. *J Comput Assist Tomogr.* 2003;27:279-283.
19. Wendling J, Descamps V, Grossin M, et al. Sarcoidosis during combined interferon alfa and ribavirin therapy in 2 patients with chronic hepatitis C. *Arch Dermatol.* 2002;138:546-547.
20. Papaioannides D, Fotinou M, Korantzopoulos P, et al. Sarcoidosis associated with interferon-alpha therapy for chronic hepatitis C. *Med Sci Monit.* 2004;10:CS5-CS7.

21. Nawras A, Alsolaiman MM, Mehboob S, et al. Systemic sarcoidosis presenting as a granulomatous tattoo reaction secondary to interferon-alpha treatment for chronic hepatitis C and review of the literature. *Dig Dis Sci.* 2002;47:1627-1631.
22. Pietropaoli A, Modrak J, Utell M. Interferon-alpha therapy associated with the development of sarcoidosis. *Chest.* 1999;116:569-572.
23. Mehta CL, Tyler RJ, Cripps DJ. Granulomatous dermatitis with focal sarcoidal features associated with recombinant interferon beta-1b injections. *J Am Acad Dermatol.* 1998;39:1024-1028.
24. Frankova H, Gaja A, Hejlova N. Pulmonary sarcoidosis in a patient with essential thrombocythemia treated with interferon alpha: a short case report. *Med Sci Monit.* 2000;6:380-382.
25. Parronchi P, Mohapatra S, Sampognaro S, et al. Effects of interferon-alpha on cytokine profile, T cell receptor repertoire and peptide reactivity of human allergen-specific T cells. *Eur J Immunol.* 1996;26:697-703.
26. Leclerc S, Myers RP, Moussalli J, et al. Sarcoidosis and interferon therapy: report of five cases and review of the literature. *Eur J Intern Med.* 2003;14:237-243.
27. Ravenel JG, McAdams HP, Plankeel JE, et al. Sarcoidosis induced by interferon therapy. *AJR Am J Roentgenol.* 2001;177:199-201.
28. Rogers CJ, Romagosa R, Vincek V. Cutaneous sarcoidosis associated with pegylated interferon alpha and ribavirin therapy in a patient with chronic hepatitis C. *J Am Acad Dermatol.* 2004;50:649-650.
29. Toulemonde A, Quereux G, Dréno B. Sarcoidosis granuloma on a tattoo induced by interferon alpha [in French]. *Ann Dermatol Venereol.* 2004;131(1 pt 1):49-51.
30. Massaguer S, Sanchez M, Castel T. Mediastinal sarcoidosis induced by high-dose alpha-2-interferon therapy in a patient with malignant melanoma. *Eur Radiol.* 2004;14:1716-1717. Epub Jan 22, 2004.
31. Robert C, Schoenlaub P, Avril MF, et al. Malignant melanoma and granulomatosis. *Br J Dermatol.* 1997;137:787-792.
32. O'Connell MJ, Schimpff SC, Kirschner RH, et al. Epithelioid granulomas in Hodgkin disease. a favorable prognostic sign? *JAMA.* 1975;233:886-889.