

Atypical Chromhidrosis: A Case Report of Orange Sweat

Kristen Wyrick, MD; Timothy Cragun, DO; Brian Russ, MD; Michael C. Royer, MD

Chromhidrosis is a rare sweat gland disorder that produces pigmented sweat. The etiology of this disorder often is unknown and the clinical presentation can vary. We describe a previously asymptomatic patient who presented with bronzing of the skin and complained of orange stains on her clothing. The patient's symptoms began after a prophylactic hysterectomy with bilateral oophorectomy. She is the first reported patient with orange-pigmented sweat in chromhidrosis. She also is the first postmenopausal patient with chromhidrosis.

Cutis. 2008;81:167-170.

Chromhidrosis, the excretion of sweat containing pigment, is a rare but benign disorder that can affect the axillae, face, or areolae.¹ Pseudochromhidrosis is the change of color of normal eccrine sweat on the skin by surface compounds, molecules, or chromogenic bacteria.^{2,3} Both the apocrine and eccrine glands can be involved in chromhidrosis. The mechanism for the production of pigmented sweat in apocrine chromhidrosis involves oxidized lipofuscin pigment granules excreted from the apocrine glands. Pure axillary apocrine chromhidrosis is a more common disorder affecting approximately 10% of black individuals and fewer individuals of other ethnicities.³ The incidence of chromhidrosis

in other locations of the body is unknown because of limited case reports. Previously reported colors of apocrine sweat include black, blue, green, brown, red, and yellow.^{1,4-8} In eccrine chromhidrosis, water soluble pigment granules from ingested dyes or drugs^{2,3} are excreted. Chromhidrosis is not linked to other systemic disorders and has not been associated with any morbidity other than inconvenience and embarrassment. In this report, we present a postmenopausal patient with chromhidrosis producing orange secretions and bronzing of the skin.

Case Report

A 44-year-old woman presented with a chief complaint of orange skin and nails. For a year, she noticed that any white clothing she wore would become stained orange across her chest, especially on her undergarments and pajamas and most often after sleep or exercise. She denied a prickly sensation or aura of warmth with the secretion of the sweat. She also denied being able to manually express the pigmented sweat. She was unable to remove the stains with bleach or regular washing. The patient reported friends and family asking if she was tanning or using a self-tanner. Her fingernails also were discolored around the edges.

The patient's medical history was positive for breast cancer 1 gene, *BRCA1*, and liver cysts. She underwent an extensive evaluation, including a full malignancy workup for the liver cysts, which proved to be benign. She had previously complained of some numbness and tingling in her upper extremities and had been referred to neurology. Electromyography was negative for any nerve pathology. These neurologic symptoms eventually resolved without specific treatment. She had undergone a prophylactic hysterectomy with bilateral oophorectomy due to her *BRCA1* gene positivity prior to the onset of skin pigment symptoms. After the surgery, she reported typical postmenopausal symptoms, including hot flashes, night sweats, vaginal dryness, and mood swings. She was treated with conjugated vaginal estrogen cream and topical testosterone to control

Accepted for publication June 12, 2007.

Dr. Wyrick is from Family Medicine Residency, Travis Air Force Base, Fairfield, California. Dr. Cragun is from Family Medicine Residency, Andrews Air Force Base, Camp Springs, Maryland. Dr. Russ is from Wright-Patterson Air Force Base, Dayton, Ohio. Dr. Royer is from the Department of Pathology and Area Laboratory Services, Walter Reed Army Medical Center, Washington, DC. The authors report no conflict of interest.

The opinions and assertions contained herein are the private views of the authors and are not to be construed as official or as reflecting the views of the US Air Force medical departments or the US Air Force at large.

Correspondence: Kristen Wyrick, MD, 101 Bodin Cir, Travis AFB, CA 94534 (wyrick1@comcast.net).



Figure 1. The patient's face appeared bronze when compared to her back and legs.

these symptoms approximately 6 months after the onset of pigmented sweat; the medications did not improve her pigmented sweat. She took one multi-vitamin daily, which she discontinued immediately after the onset of symptoms without resolution. She denied taking additional supplements or medications and stated that her diet did not contain excessive amounts of pigmented fruits or vegetables. Additionally, she denied the use of lotions or creams and continued to have orange sweat after discontinuing use of all makeup products.

On physical examination, she appeared to be her stated age with normal vital signs and a body mass index of 22. The skin on her chest and face appeared bronze when compared to her back and legs (Figure 1). She had benign intradermal nevi but little evidence of sun damage. There was no evidence of dry crusted secretions and the physician was unable to express pigmented sweat from the affected areas. The bilateral edges of her fingernails also had orange discoloration. The remainder of her physical examination did not reveal any abnormalities. Homogentisic acid analysis of urine was negative for alkaptonuria. Additionally, a complete blood count and coagulation panel, adrenocorticotrophic hormone level and cortisol level, and iron panel and ferritin level were obtained to evaluate for a bleeding diathesis, Addison disease, and hemochromatosis, respectively, and were normal. The patient's clothing and undergarments showed staining, primarily across the chest with minimal axillary involvement (Figure 2). No staining was noted on the back of her clothing. Her clothing was viewed under a Wood lamp and did not autofluoresce. A punch biopsy of the chest wall above the right breast in an area of maximum pigmentation was performed and revealed normal skin with slight elasticity in the dermal layer. Yeast forms (ie, *Pityrosporum ovale*) were seen in some of the hair


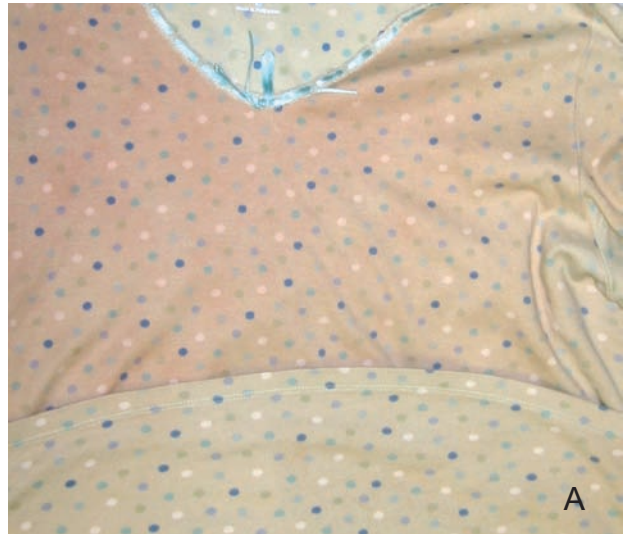


Figure 2. The patient's clothing (A) and undergarment (B) stained orange.

follicles (Figure 3). No apocrine glands were seen. Further evaluation and testing of the specimen was conducted at the Armed Forces Institute of Pathology in the environmental and infectious disease departments, including extensive testing of the eccrine glands (Figure 4). Fluorescent cytoplasmic granules within the eccrine glands that were not conclusively identified as lipofuscin were noted (Figure 5). Rare gram-positive cocci also were found within the eccrine glands. The patient declined further biopsies to isolate and evaluate the apocrine glands.

The patient was offered capsaicin cream as treatment but declined it because of the potential side effect of irritation. She was treated with a course of amoxicillin/clavulanate potassium 875-mg tablets twice daily for 10 days because of the finding of gram-positive cocci on biopsy. Topical antibiotics were not offered because of the large affected surface area. No improvement was noted by the patient after completion of this therapy. Botulinum toxin type A was not offered because of the large affected surface area.

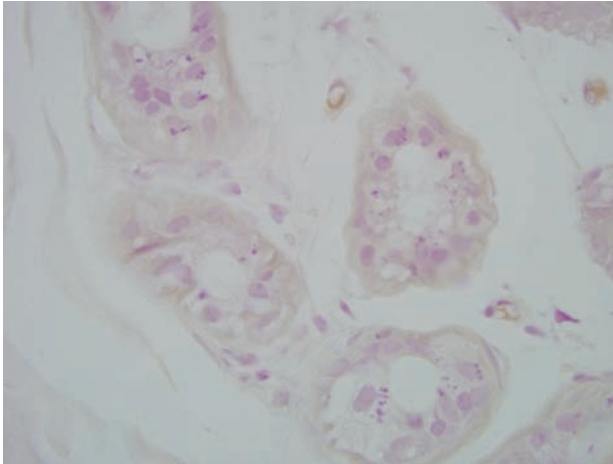


Figure 3. Yeast forms presented in some of the hair follicles, morphologically consistent with *Pityrosporum ovale* (H&E, original magnification $\times 1000$).

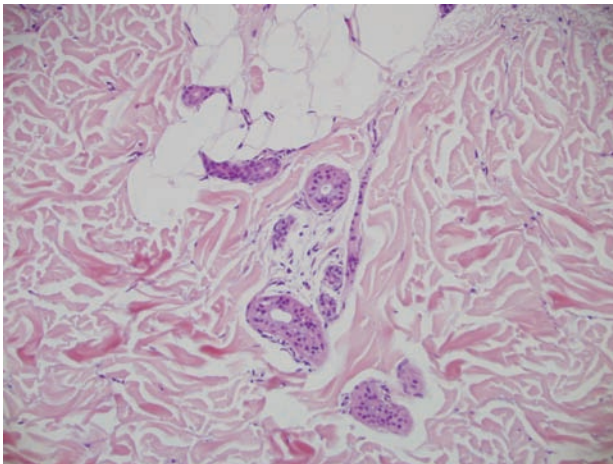


Figure 4. Unremarkable eccrine glands identified on routine evaluation of punch biopsy specimen (H&E, original magnification $\times 600$).

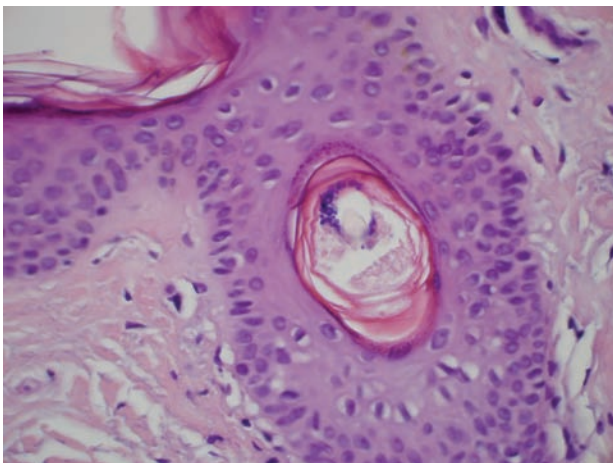


Figure 5. Pink-red intracytoplasmic granules (lipofuscin [modified carbol fuchsin], original magnification $\times 1000$).

Comment

Chromhidrosis is a rare sweat gland disorder characterized by the excretion of pigmented sweat arising from either the apocrine^{1,3-5} or eccrine glands.^{2,3,5} Additionally, pseudochromhidrosis, the change of pigment of normal eccrine sweat on the skin by surface compounds, molecules, or chromogenic bacteria, has been described in the literature.^{2,3,6}

In apocrine chromhidrosis, varying degrees of oxidized lipofuscin pigment granules within apocrine glands can cause black, blue, green, brown, red, and yellow sweat. The onset of apocrine chromhidrosis usually is preceded by a prickly sensation⁹ or aura of warmth on the skin prompted by emotional or physical stimuli. Additionally, the sweat can be manually expressed and dries quickly, leaving adherent pigmented flecks. The diagnosis of apocrine chromhidrosis is based on history and physical examination. The presence of lipofuscin pigment granules within the apocrine cells confirms the diagnosis.⁴

Eccrine chromhidrosis is the excretion of pigmented sweat from eccrine glands after the ingestion of dyes or drugs.³ Case reports of eccrine chromhidrosis are limited; however, red,² yellow,³ and blue¹⁰ excretions have been described.

Our patient denied the classic symptoms of a prickly sensation or aura of warmth prior to sweating and was unable to manually express the pigmented sweat. She noted that the staining was most prominent after sleep (when she experienced postmenopausal night sweats) and exercise. Her fingernails were discolored around the edges, most likely because of contact with the pigmented sweat. A thorough history did not demonstrate the ingestion of pigmented fruits, vegetables, or over-the-counter medications. Conjugated vaginal estrogen cream and topical testosterone were started for her postmenopausal symptoms and were initiated after the onset of pigmented sweat. Discontinuation of the medications did not improve her pigmented sweat. Because chromogenic bacteria have been listed as a cause of pseudochromhidrosis^{2,3} and gram-positive cocci were seen on biopsy, a course of amoxicillin/clavulanate potassium 875-mg tablets twice daily for 10 days was administered but did not affect the amount of skin hyperpigmentation or the staining of the patient's clothing. Unfortunately, the biopsy did not demonstrate involvement of apocrine glands; therefore, it is unknown if lipofuscin pigment granules in the apocrine glands were present. Eccrine glands were seen and demonstrated some fluorescent cytoplasmic granules that were most likely lipofuscin. After reviewing the literature and facts of this case, we hypothesized that our patient had eccrine chromhidrosis, though we are unable to completely rule out

an apocrine etiology with the lack of evaluation of apocrine glands.

The differential diagnosis for skin and sweat pigmentation includes hyperbilirubinemia, hematochromidrosis, alkaptonuria, copper exposure, Addison disease, and hemochromatosis. To rule out alkaptonuria, a homogentisic acid level should be measured. A complete blood count and coagulation panel can be checked to rule out a bleeding disorder. A Wood lamp evaluation of the sweat can be positive and affected clothing fibers can exhibit fluorescence¹¹ in apocrine chromhidrosis.

While no definitive treatment exists for chromhidrosis, a few case reports describe good outcomes with capsaicin cream^{12,13} and botulinum toxin type A injections.^{14,15} If eccrine chromhidrosis is suspected secondary to ingestion or exposure, the offending agent should be eliminated and the patient monitored for improvement. The prognosis is good if an extrinsic cause can be identified.³ In apocrine chromhidrosis, the patient can be reassured that the disease will slowly improve as involvement of the apocrine glands regress with time.^{3,9}

REFERENCES

1. Shelley WB, Hurley HJ. Localized chromhidrosis: a survey. *Arch Dermatol*. 1954;69:449-471.
2. Cilliers J, de Beer C. The case of the red lingerie-chromhidrosis revisited. *Dermatology*. 1999;199:149-152.
3. Kim J. Chromhidrosis. eMedicine Web site. <http://www.emedicine.com/derm/topic596.htm>. Updated September 12, 2006. Accessed December 15, 2006.
4. Griffith JR. Isolated areolar apocrine chromhidrosis. *Pediatrics*. 2005;115:239-241.
5. Mali-Gerrits MM, van de Kerkhof PC, Mier PD, et al. Axillary apocrine chromhidrosis. *Arch Dermatol*. 1988;124:494-496.
6. Thami GP, Kanwar AJ. Red facial pseudochromhidrosis. *Br J Dermatol*. 2000;142:1219-1220.
7. Barankin B, Alanen K, Ting PT, et al. Bilateral facial apocrine chromhidrosis. *J Drugs Dermatol*. 2004;3:184-186.
8. Saff DM, Owens R, Kahn TA. Apocrine chromhidrosis involving the areolae in a 15-year-old amateur figure skater. *Pediatr Dermatol*. 1995;12:48-50.
9. Daos MS, Dicken CH. Disorders of the apocrine sweat glands. In: Freedberg IM, Eisen AZ, Wolff K, et al, eds. *Fitzpatrick's Dermatology in General Medicine*. 6th ed. New York, NY: McGraw-Hill; 2003:707-713.
10. Hurley HJ, Witkowski J. Dye clearance and eccrine sweat secretion in human skin. *J Invest Dermatol*. 1961;36:259-272.
11. Cox NH, Popple AW, Large DM. Autofluorescence of clothing as an adjunct in the diagnosis of apocrine chromhidrosis. *Arch Dermatol*. 1992;128:275-276.
12. Marks JG. Treatment of apocrine chromhidrosis with topical capsaicin. *J Am Acad Dermatol*. 1989;21:418-420.
13. Rumsfield JA, West DP. Topical capsaicin in dermatologic and peripheral pain disorders. *DICP*. 1991;25:381-387.
14. Matarasso SL. Treatment of facial chromhidrosis with botulinum toxin type A. *J Am Acad Dermatol*. 2005;52:89-91.
15. Wu JM, Mamelak AJ, Nussbaum R, et al. Botulinum toxin a in the treatment of chromhidrosis. *Dermatol Surg*. 2005;31(8, pt 1):963-965.