



# Transforming vaginal hysterectomy: 7 solutions to the most daunting challenges

↘ Vaginal hysterectomy is a 21st Century approach, thanks to tools, techniques, and other refinements from the fields of laparoscopy and robotics

**Rosanne M. Kho, MD**

Vaginal hysterectomy is the preferred route to benign hysterectomy because it is associated with better outcomes and fewer complications than the laparoscopic and open abdominal approaches.<sup>1,2</sup> Yet, despite superior patient outcomes and cost benefits, the rate of vaginal hysterectomy is declining.

According to the Nationwide Inpatient Sample, the use of vaginal hysterectomy declined from 24.8% in 1998 to 16.7% in 2010.<sup>3</sup> In fact, more than 80% of surgeons in the United States now perform fewer than five vaginal procedures in a year.<sup>4</sup>

The increasing use of other minimally invasive routes, such as laparoscopy and robotics, indicates that most practicing surgeons and recent graduates are choosing these approaches over the vaginal route. In only 3 years, the rate of laparoscopy increased by 6% and robotics increased by almost 10%.<sup>3</sup>



Dr. Kho is Assistant Professor, Director of the Urogynecology Program, and Co-Director of the MIGS Fellowship Program at Columbia University Medical Center in New York, New York.

*The author reports that she is a consultant to Marina Medical and Symmetry Surgical.*

Many surgeons assume that vaginal hysterectomy exists in a state of suspended animation, with nothing much changed in the way it has been performed over the past few decades. Further, vaginal surgery is difficult to teach and learn, given limitations in exposure and visualization, difficulty in securing hemostasis, and challenges in the removal of the large uterus and adnexae. As a result, vaginal hysterectomy often is thought, erroneously, to be indicated only in procedures involving a small and prolapsing uterus.

To increase the rate of vaginal hysterectomy, we can benefit from experience gained in laparoscopy and robotics—whether we are teachers or learners—while maintaining patient safety and containing costs.

In this article, I describe common challenges in vaginal hysterectomy and offer tools and techniques to overcome them:

- achieving and enhancing ergonomics, exposure, and visualization
- the need to work in a long vaginal vault
- the task of securing vascular and thick tissue pedicles when the introitus and vaginal vault are narrow.

## The vaginal approach is less costly

Vaginal hysterectomy costs significantly less to perform than other approaches. At a tertiary referral center, vaginal hysterectomy costs approximately \$7,000 to \$18,000 per

### IN THIS ARTICLE

**Ergonomics, exposure, and visualization**  
page 35

**Benefits of vessel-sealing technology**  
page 37

### ON THE WEB

Dr. Kho presents hand morcellation, using advanced instruments. See page 36 for QR code or visit [obgmanagement.com](http://obgmanagement.com)

CONTINUED ON PAGE 34

### 8.3 Nursing Mothers

When possible, advise the nursing mother to use other forms of contraception until she has weaned her child. Estrogen-containing OCs can reduce milk production in breastfeeding mothers. This is less likely to occur once breastfeeding is well-established; however, it can occur at any time in some women. Small amounts of oral contraceptive steroids and/or metabolites are present in breast milk.

### 8.4 Pediatric Use

Safety and efficacy of Lo Loestrin Fe have been established in women of reproductive age. Efficacy is expected to be the same in postpubertal adolescents under the age of 18 years as for users 18 years and older. Use of this product before menarche is not indicated.

### 8.5 Geriatric Use

Lo Loestrin Fe has not been studied in postmenopausal women and are not indicated in this population.

### 8.6 Renal Impairment

The pharmacokinetics of Lo Loestrin Fe has not been studied in subjects with renal impairment.

### 8.7 Hepatic Impairment

No studies have been conducted to evaluate the effect of hepatic impairment on the disposition of Lo Loestrin Fe. However, steroid hormones may be poorly metabolized in patients with impaired liver function. Acute or chronic disturbances of liver function may necessitate the discontinuation of COC use until markers of liver function return to normal and COC causation has been excluded [see *Contraindications (4)* and *Warnings and Precautions (5.3)*].

### 8.8 Body Mass Index

The safety and efficacy of Lo Loestrin Fe in women with a body mass index (BMI) > 35 kg/m<sup>2</sup> has not been evaluated.

### 10 OVERDOSAGE

There have been no reports of serious ill effects from overdose of oral contraceptives, including ingestion by children. Overdosage may cause withdrawal bleeding in females and nausea.

### 17 PATIENT COUNSELING INFORMATION

See FDA-approved patient labeling.

Based on Lo Loestrin Fe Prescribing information dated 06/2012.

Manufactured By:  
Warner Chilcott Company, LLC  
Fajardo, PR 00738

Distributed By:  
Actavis Pharma, Inc.  
Parsippany, NJ 07054

© 2014, Actavis Pharma, Inc.

All rights reserved.

05/14



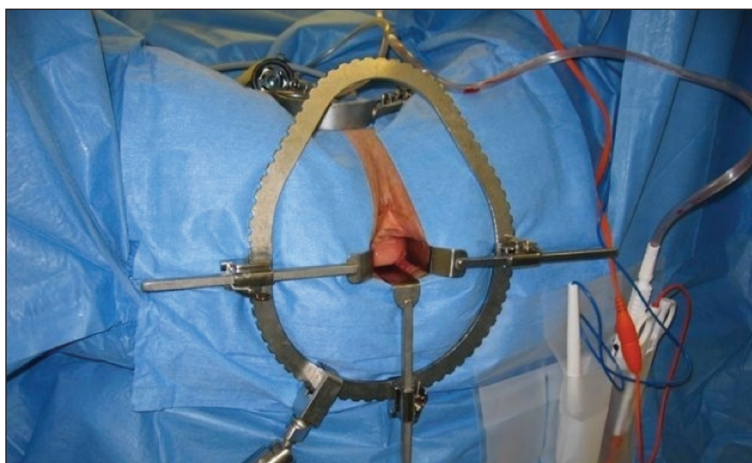## SURGICAL Techniques

### vaginal hysterectomy

CONTINUED FROM PAGE 29

case less than laparoscopic, abdominal, and robotic hysterectomy.<sup>5</sup> With declining use of vaginal hysterectomy and increasing use of more costly approaches, we face a health-care crisis.

### FIGURE 1 Vaginal retraction system



The Magrina-Bookwalter vaginal retractor system provides consistent and fixed retraction to maximize exposure. *Photo courtesy of Rosanne Kho, MD.*

### Residents are inadequately trained to perform vaginal hysterectomy

Data reveal that not only are our recent graduates inadequately prepared to perform vaginal hysterectomy, but national health-care dollars and resources are depleted when surgeons choose to perform more costly approaches. As a result, many eligible patients end up deprived of the benefits of a single, concealed, and minimally invasive procedure.

The increase in laparoscopic and robotic approaches to hysterectomy has affected residency training. National case log reports from the Accreditation Council of Graduate Medical Education show that the number of vaginal hysterectomies performed by residents as “primary surgeons” decreased by 40%, from a mean of 35 cases in 2002 to 19 cases in 2012.<sup>6</sup> A recent survey found that only 28% of graduating residents were “completely prepared” to perform a vaginal hysterectomy, compared with 58% for abdominal hysterectomy, 22% for laparoscopic hysterectomy, and 3% for the robotic approach.<sup>7</sup>

The rate of vaginal hysterectomy will

continue to decline if we perform it in the same manner it was done 30 years ago. The current generation of practicing gynecologists and graduates is choosing to perform the procedure laparoscopically or robotically because of the advantages these technologies provide. It is time that we incorporate features from these minimally invasive approaches to streamline vaginal hysterectomy while maintaining patient safety and containing costs.

### Challenges: Ergonomics, exposure, and visualization

In conventional vaginal surgery, the surgeon often is the person who has the best and, sometimes, the sole view. Two bedside assistants are required to hold retractors during the entire case, which can lead to fatigue and muscle strain. Poor lighting also can greatly limit visualization into the pelvic cavity.

Both laparoscopy and robotics provide a well-illuminated and magnified view, with three-dimensional images now available in both platforms. This view is projected to overhead monitors for the entire surgical team to see. Magnification of the pelvic anatomic structures and projection to an external monitor facilitate teaching and learning, better anticipation of the surgical and procedural needs, and overall patient safety.

From robotics, where ergonomics is exemplified, we also learn the importance of surgeon comfort during the procedure.

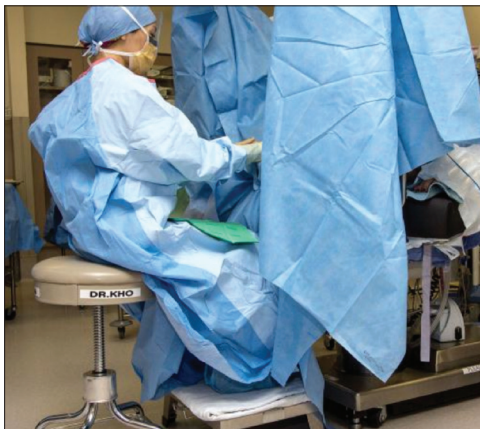
#### Solution #1: A self-retaining retractor

A self-retaining system such as the Magrina-Bookwalter vaginal retractor (Symmetry Surgical, Nashville, Tennessee) (FIGURE 1) eliminates the need for handheld retractors and eases strain on the two bedside assistants. It also allows trainees to focus on learning.

#### Solution #2: Seat the surgeon for an optimal view

With the patient in the lithotomy position and her legs in candy cane stirrups, the surgeon can be seated on a high chair so that the operative field is at the approximate level of the assistants' view (FIGURE 2). For ergonomics,

### FIGURE 2 Positioning



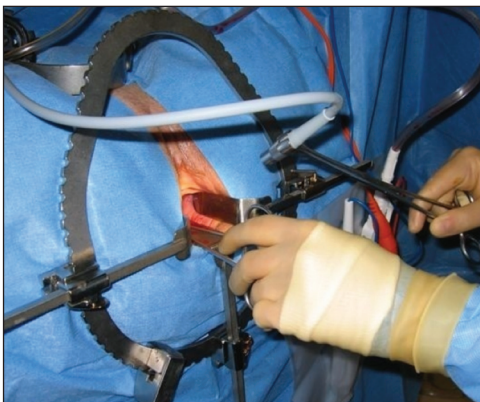The vaginal surgeon is seated in a chair adjusted in a high position so that the operative field is closer to the level of the bedside assistants. *Photo courtesy of Rosanne Kho, MD.*

the surgeon works with her elbows comfortably positioned at her sides. A low stool for the surgeon's feet creates a secure lap for laying instruments on a magnetic pad.

#### Solution #3: Illuminate the cavity

The deep pelvic cavity can be easily illuminated using a lighted suction tip, a flexible light source (as part of the cystoscopy set) held with a Babcock clamp (FIGURE 3), or a malleable illuminating mat taped to the retractor blades (such as Lightmat surgical illuminator, Lumitex, Inc., Strongsville, Ohio).

### FIGURE 3 Lighting is critical



A flexible light source from the cystoscopy set-up can be held with a Babcock clamp for illumination. *Photo courtesy of Rosanne Kho, MD.*

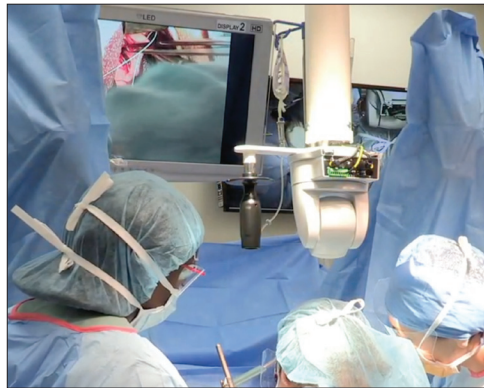### FAST TRACK

The surgeon can be seated on a high chair so that the operative field is at the level of the assistants' view and she can work with her elbows positioned comfortably at her sides

CONTINUED ON PAGE 36



### FIGURE 4 Overhead projection aids the team



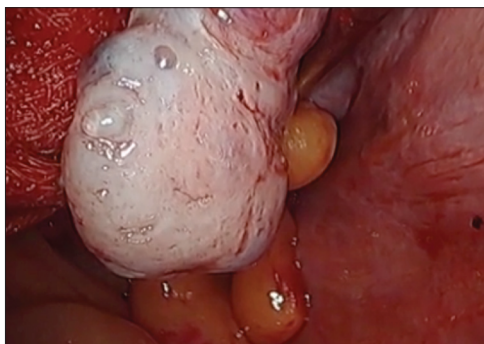
Overhead projection during vaginal surgery provides an external view to the entire surgical team. *Photo courtesy of Rosanne Kho, MD.*

#### Solution #4: Project the image

Cameras attached to an overhead boom or operating room light handles (FIGURE 4) and an external telescope with integrated illumination, such as a standard cystoscope or VITOM Exoscope (Karl Storz, El Segundo, California) (FIGURE 5) provide both magnification and projection of the procedure to an overhead monitor.

Glass technology (Google, Mountain View, California) also has been utilized in surgery and can be a good application of

### FIGURE 5 Magnify and illuminate the cavity



Use of a scope, such as a cystoscope or VITOM Exoscope, provides magnification and illumination deep in the pelvic cavity. *Photo courtesy of Kevin Stepp, MD.*

simultaneous projection and recording of the procedure to an external monitor (FIGURE 6). Google Glass is a wearable computer with an optical head-mounted display. The device, similar to eyeglasses, is voice-activated, thereby allowing the surgeon to record the procedure hands-free. Simultaneous projection to an external monitor allows the entire team in the operating room to be aware of the flow of the procedure.

### Challenge: Working in a narrow vaginal vault

Without correct instrumentation, this challenge can be especially daunting. Laparoscopy and robotics have changed the way we perform pelvic surgery by providing advanced instrumentation.

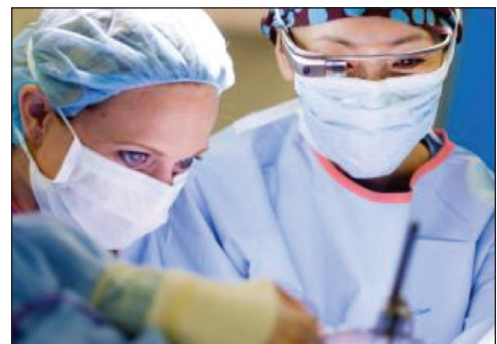#### Solution #5: Adapt your instruments

Modified vaginal instruments can be used to facilitate a case. (For an accompanying VIDEO on the use of improved vaginal instruments during morcellation, visit [obgmanagement.com](http://obgmanagement.com).)

Among the instruments adaptable for vaginal surgery:

- curving, articulating instruments
- long, curved, and rounded knife handles, which allow for better ergonomics during

### FIGURE 6 Simultaneous projection and recording



Use of glass technology allows simultaneous projection of surgery to an external monitor and recording of the case for teaching purposes. *Photo courtesy of Rosanne Kho, MD.*

### WATCH THE VIDEO!



Use this QR code to download the video to your Smartphone,\* or go to [obgmanagement.com](http://obgmanagement.com)

\*Free QR readers are available at the iPhone App Store, Android Market, and BlackBerry App World.

- prolonged morcellation
- modified long retractors and use of a single long vaginal pack provide retraction of loops of bowel and easy access to secure pedicles deep in the pelvis.

All of these instruments are available through Marina Medical in Sunrise, Florida.

### Challenge: Securing vascular and thick tissue pedicles

A narrow introitus and vaginal vault can be difficult to manage during vaginal surgery. Another challenge is a uterus that is large or deformed by multiple fibroids.

#### Solution #6: Vaginal incision

A simple superficial 2- to 3-cm incision on the distal posterior aspect of the vaginal wall can widen the introitus and vault to facilitate the procedure (FIGURE 7).

#### Solution #7: Vessel-sealing tools

The use of energy is integral to laparoscopy and robotics for dissection and securing vessels. In a meta-analysis that included seven randomized controlled trials, advanced vessel-sealing devices proved useful in vaginal surgery by decreasing blood loss and operative time.<sup>8</sup>

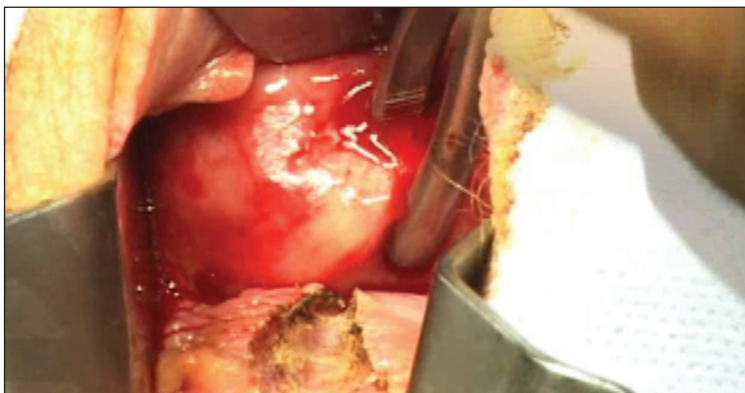
In the setting of a difficult vaginal hysterectomy with a narrow introitus and large uterus, the use of vessel-sealing technology allows the surgeon to skeletonize the uterine arteries while allowing progressive descensus to secure the upper pedicles.

In my experience, the use of an advanced vessel-sealing device, compared with traditional clamp-cut-tying technique, facilitated successful completion of vaginal hysterectomy in 650 patients with relative contraindications to the vaginal approach, such as nulliparity, a uterus weighing more than 250 g, and a history of cesarean delivery (Mayo Clinic data; yet unpublished).

### We must change with the times

The rate of vaginal hysterectomy will continue to decline unless we modify our technique to

### FIGURE 7 Widen the introitus



Make a superficial 2- to 3-cm incision on the distal posterior aspect of the vaginal wall to widen the introitus. Photo courtesy of Rosanne Kho, MD.

incorporate new technology. The current generation of practicing gynecologists and recent graduates are choosing the laparoscopic and robotic approaches because of the advantages these technologies offer. It is time we incorporate relevant features from these minimally invasive approaches while maintaining patient safety and containing costs by performing vaginal hysterectomy whenever possible. A willingness to change and ability to think outside the usual box will help us train new generations of vaginal surgeons who can bring back vaginal hysterectomy as the preferred route to the benign hysterectomy. 📌

#### References

- Nieboer TE, Johnson N, Lethaby A, et al. Surgical approach to hysterectomy for benign gynaecological disease. *Cochrane Database Syst Rev*. 2009;(3):CD003677.
- American College of Obstetricians and Gynecologists. ACOG Committee Opinion No. 444: Choosing the route of hysterectomy for benign disease. *Obstet Gynecol*. 2009;114(5):1156-1158.
- Wright T, Herzog T, Tsul J, et al. Nationwide trends in inpatient hysterectomy in the United States. *Obstet Gynecol*. 2013;122(2):233-241.
- Rogo-Gupta L, Lewyn S, Jum JH, et al. Effect of surgeon volume on outcomes and resource use for vaginal hysterectomy. *Obstet Gynecol*. 2010;116(6):1341-1347.
- Wright KN, Jonsdottir GM, Jorgensen S, Shah N, Einarsson JI. Costs and outcomes of abdominal, vaginal, laparoscopic and robotic hysterectomies. *JSL*. 2012;16(4):519-524.
- Washburn EE, Cohen SL, Manoucherie E, Zurawin, RJ, Einarsson JI. Trends in reported residency surgical experience in hysterectomy [published online ahead of print June 4, 2014]. *J Minim Invasive Gynecol*. doi:10.1016/j.jmig.2014.05.005.
- Burkett D, Horwitz J, Kennedy V, et al. Assessing current trends in resident hysterectomy training. *Female Pelvic Med Reconstr Surg*. 2011;17(5):210-214.
- Kroft J, Selk K. Energy-based vessel sealing in vaginal hysterectomy. A systematic review and meta-analysis. *Obstet Gynecol*. 2011;118(5):1127-1136.



**In a meta-analysis of seven randomized controlled trials, advanced vessel-sealing devices proved useful in vaginal surgery by reducing blood loss and operative time**