

What Is Your Diagnosis?

IMAGE NOT
AVAILABLE ONLINE

IMAGE NOT
AVAILABLE ONLINE

A 4-year-old girl presented to the dermatology clinic for the treatment of bullous impetigo. Examination revealed resolving angular cheilitis with secondary impetiginization, as well as frizzy, blond, unkempt-appearing shoulder-length hair. The patient's parents reported that the girl's hair was difficult to comb and had been unmanageable since birth.

The patient is the offspring of nonconsanguineous parents and was the product of a healthy pregnancy. She was born at 38 weeks' gestation by uncomplicated vaginal delivery and had experienced healthy growth and development. There was no known family history of hair disease.

PLEASE TURN TO PAGE 31 FOR DISCUSSION

Heidi F. Anderson, MD, University of Virginia School of Medicine, Charlottesville.

Cheryl L. Lonergan, MD, Department of Dermatology, University of Virginia.

Hina S. Qureshi, MD, Department of Pathology, University of Virginia.

Kelly M. Cordoro, MD, Department of Dermatology, University of Virginia.

The authors report no conflict of interest.

The Diagnosis: Uncombable Hair Syndrome

First described in 1973 by Dupre et al¹ as *cheveux incoiffables* and also now known as spun glass hair and *pili trianguli et canaliculi*, uncombable hair syndrome is characterized by dry, frizzy, silvery blond to light brown hair that does not lay flat on the head. Typically, the hair is noncompliant with attempts at management by a comb or brush.² Uncombable hair syndrome presents in infancy or during adolescence in rare cases.³ Hair grows at a slow to average rate, and the syndrome is not associated with any hair loss or fragility.⁴ Both inherited (autosomal dominant gene with incomplete penetrance) and sporadic forms have been described,⁵ though the genetic or biochemical changes underlying this condition have yet to be determined.⁶ The exact prevalence of uncombable hair syndrome is unknown. As in our patient, the anomaly is most commonly limited to scalp hairs (Figure 1), leaving eyelashes, eyebrows, and body hair unaffected. However, uncombable hair syndrome rarely has been described in association with features of ectodermal dysplasia.⁴ In addition, there is a case report of a child with uncombable hair in combination with phalango-epiphyseal dysplasia. It is debatable if any combination of dysmorphogenesis is true uncombable hair syndrome or if it should be classified as a separate entity.⁷

The differential diagnosis for uncombable hair syndrome includes *pili torti*, progeria, woolly hair, monilethrix, loose anagen hair syndrome, and acquired progressive kinking of the hair. Uncombable hair syndrome can be distinguished from these disorders by clinical features and microscopic examination.² Traditionally, scanning electron microscope examination has been the gold standard for confirming a clinical impression by revealing a characteristic triangular-, kidney-, or heart-shaped configuration in cross-section and well-defined longitudinal depressions of the hair shaft.³ Light microscope examination has been suggested as a more accessible and economical means of successful diagnosis through the use of paraffin-embedded hairs viewed under cross-section.⁸

The hair shafts in uncombable hair are most often triangular to kidney shaped in cross-section but can be flat or irregular. Longitudinal grooves running along the entire shaft are common. Although grooving of a few hair shafts can be seen in the hair of unaffected patients, at least 50% of the hair shafts in patients with uncombable hair syndrome





Figure 1. Uncombable hair syndrome is characterized by dry, frizzy, silvery blond to light brown hair that is unmanageable and does not lay flat on the head (A and B).

demonstrate this manifestation. In our patient, 10 hairs were cut and submitted for scanning electron microscope examination, which revealed the presence of triangular hair shafts in cross-section (Figure 2A) as well as a longitudinal groove along the entire length of the hair shaft (Figure 2B).

There is some evidence to suggest that the administration of biotin can increase strength, decrease scaling, and accelerate the growth rate of

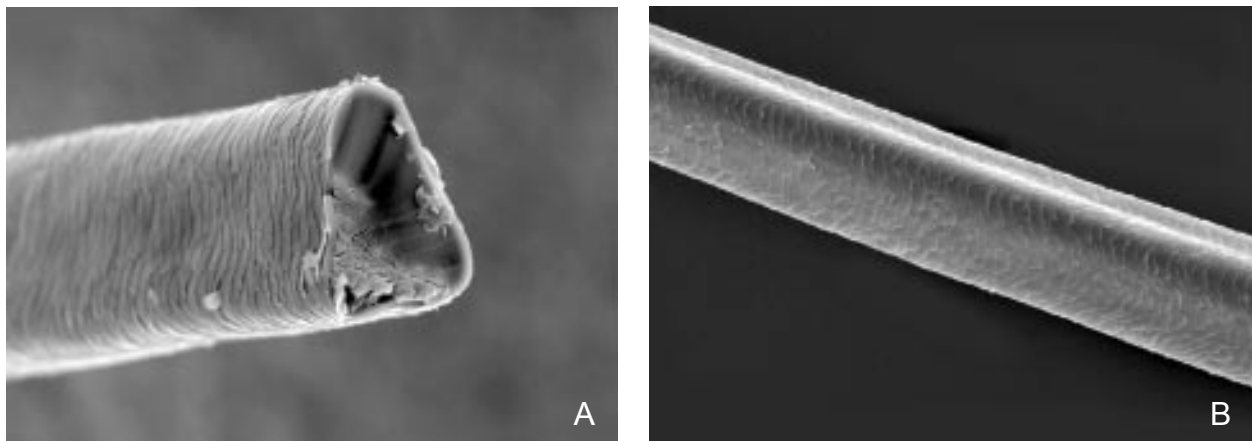


Figure 2. Scanning electron microscope examination revealed the characteristic presence of triangular hair shafts in cross-section (A) and a longitudinal groove along the entire length of the hair shaft (B).

uncombable hair; however, there is no definitive treatment.⁴ Fortunately, the manageability of the hair may gradually improve with time.²

REFERENCES

1. Dupre A, Rochiocioli P, Bonafe JL. Cheveux incoiffables: anomalies congenitale de cheveux. *Bull Soc Fr Dermatol Syphiligr.* 1973;80:111-112.
2. McCullum N, Sperling LC, Vidmar D. The uncombable hair syndrome. *Cutis.* 1990;46:479-483.
3. Hicks J, Metry DW, Barrish J, et al. Uncombable hair (chevaeux incoiffables, pili trianguli et canaliculi) syndrome: brief review and role of scanning electron microscopy in diagnosis. *Ultrastruct Pathol.* 2001;25:99-103.
4. Shelley WB, Shelley ED. Uncombable hair syndrome: observations on response to biotin and occurrence in siblings with ectodermal dysplasia. *J Am Acad Dermatol.* 1985;13:97-102.
5. Garty B, Metzker A, Mimouni M, et al. Uncombable hair: a condition with autosomal dominant inheritance. *Arch Dis Child.* 1982;57:710-712.
6. Lee AJ, Maino KL, Cohen B, et al. A girl with loose anagen hair syndrome and uncombable, spun-glass hair. *Pediatr Dermatol.* 2005;22:230-233.
7. Fritz TM, Trüeb RM. Uncombable hair syndrome with angel-shaped phalango-epiphyseal dysplasia. *Pediatr Dermatol.* 2000;17:21-24.
8. Wagner AM, Cunningham BB. Uncombable hair syndrome: light microscopy diagnosis. *Pediatr Dermatol.* 2005;22:369-370.