

# Porphyria Cutanea Tarda Presenting as Scleroderma

Raquel Zemtsov; Alexander Zemtsov, MD, MSc

*Sclerodermatous skin changes were observed in a patient with porphyria cutanea tarda (PCT) who initially was diagnosed as having progressive systemic sclerosis (PSS). In extremely rare circumstances, patients with PCT initially are misdiagnosed as having generalized morphea, or PSS, because they lack the typical skin findings of PCT, such as blisters, skin fragility, scarring on the dorsal aspects of the hands, and facial hypertrichosis. However, even in cases of PCT that clinically mimic and are misdiagnosed as PSS, the sclerodermatous skin changes primarily occur in v-shaped areas of the neck. Our patient had sclerodactyly with fingertip ulcerations as well as the classic facial features and skin tightness of PSS. Upon initiation of therapeutic phlebotomy, fingertip ulcerations and sclerodactyly resolved, and there was a notable improvement of sclerodermatous skin changes of the face and forearms.*

*Cutis.* 2010;85:203-205.

## Case Report

In April 2003 an ophthalmologist evaluated a 56-year-old man for the occlusion of a lacrimal duct and noted typical skin changes of scleroderma. The patient was referred to our dermatology service. He reported that the skin changes began approximately 18 months earlier. At a recent family reunion, family members who had not seen him in the last 2 years did not recognize him. His chief concerns were stiff fingers and skin tightness. Upon physical examination,

he had sclerodactyly but no irregular dilated nail fold capillary loops. The facial skin was thickened and tight and the face was expressionless (Figure 1), but no telangiectasia was present. The patient had completely lost his scalp hair, and the skin on his face, arms, and chest showed dyspigmentation (Figure 2). The patient denied difficulty swallowing or breathing. He did not have Raynaud phenomenon. He had not been exposed to any chemical or vibratory stimuli. His medical history was unremarkable, and he was not on any medications. However, the patient admitted to having an alcohol addiction. Test results for antinuclear antibodies and anti-Scl-70 antibodies were negative. Results of a skin biopsy showed diffuse superficial and dermal sclerosis (Figure 3), and 2 dermatopathologists diagnosed these histologic changes as scleroderma. Results of blood chemistry tests showed elevated aspartate aminotransferase at 108 U/L (reference range, 0–39 U/L) and alanine aminotransferase at 93 U/L (reference range, 0–40 U/L); elevated erythrocyte sedimentation rate at 34 mm/h (reference range, 0–21 mm/h); a negative rheumatoid factor; and a normal, clear yellow in color urinalysis. The patient was referred to a rheumatologist who confirmed the diagnosis of progressive systemic sclerosis (PSS). Results of pulmonary function tests, echocardiogram, and gastrointestinal motility studies showed no internal involvement.

A few months later, the patient developed severe chondrodermatitis nodularis chronica helices and ulcers on the fingertips of both hands. However, except for his severe skin disease, he said he felt fine and declined any systemic therapy, including penicillamine or aminobenzoate potassium. At the patient's request he obtained additional consultation from a dermatology service at the University of Cincinnati, Ohio, in May 2004 that confirmed the diagnosis of diffuse scleroderma. A rheumatologist at the Mayo Clinic in Rochester, Minnesota, also evaluated him and again verified the diagnosis of PSS. In July 2004, the patient suddenly developed blisters on the dorsal surfaces of both hands. A 24-hour

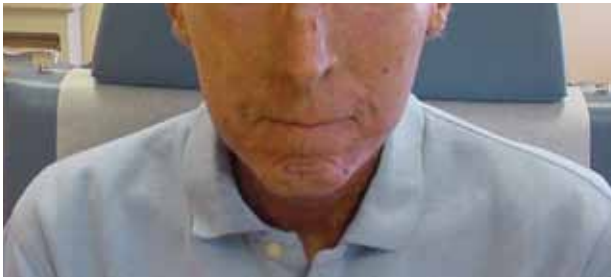---

From the University Dermatology Center, PC, Muncie, Indiana.

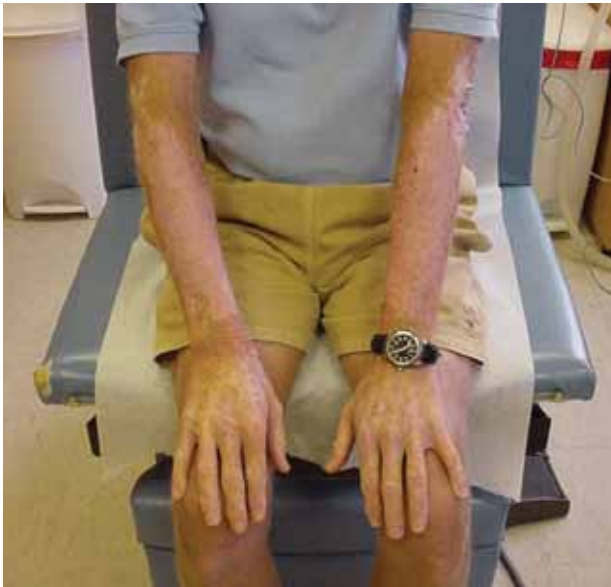Dr. A. Zemtsov also is from the Department of Dermatology, Indiana University School of Medicine, Indianapolis.

The authors report no conflict of interest.

Correspondence: Alexander Zemtsov, MD, MSc, University Dermatology Center, PC, 2525 University Ave, Ste 402, Muncie, IN 47303 (azemtsov@iupui.edu).

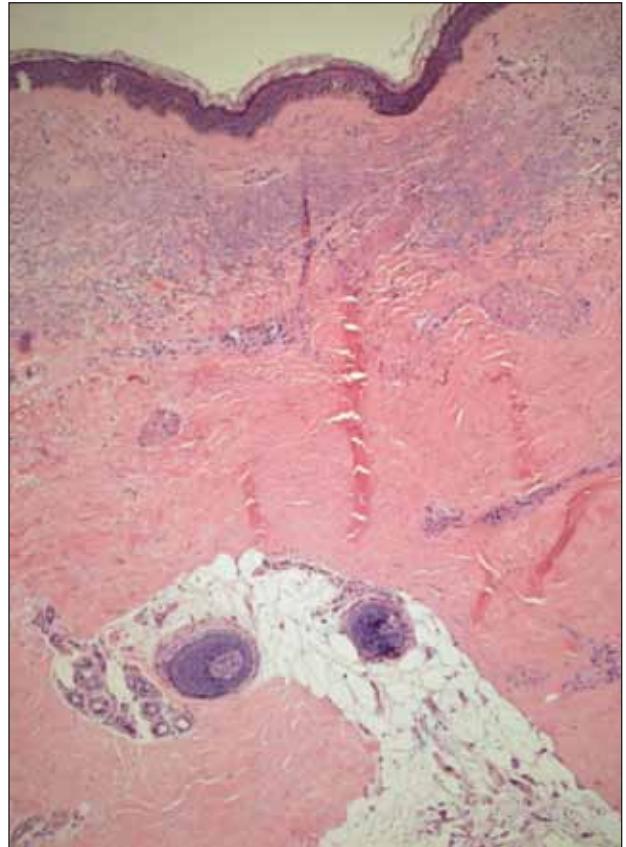


**Figure 1.** Facial skin was thickened, shiny, and tight. The face was expressionless and generalized alopecia was present.



**Figure 2.** Sclerodermatous skin changes on the forearms. The skin biopsy was taken from this area.

urine porphyrin collection showed the following: uroporphyrin, 4028  $\mu\text{g}/24\text{ h}$  (reference range,  $<20\text{ }\mu\text{g}/24\text{ h}$ ), heptacarboxyporphyrin, 3921  $\mu\text{g}/24\text{ h}$  (reference range,  $<13\text{ }\mu\text{g}/24\text{ h}$ ), pentacarboxyporphyrin, 508  $\mu\text{g}/24\text{ h}$  (reference range,  $<5\text{ }\mu\text{g}/24\text{ h}$ ), and coproporphyrin, 192  $\mu\text{g}/24\text{ h}$  (reference range,  $<110\text{ }\mu\text{g}/24\text{ h}$ ). Direct immunofluorescence of the involved skin from the dorsal aspect of a hand showed IgG, IgA, IgM, C3, and fibrinogen vascular staining. Results of a routine skin biopsy of a blister were diagnostic of porphyria cutanea tarda (PCT). The patient was sent to the dermatology grand rounds at the Indiana University School of Medicine, Indianapolis, where he was examined and evaluated, and the diagnosis of PCT was confirmed. The patient stated in retrospect that his urine was occasionally burgundy in color during the last 2 to 3 years.



**Figure 3.** Results of a skin biopsy revealed diffuse sclerosis and destruction of adnexal architecture in addition to solar elastosis (H&E, original magnification  $\times 40$ ).

Therapeutic phlebotomy was initiated and rapid resolution of the blisters occurred. The chondrodermatitis nodularis chronica helices and fingertip ulcers began healing, and in the following years, the skin on his hands became softer and less tight, with a dramatic improvement in his ability to grip. The patient also claimed to have substantially decreased alcohol consumption, and his liver enzyme levels currently are within reference range. His urine is now consistently normal in color, and the tightness in his face has somewhat improved.

### Comment

Sclerodermatous skin changes in patients with PCT that are clinically confused with PSS have occasionally been reported in the dermatology literature.<sup>1-3</sup> However, in the majority of these cases, characteristic skin features of PCT such as skin bullae, scarring, and hypertrichosis also are present and can be easily distinguished from PSS.<sup>1</sup> Furthermore, sclerodermatous skin changes have been described in patients with erythropoietic protoporphyria,<sup>4</sup> hepatoerythropoietic porphyria,<sup>5</sup> and variegate porphyria.<sup>6</sup>

However, most patients with porphyria and cutaneous sclerosis have PCT.<sup>6</sup> There is a direct relationship between the severity of sclerodermatous skin changes and the urine uroporphyrin levels; moreover, the degree of improvement in sclerodermatous skin changes, as in the case presented here, often is proportional to the reduction of the urine uroporphyrin levels.<sup>6</sup> Sclerodermatous skin changes on the scalp, as in our case, are associated with scarring alopecia.<sup>7</sup>

The sclerodermatous plaques of PSS and PCT cannot be distinguished by either light or electron microscopy.<sup>8</sup> The mechanism of the development of sclerodermatous skin changes in patients with PCT is unknown.<sup>3</sup> Some authors speculate that these changes are caused by porphyrin-induced direct phototoxic damage.<sup>9</sup> On the other hand, investigators believe that these sclerodermatous skin changes are produced by the uroporphyrin I stimulation of fibroblast-induced collagen biosynthesis.<sup>9,10</sup> Fibroblast-induced collagen biosynthesis can occur in the dark, explaining the production of sclerosis in areas not exposed to light.

A retrospective review of medical records of all PSS and PCT cases between 1950 and 1982 from the Mayo Clinic, Rochester, Minnesota, revealed that of 716 patients with PCT, 15 had sclerodermatous skin changes. However, in only 3 of 15 patients, the cutaneous findings of PCT were not apparent during the initial clinical evaluation.<sup>6</sup> As in our case, most patients with PCT with sclerodermatous skin changes have elevated liver enzymes and a history of alcohol abuse.<sup>1,2,6,9</sup> In all of the patients with PCT and sclerodermatous skin findings reported in the dermatology literature, there was no systemic involvement, Raynaud phenomenon, or presence of antinuclear antibodies, to the best of our knowledge. Furthermore, the sclerodermatous skin changes in these patients with PCT occur predominantly in v-shaped areas of the neck.<sup>7</sup> Our patient is unique because he had fingertip ulcerations and sclerodactyly. In the rheumatology literature, Panda et al<sup>11</sup> reported a patient with PCT who abused alcohol and had sclerodactyly and multiple amputations caused by fingertip ulcerations. He also had Raynaud phenomenon and antinuclear antibodies. However, this patient was diagnosed as having overlap PSS-PCT disease, even though he had minimal systemic involvement.<sup>11</sup> Other cases of overlap

PSS-PCT disease have been reported in the literature.<sup>12,13</sup> However, because of the extremely rare coexistence of these 2 diseases, these conditions probably are not pathophysiologically related.<sup>6</sup>

## Conclusion

Any patient with PSS-like skin changes without notable systemic involvement and antinuclear antibodies should be evaluated for the presence of PCT, especially if the patient has a history of alcohol abuse and elevated liver enzymes.

## REFERENCES

1. Castanet J, Lacour JP, Perrin C, et al. Sclerodermatous changes revealing porphyria cutanea tarda. *Acta Derm Venereol.* 1994;74:310-311.
2. Goh CL. Porphyria cutanea tarda simulating scleroderma. *Singapore Med J.* 1987;28:83-88.
3. Wilson PR. Porphyria cutanea tarda with cutaneous "scleroderma" and calcification. *Australas J Dermatol.* 1989;30:93-96.
4. Findlay GH, Scott PP, Cripps DJ. Porphyria and lipid proteinosis: a clinical, histological and biochemical comparison of 19 South African cases. *Br J Dermatol.* 1966;78:69-80.
5. Simon N, Berkó G, Schneider I. Hepato-erythropoietic porphyria presenting as scleroderma and acrosclerosis in a sibling pair. *Br J Dermatol.* 1977;96:663-668.
6. Friedman SJ, Doyle JA. Sclerodermoid changes in porphyria cutanea tarda: possible relationship to urinary uroporphyrin levels. *J Am Acad Dermatol.* 1985;13:70-74.
7. Doyle JA, Friedman SJ. Porphyria and scleroderma: a clinical and laboratory review of 12 patients. *Australas J Dermatol.* 1983;24:109-114.
8. Grossman ME, Poh-Fizpatrick MP. Porphyria cutanea tarda: diagnosis, management and differentiation from other hepatic porphyrias. *Dermatol Clin.* 1986;4:297-309.
9. Stevens HP, Ostlere LS, Black CM, et al. Generalized morphea secondary to porphyria cutanea tarda. *Br J Dermatol.* 1993;129:455-457.
10. Varigos G, Schiltz BR, Bickers DR. Uroporphyrin I stimulation of collagen biosynthesis in human skin fibroblasts: a unique dark effect of porphyrin. *J Clin Invest.* 1982;69:129-135.
11. Panda M, Meduri B, Enzenauer RJ. Porphyria cutanea tarda and scleroderma. *J Clin Rheumatol.* 2004;10:287-288.
12. Koczard E. Some clinical and pathogenic problems of porphyria. *Australas J Dermatol.* 1966;8:206-215.
13. Palmer AE. Scleroderma with porphyria cutanea tarda. *Cutis.* 1978;22:615-616.