

Sorafenib-Associated Psoriasiform Skin Changes

To the Editor:

As the use of new biologic agents becomes more common, associated cutaneous side effects warrant consideration. Multikinase inhibitors cause rashes including anaphylaxis, papulopustular eruptions, paronychia, xerosis, and telangiectases. Gefitinib, the inhibitor of the epidermal growth factor receptor tyrosine kinase, is the only multikinase inhibitor reported to cause psoriatic exacerbation.¹ Sorafenib was developed as a *raf* kinase inhibitor but is now known to also inhibit vascular endothelial growth factor receptors 1, 2, and 3, and platelet-derived growth factor receptor β . Sorafenib is US Food and Drug Administration approved for the treatment of unresectable hepatocellular carcinoma and advanced renal cell carcinoma; it is under investigation for stage III and stage IV melanoma. Dermatologic side effects of sorafenib include facial dermatitis, hand-foot skin reaction, and other nonspecific reactions that generally do not require treatment discontinuation.² We report sorafenib-associated psoriatic skin changes.

Case Report

A 56-year-old man with a history of hepatitis C virus, hepatocellular carcinoma, and psoriasis presented to our dermatology clinic with pustules and plaques on his dorsal hands of 1 year's duration (Figure 1). The patient had a 20-year history of plaque psoriasis involving his elbows, knees, legs, and back. After 1 month of sorafenib therapy, pustules and plaques developed on his dorsal hands. He reported no hand eruptions prior to sorafenib use. The patient reported that he self-discontinued sorafenib and hand lesions cleared within 1 month. He was then restarted on a lower dose, which resulted in fewer hand lesions than the first time. The patient was not taking any medications that would have exacerbated psoriasis and he denied any tobacco use. Elbow and leg lesions responded well to medium-potency topical steroids and phototherapy; however, the hand eruption was refractory to treatment.

Biopsy of an elbow plaque showed confluent parakeratosis with Munro microabscesses and psoriasiform epidermal hyperplasia with broad-based rete ridges, all consistent with classic psoriasis. The lesions on the dorsal hand demonstrated parakeratosis, psoriasiform epidermal hyperplasia

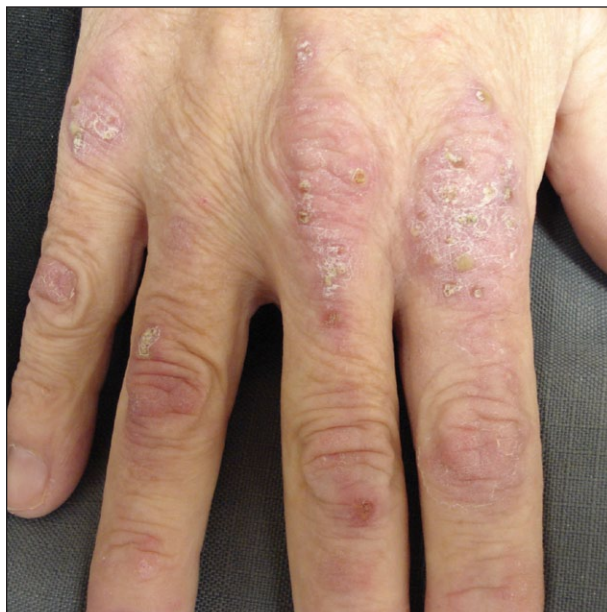

Figure 1. Right dorsal hand with pink plaques with minimal scale and pustules.

with broad-based rete ridges, and few neutrophilic micropustules (Figure 2). For the patient's hand lesions, the differential diagnosis included psoriasis exacerbation versus a psoriasiform drug eruption. It was possible that the hand reaction was due to irritation and a subsequent Köbner phenomenon, which seemed less likely than our proposed diagnoses.

Comment

We cannot definitively determine if the patient's hand lesions were due to a sorafenib-induced psoriasis exacerbation or psoriasiform drug eruption. The patient reported a direct correlation between starting sorafenib and appearance of hand lesions. Pathology was not consistent with literature reports of the common sorafenib-associated hand-foot skin reaction,³ which is characterized by symmetric, tender, erythematous areas on the palms and soles that are worsened by friction and heat exposure and associated with numbness or tingling.⁴ Histology showed epidermal parakeratosis and dyskeratosis as well as a dermal perivascular lymphocytic infiltrate.³

There is a lack of understanding of the pathogenesis of tyrosine kinase inhibitor-associated

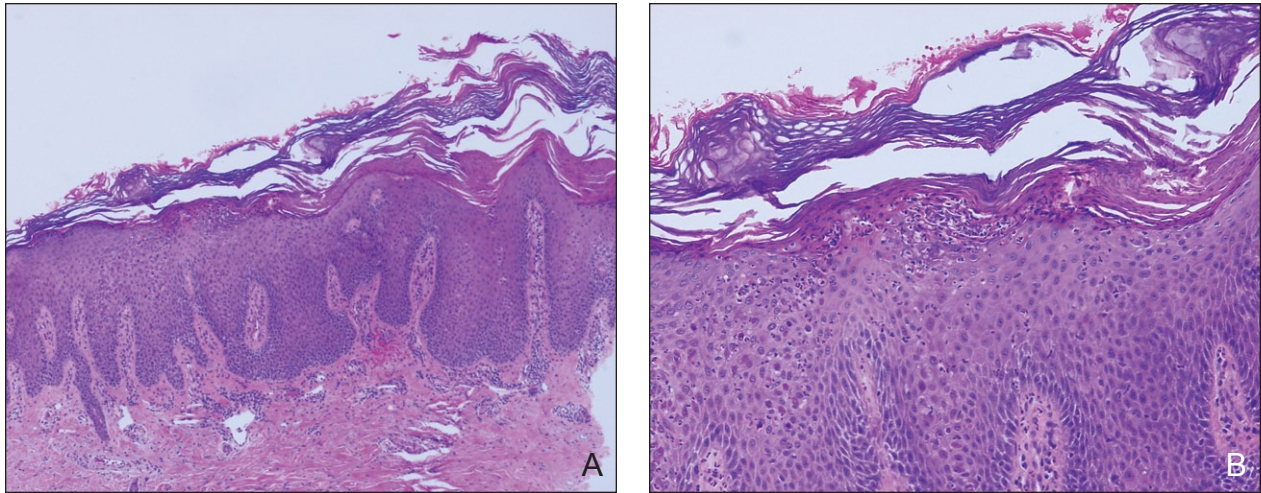


Figure 2. Shave biopsy from the dorsal hand showing parakeratosis, psoriasiform epidermal hyperplasia with broad-based rete ridges, and few neutrophilic micropustules (A and B)(H&E; original magnifications $\times 10$ and $\times 40$, respectively).

cutaneous reactions. Future research and reports of instructive clinical cases will enhance knowledge about these medications.

Sincerely,
Vivian Laquer, MD
Los Angeles, California

Nazanin Saedi, MD
Frank Dann, MD
Kristen Kelly, MD
Irvine, California

The authors report no conflict of interest.

REFERENCES

1. Heidary N, Naik H, Burgin S. Chemotherapeutic agents and the skin: an update. *J Am Acad Dermatol.* 2008;58:545-570.
2. Ratain MJ, Eisen T, Stadler WM, et al. Phase II placebo-controlled randomized discontinuation trial of sorafenib in patients with metastatic renal cell carcinoma. *J Clin Oncol.* 2006;24:2505-2512.
3. Autier J, Escudier B, Wechsler J, et al. Prospective study of the cutaneous adverse effects of sorafenib, a novel multikinase inhibitor. *Arch Dermatol.* 2008;144:886-892.
4. Robert C, Mateus C, Spatz A, et al. Dermatologic symptoms associated with the multikinase inhibitor sorafenib. *J Am Acad Dermatol.* 2009;60:299-305.