

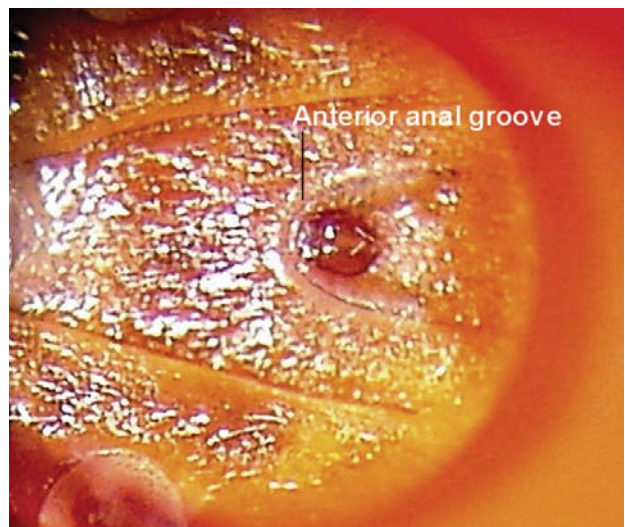
# What's Eating You? *Ixodes* Ticks

Roger Kapoor, MD, MBA; Dirk M. Elston, MD

**I***xodes* ticks can be recognized by their hard, inornate, dorsal scutum (shell); anterior-facing mouthparts; lack of eyes; and ventral anterior anal groove in the shape of an upside-down U (Figure 1).<sup>1</sup> Female ticks have a small scutum, allowing the abdomen to massively expand during a blood meal (Figure 2).

Perhaps the best-known *Ixodes* tick is *Ixodes scapularis* (formerly *Ixodes dammini*). Also commonly referred to as the deer tick or black-legged tick, it is characterized by its brown teardrop-shaped body. However, when engorged, the female tick's abdomen becomes filled with blood. The tick can be recognized by its large, soft, cream-colored, blood-filled abdomen (Figure 3).

In the United States, *Ixodes* ticks serve as vectors for 3 main diseases: Lyme disease (LD), babesiosis, and human granulocytic anaplasmosis (HGA) (formerly human granulocytic ehrlichiosis).<sup>2</sup> The vector varies according to geography. For example, *I. scapularis* is the main vector of Lyme disease in the mid-Atlantic states, the Great Lakes region, and the northeastern United States, while *Ixodes ricinus* (also known as the sheep tick) mainly is found in Europe. The major vector for Lyme disease in the western United States is *Ixodes pacificus* (the California black-legged tick). *Ixodes* ticks are well-adapted to a variety of environments from coastal shorelines to New York City parks.<sup>3</sup> Migrating birds may contribute to the wide geographic territory covered by the tick. Larval and nymphal stages of the tick attach to birds in the spring and summer,<sup>4</sup> and robins have been shown to be competent hosts for the Lyme spirochete. Another common bird,



**Figure 1.** *Ixodes* ticks have a characteristic anterior anal groove.

the yellowthroat, also has been reported as a competent reservoir,<sup>5</sup> though infectivity remains more robust in mice than in birds, and the white-footed mouse plays an important role in maintenance of the disease.<sup>6,7</sup>

*Borrelia burgdorferi*, a spirochete, is found in Europe and North America. The range of tick vectors appears wider in the southern states than in other parts of the country.<sup>8</sup> *Borrelia burgdorferi* is one of the few bacteria with enzymes that utilize manganese instead of iron.<sup>9</sup> Disease manifestations range from erythema migrans to arthritis, cardiac disease, and neurologic disease.

Babesiosis is a malarialike illness caused by *Babesia*, which is thought to be the second most common blood parasite of mammals.<sup>10,11</sup> In the United States, the disease exists mostly in eastern Long Island, the barrier islands, Fire and Shelter Islands, and the islands off the coast of Massachusetts; it is occasionally referred to as “the malaria of the Northeast.”<sup>12</sup> As Lyme disease and babesiosis are transmitted by the same vector, they may occur together.

Dr. Kapoor is from the Department of Dermatology, Massachusetts General Hospital, Harvard Medical School, Boston. Dr. Elston is from the Departments of Dermatology and Laboratory Medicine, Geisinger Medical Center, Danville, Pennsylvania.


The authors report no conflict of interest.

The images are in the public domain.

Correspondence: Dirk M. Elston, MD, Departments of Dermatology and Laboratory Medicine, Geisinger Medical Center, 100 N Academy Ave, Danville, PA 17822 (dmelston@geisinger.edu).



**Figure 2.** Nonengorged (top) and engorged (bottom) female *Ixodes* ticks.



**Figure 3.** *Ixodes scapularis*.

Human granulocytic anaplasmosis is seen in the upper midwestern states and is characterized by increased serum hepatic transaminases, leukopenia, and thrombocytopenia in the context of an acute febrile illness.<sup>13</sup> The disease is caused by *Anaplasma phagocytophilum*, an intracellular bacterium that is transmitted by *Ixodes* ticks and also can be transmitted by *Dermacentor variabilis*.

The range of all of these diseases is expanding and bird migrations contribute to widely separated geographic hot spots. In one rural New Jersey county, 55% of 100 adult *I scapularis* ticks carried at least 1 disease (LD, 43%; babesiosis, 5%; and HGA, 17%). In fact, 10% of ticks carried more than 1 of the 3 diseases.<sup>14</sup> Additionally, it has been

shown that coinfection of LD, babesiosis, or HGA is common in individuals who are infected with 1 of the 3 diseases.<sup>15</sup>

Another important and potentially fatal disease, tick paralysis, is primarily caused by *Ixodes holocyclus* in Australia and *Dermacentor* ticks in the United States. Neurotoxins in the tick's saliva that seed the bloodstream during feeding are thought to be responsible for tick paralysis. Australian tick paralysis is an important cause of death among dogs. In the United States, the disease is commonly seen in humans and carries a mortality of greater than 10%, largely because *Dermacentor* ticks attach to the head and neck and are hidden by scalp hair. *Ixodes* ticks, however, attach to the upper trunk and proximal extremities and have been given the name shoulder tick. Once the tick is removed, the symptoms resolve, as the disease is induced by a tick toxin with a relatively short half-life.

Tick paralysis is treated by simple removal of the tick. Lyme disease is treated with doxycycline in adults and amoxicillin in children. Advanced disease may require intravenous ceftriaxone. Babesiosis is treated either with atovaquone plus azithromycin or clindamycin plus quinine.<sup>16</sup> Human granulocytic anaplasmosis is treated with doxycycline.

The decision to administer antibiotic prophylaxis after tick bites remains controversial. Risk stratification is important and should be based on whether a patient is from an area that is endemic to LD, if a tick is heavily engorged (a sign of prolonged attachment),<sup>17-19</sup> and accurate identification of *I scapularis*. Currently there are no studies examining the cost-benefit ratio of antibiotic prophylaxis in situations in which all such variables are present. In the right setting, even single-dose doxycycline administered within 72 hours after an *I scapularis* bite can reduce the risk for LD.<sup>20</sup> However, we generally prefer to provide the patient with a prescription to be filled at the first sign of disease, as most patients will never develop manifestations of disease and will not require antibiotic treatment.

## REFERENCES

1. Wu ML, Warren DJ, Jones VA. Ticked off: *Ixodes*. *Arch Pathol Lab Med*. 2000;124:925.
2. Malik A, Jameel MN, Ali SS, et al. Human granulocytic anaplasmosis affecting the myocardium. *J Gen Intern Med*. 2005;20:C8-C10.
3. Daniels TJ, Falco RC, Schwartz I, et al. Deer ticks (*Ixodes scapularis*) and the agents of Lyme disease and human granulocytic ehrlichiosis in a New York City park. *Emerg Infect Dis*. 1997;3:353-355.
4. Smith RP Jr, Rand PW, Lacombe EH, et al. Role of bird migration in the long-distance dispersal of *Ixodes dammini*, the vector of Lyme disease. *J Infect Dis*. 1996;174:221-224.

5. Anderson JF, Johnson RC, Magnarelli LA, et al. Involvement of birds in the epidemiology of the Lyme disease agent *Borrelia burgdorferi*. *Infect Immun*. 1986;51:394-396.
6. Richter D, Spielman A, Komar N, et al. Competence of American robins as reservoir hosts for Lyme disease spirochetes. *Emerg Infect Dis*. 2000;6:133-138.
7. Klich M, Lankester MW, Wu KW. Spring migratory birds (Aves) extend the northern occurrence of black-legged tick (Acari: Ixodidae). *J Med Entomol*. 1996;33:581-585.
8. Oliver JH Jr. Lyme borreliosis in the southern United States: a review. *J Parasitol*. 1996;82:926-935.
9. Wackett LP, Dodge AG, Ellis LB. Microbial genomics and the periodic table. *Appl Environ Microbiol*. 2004;70:647-655.
10. Herwaldt B, Persing DH, Pr cigout EA, et al. A fatal case of babesiosis in Missouri: identification of another piroplasm that infects humans. *Ann Intern Med*. 1996;124:643-650.
11. Hunfeld KP, Hildebrandt A, Gray JS. Babesiosis: recent insights into an ancient disease. *Int J Parasitol*. 2008;38:1219-1237.
12. Giannini AJ, Black HR, Goettsche RL. *Psychiatric, Psychogenic, and Somatopsychic Disorders Handbook: A Laboratory and Clinical Guide to the Medical Management of Emotional and Intellectual Pathology*. Garden City, NY: Medical Examination Publishing Co; 1978:86. Cited by: Schaller J, Blackwell R. *Babesia Update 2009: Routine and Advanced Testing Often Fail, Standard Treatments Do Not Cure*. Tampa, FL: Hope Academic Press; 2008.
13. Dumler JS. Is human granulocytic ehrlichiosis a new Lyme disease? review and comparison of clinical, laboratory, epidemiological and some biological features. *Clin Infect Dis*. 1997;25(suppl 1):S43-S47.
14. Varde S, Beckley J, Schwartz I. Prevalence of tick-borne pathogens in *Ixodes scapularis* in a rural New Jersey county. *Emerg Infect Dis*. 1998;4:97-99.
15. Mitchell PD, Reed KD, Hofkes JM. Immunoserologic evidence of coinfection with *Borrelia burgdorferi*, *Babesia microti* and human granulocytic *Ehrlichia* species in residents of Wisconsin and Minnesota. *J Clin Microbiol*. 1996;34:724-727.
16. Babesiosis treatment. Centers for Disease Control and Prevention Web site. <http://www.cdc.gov/babesiosis/treatment.html>. Updated May 5, 2009. Accessed September 5, 2010.
17. Yeh MT, Bak JM, Hu R, et al. Determining the duration of *Ixodes scapularis* (Acari: Ixodidae) attachment to tick-bite victims. *J Med Entomol*. 1995;32:853-858.
18. Falco RC, Fish D, Piesman J. Duration of tick bites in a Lyme disease-endemic area. *Am J Epidemiol*. 1996;143:187-192.
19. Sood SK, Salzman MB, Johnson BJ, et al. Duration of tick attachment as a predictor of the risk of Lyme disease in an area in which Lyme disease is endemic. *J Infect Dis*. 1997;175:996-999.
20. Nadelman RB, Nowakowski J, Fish D, et al; Tick Bite Study Group. Prophylaxis with single-dose doxycycline for prevention of Lyme disease after an *Ixodes scapularis* tick bite. *N Engl J Med*. 2001;345:79-84.