

Syringomas on the Buttocks: Case Report

Michelle L. Jackson, MD; Elan Newman, MD; Fern Nelson, MD; Laura Romero, MD; Sharon Jacob, MD

Syringomas are benign adnexal neoplasms of eccrine ductal origin. They are most commonly described in females and typically are located on the anterior surfaces of the body. Syringomas rarely are reported on other regions of the body, especially the buttocks. We present the case of a 62-year-old man with multiple asymptomatic syringomas of 40 years' duration on his buttocks as well as the upper anterior thighs, groin, malar cheeks, and periorbital areas. This case is unique in that the duration and distribution of the lesions are more extensive than other cases reported in the literature.

Cutis. 2010;86:259-260.

Case Report

A 62-year-old man presented with a persistent eruption on his buttocks of 40 years' duration. He denied any specific history of trauma or irritation to the area, and there was no family history of similar lesions. The patient had not been taking any medications at the onset of the eruption. The lesions had been stable in morphology, and aside from being a cosmetic concern, they were entirely asymptomatic.

Physical examination revealed multiple 2- to 4-mm reddish brown papules in a symmetric distribution over his upper anterior thighs, groin, and buttocks (Figure 1). Multiple 2- to 3-mm flesh-colored papules were present on the malar cheeks and periorbital areas. Results from a 4-mm punch biopsy of a papule on the left aspect of the buttocks demonstrated a well-circumscribed tumor restricted to the upper dermis. It consisted of small- and medium-sized ducts lined by 2 layers of cuboidal epithelium. Solid strands of basaloid cells also were present. The duct lumina were dilated, contained eosinophilic material, and occasionally demonstrated commalike tails (Figure 2).

From the University of California, San Diego.

The authors report no conflict of interest.

Correspondence: Michelle L. Jackson, MD, 12514 Montellano Terr, San Diego, CA 92130 (mlucerojackson@gmail.com).

Comment

Syringomas are benign adnexal neoplasms of eccrine ductal differentiation.¹⁻⁶ Four clinical variants have been described: localized, familial, Down syndrome associated, and a generalized form that includes both multiple and eruptive syringomas.^{3,4,6} The localized form is the most common, often presenting as 2- to 5-mm, firm, smooth, flesh-colored papules located on the lower eyelids.¹⁻⁶ Eruptive syringomas, a rare variant mostly described in females, present as successive crops of multiple yellow-brown papules over the anterior surfaces of the body.²⁻⁶

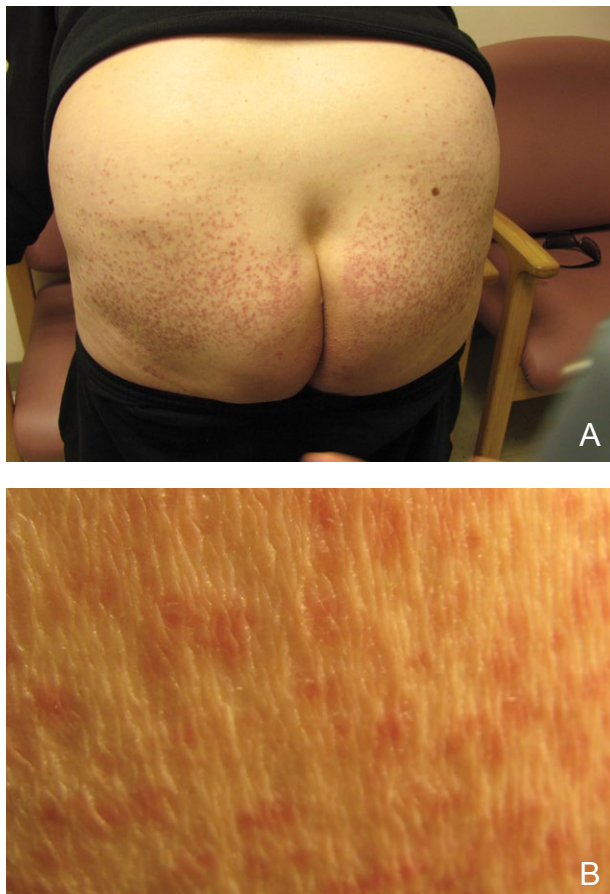


Figure 1. Multiple symmetric reddish brown papules on the buttocks (A and B).

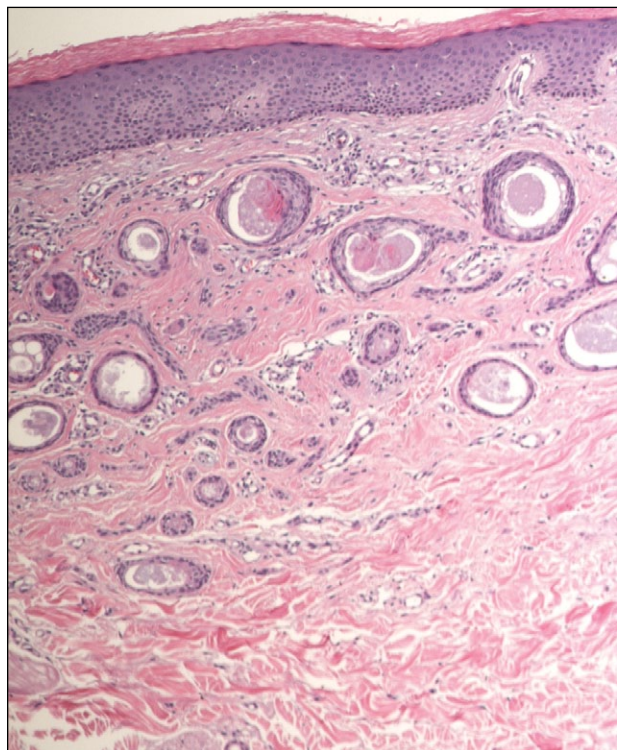


Figure 2. Small- and medium-sized ducts lined by 2 layers of cuboidal epithelium were present on histologic examination as well as solid strands of basaloid cells. The duct lumina were dilated, contained eosinophilic material, and demonstrated typical commalike tails (H&E, original magnification $\times 400$).

Rarely they have been reported on the scalp, penis, vulva, and perianal region.¹⁻⁶

Syringomas often are diagnosed based on clinical examination; however, histologic examination is required to establish a definitive diagnosis.³ Classically, syringomas consist of a superficial dermal proliferation of small comma-shaped ducts lined by 2 layers of cuboidal epithelium. A surrounding dense collagenous stroma with amorphous pale-staining material within the ductal lumen is typical.²⁻⁶

According to a PubMed search of articles indexed for MEDLINE using the terms *syringoma and buttocks* as well as *syringoma and gluteus*, only 3 cases of syringomas on the buttocks have been reported in the literature.¹⁻³ These cases detail a bilaterally symmetric, scattered, nonscaling, hyperpigmented papular eruption localized and limited to the buttocks.

Papules ranged in size from 3 to 10 mm but were otherwise asymptomatic. Patients ranged from 21 to 79 years of age, and lesions had been present from 2 months to 2 years prior to dermatologic evaluation. Unlike eyelid syringomas, buttock syringomas only have been described in male patients. The concomitant appearance of syringomas elsewhere on the body has not been previously reported, according to a PubMed search using the terms *syringoma, buttock, and eyelid*, as well as *syringoma, buttock, and periorbital*. The histology of buttock syringomas is identical to other variants of syringomas.¹⁻³

Our case is unique in both the distribution and persistence of the syringomas. In addition to the syringomas on his buttocks, our patient had syringomas present on his upper anterior thighs, groin, malar cheeks, and periorbital areas. Although his facial lesions were clinically typical of eyelid syringomas, they were morphologically different from the buttock lesions.

Despite their clinical variability, it appears that syringomas share common histologic architecture and may develop in more anatomical locations than classically described. With few cases reported to date, we suggest that buttock syringomas may represent a unique clinical variant of eruptive syringomas.

REFERENCES

1. Paquette DL, Massa MC. An unusual presentation of syringomas on the buttocks. *J Am Acad Dermatol.* 1998;39:1032-1033.
2. Loo WJ, Rytina E, Norris PG. Case 2. *Clin Exp Dermatol.* 2004;29:439-440.
3. Powell CL, Smith EP, Graham BS. Eruptive syringomas: an unusual presentation on the buttocks. *Cutis.* 2005;76:267-269.
4. Tsunemi Y, Ihn H, Saeki H, et al. Generalized eruptive syringoma. *Pediatr Dermatol.* 2005;22:492-493.
5. Taylor RS, Perone J, Kaddu S, et al. Appendage tumors and hamartomas of the skin. In: Wolff K, Goldsmith LA, Katz SI, et al, eds. *Fitzpatrick's Dermatology in General Medicine.* 7th ed. San Francisco, CA: The McGraw-Hill Companies, Inc; 2008:1068-1087.
6. McCarmont TH. Neoplasms of the skin: adnexal neoplasms. In: Bolognia JL, Jorizzo JL, Rapini RP, et al, eds. *Dermatology.* 2nd ed. New York, NY: Elsevier Limited; 2008:1693-1712.