

# Psoriasis Rupioides: A Rare Variant of a Common Disease

Małgorzata Salamon, MD, PhD; Anastazy Omulecki, MD, PhD; Anna Sysa-Jędrzejowska, MD, PhD; Daniel P. McCauliffe, MD; Anna Woźniacka, MD, PhD

*Psoriasis lesions typically are classified by their morphologic appearance and include plaque, guttate, pustular, and erythrodermic forms. Few review articles on psoriasis discuss the rare variant termed psoriasis rupioides. We report a case of psoriasis rupioides and discuss the unique features of this unusual form of psoriasis.*

*Cutis.* 2011;88:135-137.

**P**soriasis lesions typically are classified by their morphologic appearance and include plaque, guttate, pustular, and erythrodermic forms.<sup>1</sup> Psoriasis rupioides is a rare variant of psoriasis. A PubMed search of articles indexed for MEDLINE revealed only 2 reports of psoriasis rupioides and neither were in the English language.<sup>2,3</sup>

## Case Report

A 35-year-old man presented with a history of symmetrical disseminated red papules and plaques covered with thick scaly crusts of 2 months' duration with the greatest involvement on the palms and soles. Single, disseminated, circular lesions with visible stratification of concentric (ringlike) scale were present on the trunk, hands, and knees (Figures 1 and 2). Skin findings also included solitary red papules with silver scale and a positive Auspitz sign. Red papules with exudate also were noted in the axillae, groin, and anogenital region. Nail plates were yellowish and hyperkeratotic with mild onycholysis.

The patient denied symptoms of arthritis or dysuria. He had no family history of psoriasis. The differential diagnosis included hyperkeratotic variants of psoriasis, Bazex syndrome, ecthyma, secondary syphilis, and Reiter disease. A complete blood cell count revealed mild anemia, thrombocytopenia, and leukocytosis. Urinalysis, blood urea nitrogen, serum creatinine, aspartate aminotransferase, alanine aminotransferase, total bilirubin,  $\gamma$ -glutamyltranspeptidase, serum electrolytes, and blood glucose levels revealed no abnormalities. A urethral smear and culture were negative for white blood cells and bacteria. Human immunodeficiency virus, VDRL, and fluorescent treponemal antibody absorption tests were negative. Results of a skin biopsy confirmed the diagnosis of psoriasis (Figure 3).

Initially, desquamative ointment with 6% sulfur and salicylic acid was applied twice daily. When the scaly crusts came off, anthralin ointment in increasing concentrations was applied overnight and urea ointment 10% was used once daily in the morning. Psoralen plus UVA soak therapy was then introduced 3 times a week. After 3 weeks of intensive treatment, substantial clinical improvement was obtained.

## Comment

There are several rare, excessively hyperkeratotic forms of psoriasis, though there are only minor differences between them (rupioides, ostreaea, elephantine, and pseudocorneal subtypes).<sup>1,4</sup>

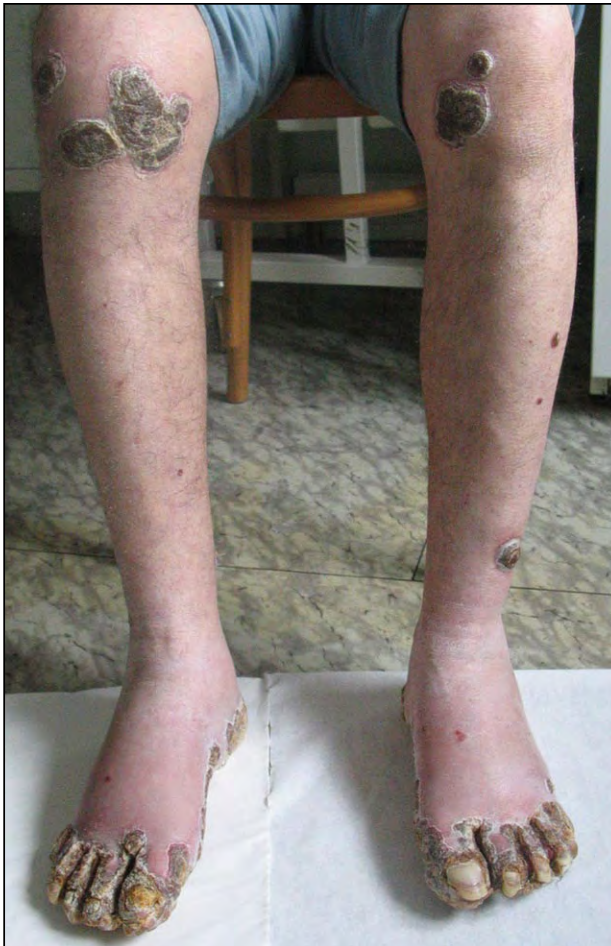The first, more precise descriptions of the rupioides and ostreaea variants of psoriasis were made by Polish dermatologist Marian Grzybowski in 1948.<sup>5</sup> He termed these variants *psoriasis exudativa*, with exudative crusts forming layers of lesions resembling rupia of secondary syphilis. Thick layers are caused by serous fluid. The lesions usually are extensive and resistant to therapy, often involving the palms, soles, and fingers. The nails also can be affected. It is a more severe type of psoriasis and arthritic manifestations are common.<sup>5</sup>

---

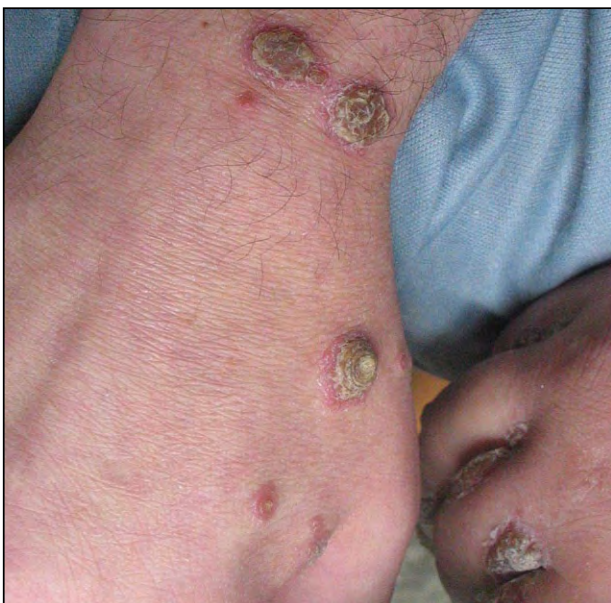Drs. Salamon, Omulecki, Sysa-Jędrzejowska, and Woźniacka are from the Department of Dermatology and Venereology, Medical University of Lodz, Poland. Dr. McCauliffe is from the Department of Dermatology, University of North Carolina, Chapel Hill, and private practice, Rutland, Vermont.

The authors report no conflict of interest.

Correspondence: Daniel P. McCauliffe, MD, 3 Mahoney Ave, Rutland, VT 05701 (dpmccauliffe@gmail.com).

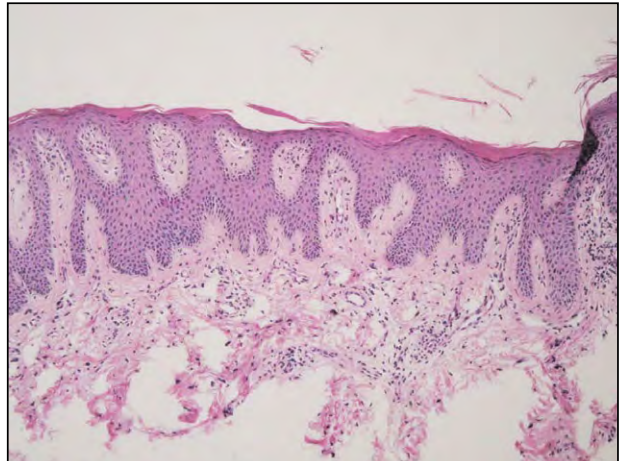


**Figure 1.** Plaques covered with thick adherent crusts on the legs and feet.

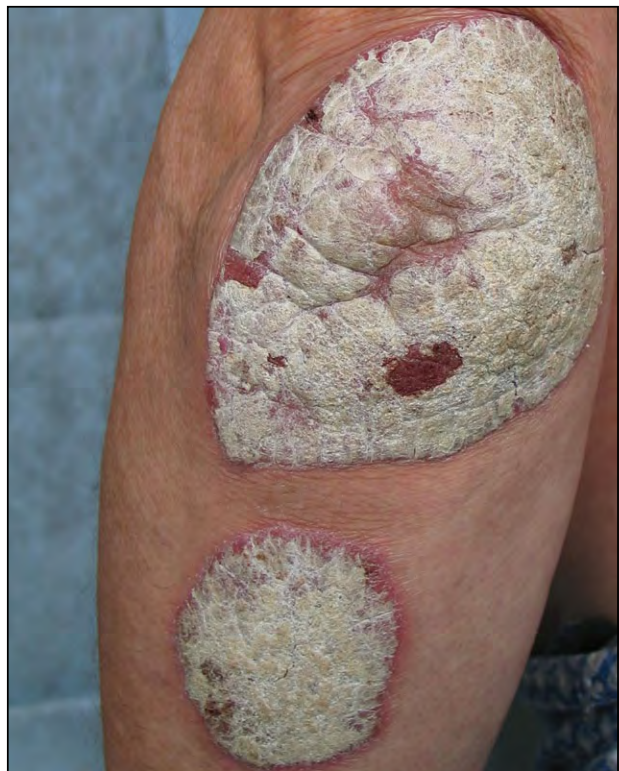

**Figure 2.** The classic appearance of conical ringlike crusts of psoriasis rupioides resembling the outer surface of a limpet shell.

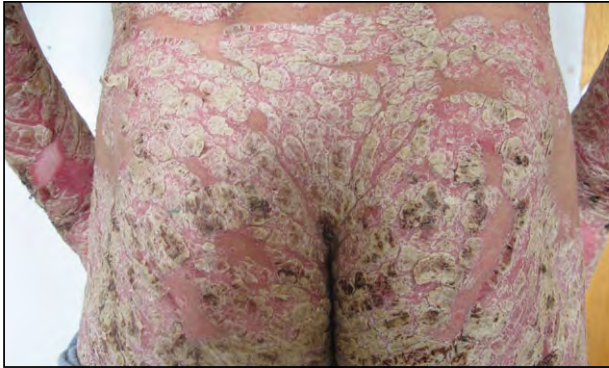In the 1960s, the differences between the rupioides and ostreacea variants were described.<sup>6,7</sup> The authors pointed out typical features of psoriasis ostreacea, including layers of visible scales, often in



**Figure 3.** Microscopic examination of a hematoxylin and eosin-stained specimen revealed epidermal thickening with wide rete ridges as well as elongated papillae of the dermis with elongated and enlarged vascular plexuses. Parakeratosis of the horny layer, atrophy of the granular layer, thickening of the spinous layer, and an increased number of mitotic divisions and neutrophils also were noted (original magnification  $\times 40$ ).



**Figure 4.** Psoriasis ostreacea with thick scale that typically takes on a concave appearance.



**Figure 5.** Elephantine psoriasis with large areas of involvement taking on the appearance of elephant skin.

various colors, with a very characteristic concave surface resembling an oyster shell (Figure 4). They drew distinctions between this form and the rupioides form, which consists of circular concentric layers of scale that create a cone (rupia) (Figure 2).<sup>5</sup> The clinical distinction between these psoriasis variants is now recognized.<sup>8,9</sup>

Another infrequent hyperkeratotic form of psoriasis is elephantine psoriasis, which is characterized by the presence of thick and flat, long-lasting, extensive plaques (Figure 5). Lesions typically are found on the back, upper limbs, and buttocks, and often are extensive.

Our case represents a rare and underappreciated form of psoriasis that may mimic other skin

conditions. A skin biopsy is useful in helping the clinician make the correct diagnosis.

**Acknowledgment**—This work was supported by a grant (#503-1152-1) from the Medical University of Lodz, Poland.

## REFERENCES

1. Griffiths CEM, Camp RDR, Barker JNWN. Psoriasis. In: Champion RH, Burton JL, Burns DA, et al, eds. *Textbook of Dermatology*. 6th ed. Boston, MA: Blackwell-Science; 1998:1589-1649.
2. Cvejić S, Milakov J. Psoriasis rupioides et verrucosa [in Serbian]. *Med Pregl*. 1967;20:167-169.
3. Golousenko I, Fadeeva VI, Omran A. Case of psoriasis rupioides with arthropathy [in Russian]. *Vestn Dermatol Venerol*. 1984;3:74-75.
4. Arias-Santiago SA, Naranjo-Sintes R. Images in clinical medicine. generalized ostraceous psoriasis. *N Engl J Med*. 2010;362:155.
5. Grzybowski M. *Diseases of the Skin: Handbook for Practitioners and Students*. Vol 2. Warsaw, Poland: Institute of Medical Science Publishing; 1948.
6. Ryll-Nardzawski C, Kudejko J. Psoriasis ostracea [in French]. *Ann Dermatol Syphiligr*. 1968;95:405-410.
7. Kudejko J. Psoriasis pseudocornea [in Polish]. *Przegl Dermatol*. 1965;52:271-274.
8. Estrada B, Azevedo P, Tamler C, et al. Comparative dermatology: hyperkeratotic psoriasis. *An Bras Dermatol*. 2007;82:369-371.
9. Bernardi C, Schwartz J, Lecompte S, et al. Psoriasis ostracea—case report. *An Bras Dermatol*. 2002;77:207-210.



### NEED MORE INFORMATION?

Access these related articles in our online archives at [www.cutis.com](http://www.cutis.com)

- ▾ Alcohol as a Risk Factor for Plaque-Type Psoriasis
- ▾ Psoriasis Guttata With Palmoplantar Involvement Clinically Mimicking Secondary Syphilis
- ▾ Successful Treatment of Recalcitrant Palmoplantar Psoriasis With Etanercept

Use our Advanced Search to find these articles and more online!