

An Unusual Presentation of Multiple Hidrocystomas

Jane Scribner, MD; Thomas D. Regan, MD; James W. Steger, MD

An 85-year-old man sought treatment of multiple nontender bluish papules of 3 years' duration on the forearms, forehead, and temples. On physical examination, blue-tinged, semitranslucent, dome-shaped papules were noted. Workup revealed multiple hidrocystomas. We discuss the findings in our patient and review the literature.

Cutis. 2011;88:178-181.

Case Report

We report an 85-year-old man who presented with multiple nontender bluish papules of 3 years' duration on the forearms, forehead, and temples (Figure 1). He stated that these papules waxed and waned, but he could not recall if they changed in size with perspiration. His medical history included hypertension, benign prostatic hypertrophy, actinic keratosis, and hypopituitarism. Thirty years prior he had undergone a hypophysectomy and radiation therapy for a pituitary adenoma. His medications included lisinopril, hydrochlorothiazide, tolterodine, cortisone, synthroid, and testosterone. Laboratory tests drawn a month prior to his visit revealed no abnormalities in the free serum thyroxine level.

On examination, he had 10 to 15 blue-tinged, semitranslucent, dome-shaped papules measuring approximately 4 mm in diameter on the bilateral forearms. Three similar lesions also were present on his forehead and temples.

A biopsy obtained from a lesion on the right forearm revealed a unilocular cystic space with 2 layers of cuboidal to flattened epithelium, consistent with a hidrocystoma. There was an absence of decapitation secretion and bulbous protrusions, suggesting the origin of the cyst was likely eccrine (Figure 2). Immunohistochemical studies were not performed.

Comment

Hidrocystomas are benign cystic tumors of the skin that originate from apocrine or eccrine secretory glands. Apocrine hidrocystomas have principally been reported as solitary lesions,¹ whereas eccrine hidrocystomas are at times further classified as either solitary (Smith type) or multiple (Robinson type). The classic multiple type of eccrine hidrocystomas was first described in 1893 by Robinson² in a large number of patients who had multiple lesions located around their periorbital and malar areas. These patients primarily were women who tended to work in hot humid environments.² In 1973, Smith and Chernosky³ described a group of patients who primarily exhibited solitary lesions with an equal distribution between males and females. Notably, the division of hidrocystomas into apocrine or eccrine is somewhat controversial because immunohistochemical stains have shown that the distinction is not always reliably made by light microscopy.^{1,4}

Both apocrine and eccrine hidrocystomas typically present as painless cysts that range in color from flesh toned to brown to bluish black. They are almost always found on the head and neck, especially on the eyelid and lateral canthus. Apocrine hidrocystomas often are darker in color and less likely to be periorbital.^{5,6} Apocrine hidrocystomas range in size from 3 to 15 mm. Eccrine hidrocystomas generally are smaller, but giant eccrine hidrocystomas have been reported.⁷ Multiple eccrine hidrocystomas often show a waxing and waning course and increase in size and number with exercise or exposure to heat and humidity.⁸ Apocrine hidrocystomas do not show similar variability in

Drs. Scribner and Steger are from Naval Medical Center, San Diego, California. Dr. Regan is from Wilford Hall Medical Center, Lackland Air Force Base, Texas.

The authors report no conflict of interest.

The views expressed in this article are those of the authors and do not reflect the official policy or position of the Department of the Navy, Department of Defense, or US Government.

Correspondence: Jane Scribner, MD, Naval Medical Center San Diego, 34800 Bob Wilson Dr, Ste 300, San Diego, CA 92134 (jane.scribner@med.navy.mil).

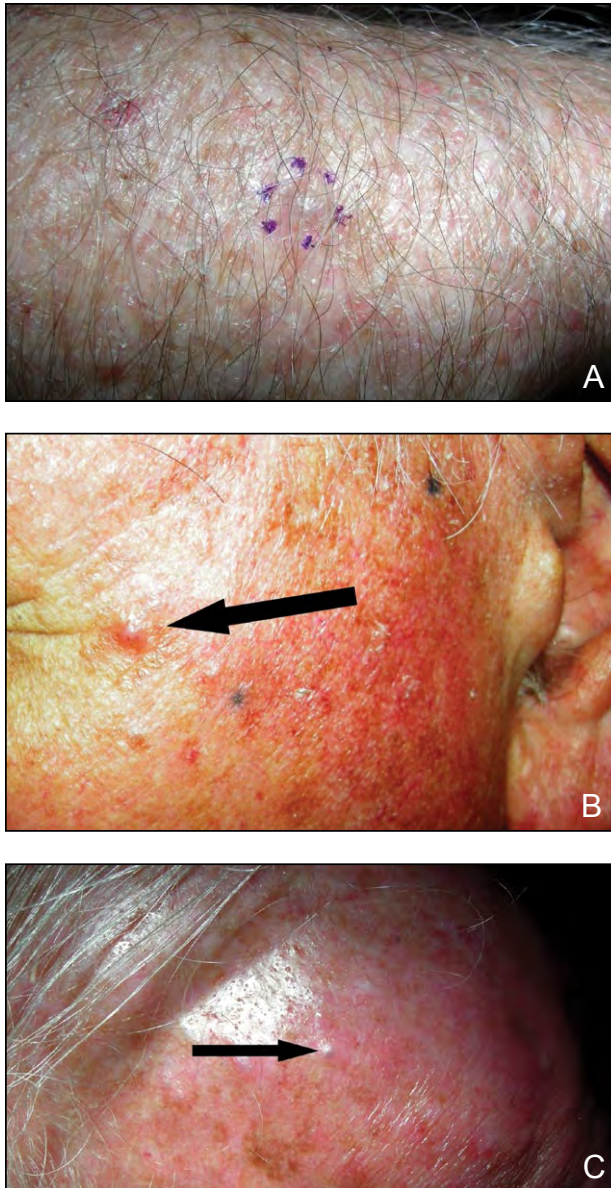


Figure 1. Nontender, bluish, semitranslucent, dome-shaped papule on the forearm (A), left temple (arrow)(B), and forehead (arrow)(C).

hot weather. It is thought that eccrine hidrocystomas result from dilatation of eccrine ducts, whereas apocrine hidrocystomas may result from dilatation of apocrine ducts or represent adenomas of apocrine sweat gland coils.^{1,9}

The clinical differential diagnosis for hidrocystomas includes epidermal inclusion cysts, cutaneous focal mucinosis, hemangiomas, blue nevi, syringomas, milia, melanoma, and pigmented-type cystic basal cell carcinomas.¹⁰ Because many of these lesions have a similar appearance on physical examination and carry different prognostic importance, biopsy of the lesions is essential for correct diagnosis.⁵

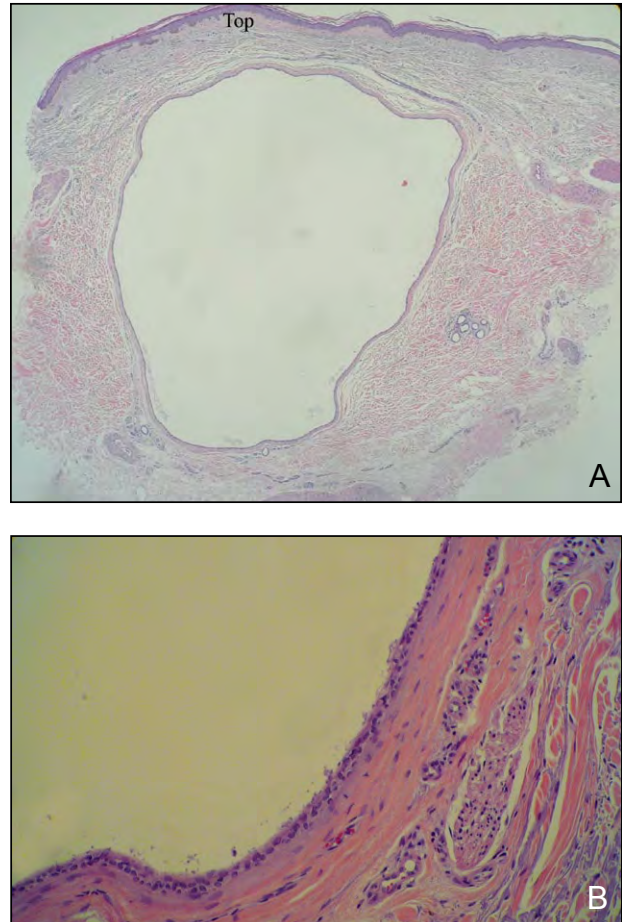


Figure 2. Unilocular cyst with 2 layers of cuboidal to flattened epithelium and absence of decapitation secretion and bulbous protrusions (A and B)(H&E; original magnifications $\times 40$ and $\times 200$, respectively).

Histologically, apocrine hidrocystomas appear as unilocular to multilocular cysts lined by 1 to several layers of cuboidal to columnar epithelial cells surrounded by perpendicularly oriented myoepithelial cells.¹¹ The luminal cells exhibit bulbous or papillary protrusions and luminal decapitation-type secretion. They are less frequently unilocular. Eccrine hidrocystomas, on the other hand, primarily are unilocular and lined by 2 layers of cuboidal or flattened epithelium.¹

Nevertheless, the classification of hidrocystomas as apocrine or eccrine is difficult and somewhat controversial. There are reports of hidrocystomas diagnosed as eccrine with light microscopy, only to have immunohistochemical studies reveal the expression of apocrine antigens.⁹ High intraluminal pressure within some apocrine hidrocystomas may cause their epithelial lining to become flattened, thus mimicking eccrine hidrocystomas in appearance.¹² Therefore, the definitive diagnosis

of apocrine versus eccrine hidrocystoma is best withheld until immunohistochemical studies have been performed.^{9,13}

The different histogenetic derivations of sweat gland systems allow for unique immunohistochemical stains to assist in classifying hidrocystomas. de Viragh et al⁹ examined 24 tissue samples previously diagnosed as either eccrine hidrocystoma or apocrine cystadenoma. The authors used human milk fat globulin 1, α -smooth muscle actin, and keratin markers to establish 3 separate categories of sweat gland tumors: eccrine hidrocystomas, apocrine hidrocystomas, and apocrine cystadenomas. Their results suggest that eccrine cystic tumors are of ductal origin (eccrine hidrocystomas), whereas apocrine cystic tumors may be either ductal (apocrine hidrocystomas) or derived from apocrine secretory coils (apocrine cystadenomas).⁹ Another study used S-100 protein that is found in the secretory cells of the eccrine sweat gland to show that cases of multiple eccrine hidrocystomas were S-100 protein negative, thus indicating ductal origin.⁴ Stains with anti-carcinoembryonic antigen have not been useful in differentiating between hidrocystomas.⁹

The few reported cases of multiple hidrocystomas have been limited to the head, neck, and axillae. Even reports of solitary hidrocystomas are limited to the head and neck with a few unusual presentations on the finger,¹⁴⁻¹⁶ rectum,¹⁷ pericoccygeal region,¹⁸ penis,^{19,20} vulva,¹³ and axilla²¹ (Table). The presentation of a hidrocystoma, single or multiple, involving the forearms is unusual.

Notably, multiple hidrocystomas may be markers of 2 rare inherited syndromes of ectodermal dysplasia: focal dermal hypoplasia (Goltz syndrome) and Schöpf-Schulz-Passarge syndrome.²¹ Schöpf-Schulz-Passarge syndrome is characterized by multiple eyelid hidrocystomas, hypodontia, hypotrichosis, palmo-plantar hyperkeratosis, and onychodystrophy. The pattern of inheritance of Schöpf-Schulz-Passarge syndrome is considered autosomal recessive, but sporadic cases have been reported.^{12,22} Characteristic cutaneous features of focal dermal hypoplasia, or Goltz syndrome, include atrophic linear hypopigmented or hyperpigmented patches, telangiectases, multiple papillomas of the skin, and anomalies of apocrine glands often manifesting as multiple hidrocystomas.²³ There also are numerous facial and skeletal abnormalities as well as cardiopulmonary, gastrointestinal tract, and genitourinary disorders. Goltz syndrome is considered an X-linked dominant trait.²⁴ Our patient had no other cutaneous findings suggestive of a larger syndrome. Multiple eccrine hidrocystomas have been reported in the setting of Graves disease.⁸ It is believed that the hyperhidrosis

Summary of Unusual Locations of Hidrocystomas

Location	Type	Reference
Finger	Apocrine	Numata et al ¹⁴ Santos-Juanes et al ¹⁵ De Fontaine et al ¹⁶
Rectum	No type	Erbay et al ¹⁷
Pericoccygeal region	Apocrine	Chin et al ¹⁸
Penis	Apocrine	Mataix et al ¹⁹ Samplaski et al ²⁰
Vulva	Eccrine	Kamishima et al ¹³
Axilla	Apocrine	Obaidat and Ghazarian ²¹

associated with hyperthyroidism causes subsequent sweat retention. In one reported case, correction of the thyroid values to within reference range caused rapid disappearance of the associated skin lesions.⁸

The treatment of hidrocystomas is challenging due to the cosmetic location and often large number of lesions present. Aggressive surgical removal may lead to considerable scarring, and individual puncture and drainage of the lesions is associated with a high rate of recurrence. Hyfrection or electrodesiccation has been used in treatment with some success.^{1,25} Pharmacologic therapy aimed at reducing sweat production with topical as well as systemic anticholinergics such as atropine, scopolamine, and glycopyrrolate has been utilized in treatment of multiple hidrocystomas,²⁵⁻²⁷ but these medications may cause anticholinergic side effects such as blurry vision and nausea.²⁵ Successful treatment with a 1450-nm diode laser²⁸ and a 585-nm pulsed dye laser²⁹ has been reported. However, not all reports of treatment with pulsed dye lasers have been successful.³⁰ Other investigational treatment modalities include trichloroacetic acid³¹ and botulinum toxin injection.³² Avoidance of hot and humid environments is therapeutic for many patients who exhibit seasonal variability in symptoms.

Conclusion

We report an unusual case of multiple hidrocystomas of the forearms. Although histologic examination suggests an eccrine origin, definitive classification is best reserved until after immunohistochemical examination.

REFERENCES

- Stone MS. Cysts. In: Bologna JL, Jorizzo JL, Rapini RP, eds. *Dermatology*. 2nd ed. Philadelphia, PA: Elsevier Inc; 2008:1681-1691.
- Robinson AR. Hidrocystoma. *J Cutan Genitourin Dis*. 1893;11:293-303.
- Smith JD, Chernosky ME. Hidrocystomas. *Arch Dermatol*. 1973;108:676-679.
- Tokura Y, Takigawa M, Inoue K, et al. S-100 protein-positive cells in hidrocystomas. *J Cutan Pathol*. 1986;13:102-110.
- Sarabi K, Khachemoune A. Hidrocystomas—a brief review. *MedGenMed*. 2006;8:57.
- Alfadley A, Al Aboud K, Tulba A, et al. Multiple eccrine hidrocystomas of the face. *Int J Dermatol*. 2001;40:125-129.
- Matsushita S, Higashi Y, Uchimiya H, et al. Case of giant eccrine hidrocystoma of the scalp. *J Dermatol*. 2007;34:586-587.
- Kim YD, Lee EJ, Song MH, et al. Multiple eccrine hidrocystomas associated with Graves' disease. *Int J Dermatol*. 2002;41:295-297.
- de Viragh PA, Szeimies RM, Eckert F. Apocrine cystadenoma, apocrine hidrocystoma, and eccrine hidrocystoma: three distinct tumors defined by expression of keratins and human milk fat globulin 1. *J Cutan Pathol*. 1997;24:249-255.
- Buckel TB, Helm KF, Ioffreda MD. Cystic basal cell carcinoma or hidrocystoma? the use of an excisional biopsy in a histopathologically challenging case. *Am J Dermatopathol*. 2004;26:67-69.
- Weedon D. Cysts, sinuses and pits. In: Weedon D, ed. *Skin Pathology*. 2nd ed. London, England: Churchill Livingstone; 2002:503-520.
- Hampton PJ, Angus B, Carmichael AJ. A case of Schöpf-Schulz-Passarge syndrome. *Clin Exp Dermatol*. 2005;30:528-530.
- Kamishima T, Igarashi S, Takeuchi Y, et al. Pigmented hidrocystoma of the eccrine secretory coil in the vulva: clinicopathologic, immunohistochemical and ultrastructural studies. *J Cutan Pathol*. 1999;26:145-149.
- Numata Y, Okuyama R, Sasai S, et al. Apocrine hidrocystoma on the finger. *Acta Derm Venereol*. 2006;86:188-189.
- Santos-Juanes J, Galache Osuna C, Sánchez Del Río J, et al. Apocrine hidrocystoma on the tip of a finger. *Br J Dermatol*. 2005;152:379-380.
- De Fontaine S, Van Geertruyden J, Vandeweyer E. Apocrine hidrocystoma of the finger. *J Hand Surg Br*. 1998;23:281-282.
- Erbay N, Kruskal JB, Kane RA. Rectal hidrocystoma. *J Ultrasound Med*. 2002;21:933-935.
- Chin SC, Chen CY, Zimmerman RA. Pericoccygeal hidrocystoma. *AJNR Am J Neuroradiol*. 1998;19:587-588.
- Mataix J, Bañuls J, Blanes M, et al. Translucent nodular lesion of the penis. apocrine hidrocystoma of the penis. *Arch Dermatol*. 2006;142:1221-1226.
- Samplaski MK, Somani N, Palmer JS. Apocrine hidrocystoma on glans penis of a child [published online ahead of print February 20, 2009]. *Urology*. 2009;73:800-801.
- Obaidat NA, Ghazarian DM. Bilateral multiple axillary apocrine hidrocystomas associated with benign apocrine hyperplasia. *J Clin Pathol*. 2006;59:779.
- Mallaiah U, Dickinson J. Photo essay: bilateral multiple eyelid apocrine hidrocystomas and ectodermal dysplasia. *Arch Ophthalmol*. 2001;119:1866-1867.
- Spitz JL. Focal dermal hypoplasia. In: Spitz JL, ed. *Genodermatoses: A Clinical Guide to Genetic Skin Disorders*. 2nd ed. Baltimore, MD: Lippincott Williams & Wilkins; 2005:133-167.
- Riyaz N, Riyaz A, Chandran R, et al. Focal dermal hypoplasia (Goltz syndrome). *Indian J Dermatol Venereol Leprol*. 2005;71:279-281.
- Lee MR, Ryman W. Multiple eccrine hidrocystomas. *Australas J Dermatol*. 2004;45:178-180.
- Sanz-Sánchez T, Daudén E, Pérez-Casas A, et al. Efficacy and safety of topical atropine in treatment of multiple eccrine hidrocystomas. *Arch Dermatol*. 2001;137:670-671.
- Smith DR, Mathias CG, Mutasim DF. Multiple eccrine hidrocystomas treated with glycopyrrolate. *J Am Acad Dermatol*. 2008;59(suppl 5):122S-123S.
- Echague AV, Astner S, Chen AA, et al. Multiple apocrine hidrocystoma of the face treated with a 1450-nm diode laser. *Arch Dermatol*. 2005;141:1365-1367.
- Tanzi E, Alster TS. Pulsed dye laser treatment of multiple eccrine hidrocystomas: a novel approach. *Dermatol Surg*. 2001;27:898-900.
- Choi JE, Ko NY, Son SW. Lack of effect of the pulsed-dye laser in the treatment of multiple eccrine hidrocystomas: a report of two cases. *Dermatol Surg*. 2007;33:1513-1515.
- Dailey RA, Saulny SM, Tower RN. Treatment of multiple apocrine hidrocystomas with trichloroacetic acid. *Ophthalm Plast Reconstr Surg*. 2005;21:148-150.
- Blugerman G, Schavelzon D, D'Angelo S. Multiple eccrine hidrocystomas: a new therapeutic option with botulinum toxin. *Dermatol Surg*. 2003;29:557-559.