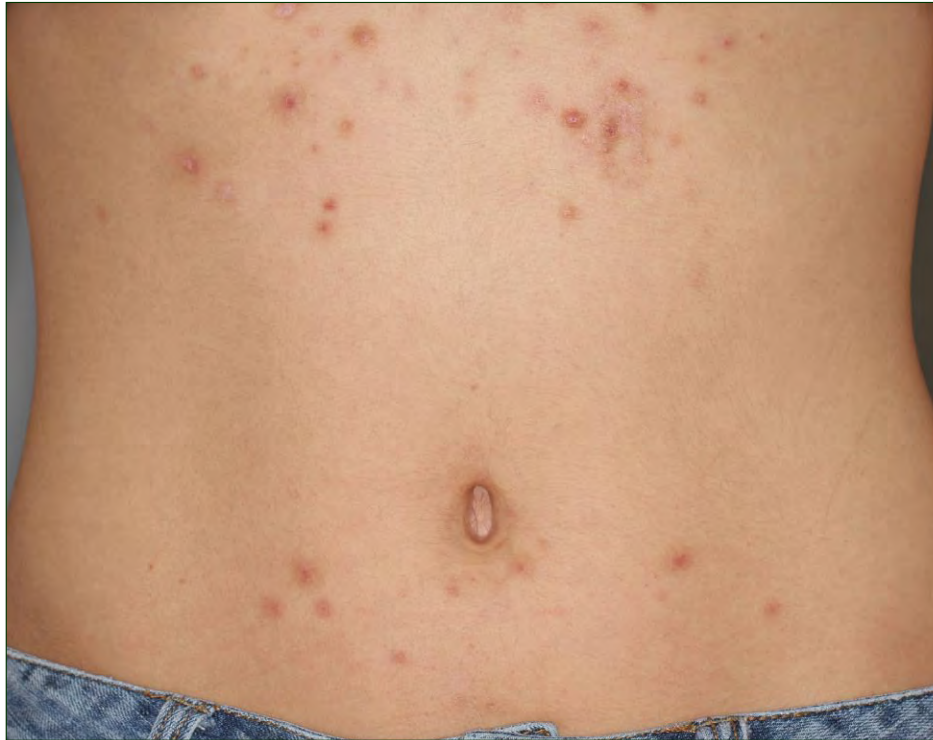

## What Is Your Diagnosis?



A 16-year-old otherwise healthy adolescent girl presented with painful papulopustules on the chest and around the axillae of 6 years' duration. She noted that thick material occasionally drained from the lesions. Her symptoms worsened despite being treated with topical antibiotics, benzoyl peroxide, triamcinolone, and a course of oral doxycycline. On examination, her upper abdomen and axillae had multiple red to brown papules, some with crusting, and several open comedonelike papules. A comedonelike papule was manually decompressed and the thick material was examined under potassium hydroxide. The rest of the cutaneous examination was normal.

PLEASE TURN TO PAGE 219 FOR DISCUSSION

Eric W. Hossler, MD; Maria I. Hicks, MD; Howard B. Pride, MD; Department of Dermatology, Geisinger Medical Center, Danville, Pennsylvania.

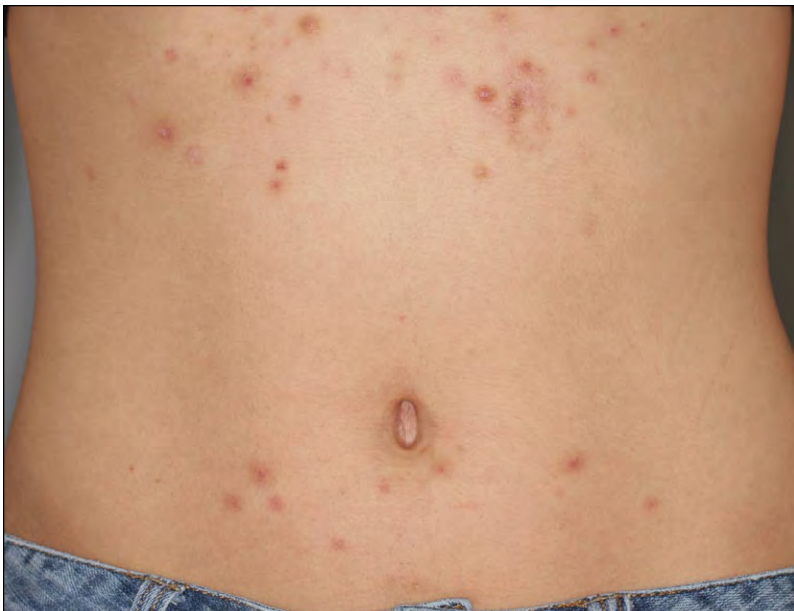The authors report no conflict of interest.

## The Diagnosis: Eruptive Vellus Hair Cysts

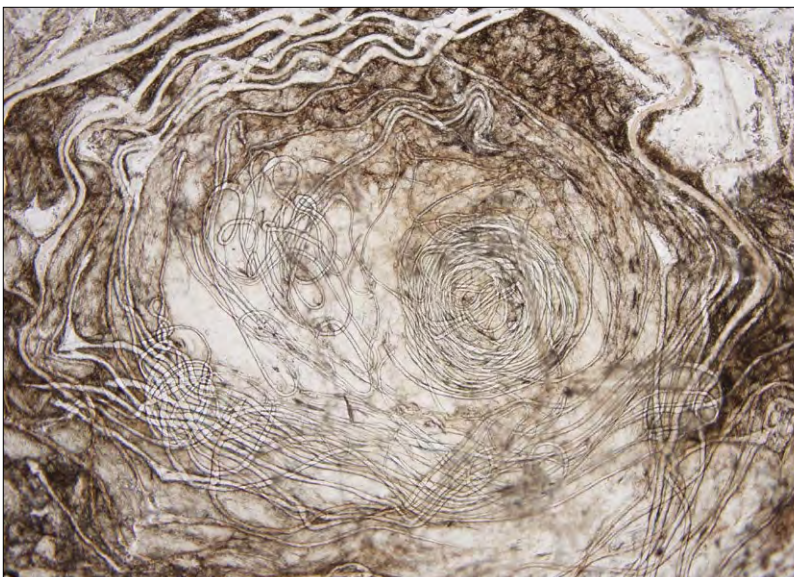
**E**ruptive vellus hair cysts are benign papules that appear in the second and third decades of life. First described in 1977,<sup>1</sup> they present as multiple 1- to 5-mm pink to hyperpigmented papules, often with central hyperkeratosis or crusting (Figure 1). Most cases present on the mid chest and proximal upper extremities; however, they can present periorbitally<sup>2</sup> or on the face mimicking Ota nevus.<sup>3</sup>

The cause of vellus hair cysts is unknown, but they can be inherited in an autosomal-dominant

manner.<sup>4-6</sup> Vellus hair cysts may be associated with renal failure,<sup>7</sup> pachyonychia congenita,<sup>8-10</sup> ectodermal dysplasia,<sup>11</sup> cardio-facio-cutaneous syndrome,<sup>12</sup> and Lowe syndrome.<sup>13</sup> There are many reports of vellus hair cysts occurring concurrently with steatocystoma multiplex, and there may be histologic overlap.<sup>14,15</sup> In one study of 64 cases of steatocystoma multiplex, 27 (42%) contained vellus hairs.<sup>14</sup> Patients with pachyonychia congenita may present with both lesions.<sup>9</sup> However, one group found



**Figure 1.** Comedone-like red-brown papules on the mid upper abdomen.



**Figure 2.** Potassium hydroxide preparation of papule contents.

different keratin expression patterns between steatocystoma and vellus hair cyst, arguing a separate pathologic mechanism of formation.<sup>16</sup>

The clinical differential diagnosis includes acne, steatocystoma multiplex, hidradenitis, folliculitis, and epidermal cysts. Diagnosis can be made with biopsy or with potassium hydroxide preparation of cyst contents that can be expressed manually or with needle evacuation, allowing rapid in-office diagnosis (Figure 2).<sup>17-19</sup> Histologically, eruptive vellus hair cysts have a stratified squamous epithelium and characteristically contain multiple vellus hair shafts.<sup>14</sup>

Treatment is difficult. Spontaneous resolution may occur in up to a quarter of cases.<sup>20,21</sup> Erbium:YAG laser,<sup>22,23</sup> CO<sub>2</sub> laser,<sup>24</sup> needle evacuation,<sup>19</sup> cautery with forcep extraction,<sup>18</sup> topical retinoic acid,<sup>25</sup> topical abrasion followed by urea cream 10%,<sup>6</sup> topical lactic acid 12%,<sup>4</sup> and other modalities have been used with limited success. Erbium:YAG or CO<sub>2</sub> laser treatments may be complicated by hyperpigmentation or scarring. Treatment with systemic isotretinoin was not successful in one study.<sup>26</sup> One report found that tazarotene cream 0.1% twice daily was superior to incision and drainage and was as effective as erbium:YAG laser with less hyperpigmentation.<sup>27</sup>

## REFERENCES

- Esterly NB, Fretzin DF, Pinkus H. Eruptive vellus hair cysts. *Arch Dermatol*. 1977;113:500-503.
- Reep MD, Robson KJ. Eruptive vellus hair cysts presenting as multiple periorbital papules in a 13-year-old boy. *Pediatr Dermatol*. 2002;19:26-27.
- Chan KH, Tang WY, Lam WY, et al. Eruptive vellus hair cysts presenting as bluish-grey facial discoloration masquerading as naevus of Ota. *Br J Dermatol*. 2007;157:188-189.
- Mayron R, Grimwood RE. Familial occurrence of eruptive vellus hair cysts. *Pediatr Dermatol*. 1988;5:94-96.
- Piepkorn MW, Clark L, Lombardi DL. A kindred with congenital vellus hair cysts. *J Am Acad Dermatol*. 1981;5:661-665.
- Stiefler RE, Bergfeld WF. Eruptive vellus hair cysts—an inherited disorder. *J Am Acad Dermatol*. 1980;3:425-429.
- Mieno H, Fujimoto N, Tajima S. Eruptive vellus hair cyst in patients with chronic renal failure. *Dermatology*. 2004;208:67-69.
- Lee HT, Chang SH, Yoon TY. Eruptive vellus hair cyst in a patient with pachyonychia congenita. *J Dermatol*. 1999;26:402-404.
- Moon SE, Lee YS, Youn JI. Eruptive vellus hair cyst and steatocystoma multiplex in a patient with pachyonychia congenita. *J Am Acad Dermatol*. 1994;30(2, pt 1):275-276.
- Takehita T, Takehita H, Irie K. Eruptive vellus hair cyst and epidermoid cyst in a patient with pachyonychia congenita. *J Dermatol*. 2000;27:655-657.
- Köse O, Taştan HB, Deveci S, et al. Anhidrotic ectodermal dysplasia with eruptive vellus hair cysts. *Int J Dermatol*. 2001;40:401-402.
- Somer M, Peippo M, Aalto-Korte K, et al. Cardio-facio-cutaneous syndrome: three additional cases and review of the literature. *Am J Med Genet*. 1992;44:691-695.
- Nandedkar MA, Minus H, Nandedkar MA. Eruptive vellus hair cysts in a patient with Lowe syndrome. *Pediatr Dermatol*. 2004;21:54-57.
- Cho S, Chang SE, Choi JH, et al. Clinical and histologic features of 64 cases of steatocystoma multiplex. *J Dermatol*. 2002;29:152-156.
- Kiene P, Hauschild A, Christophers E. Eruptive vellus hair cysts and steatocystoma multiplex. variants of one entity? *Br J Dermatol*. 1996;134:365-367.
- Tomková H, Fujimoto W, Arata J. Expression of keratins (K10 and K17) in steatocystoma multiplex, eruptive vellus hair cysts, and epidermoid and trichilemmal cysts. *Am J Dermatopathol*. 1997;19:250-253.
- Hong SD, Frieden IJ. Diagnosing eruptive vellus hair cysts. *Pediatr Dermatol*. 2001;18:258-259.
- Kaya TI, Tataroglu C, Tursen U, et al. Eruptive vellus hair cysts: an effective extraction technique for treatment and diagnosis. *J Eur Acad Dermatol Venereol*. 2006;20:264-268.
- Sárdy M, Kárpáti S. Needle evacuation of eruptive vellus hair cysts. *Br J Dermatol*. 1999;141:594-595.
- Bovenmyer DA. Eruptive vellus hair cysts. *Arch Dermatol*. 1979;115:338-339.
- Sina B, Burnett JW. Eruptive vellus hair cysts. *Cutis*. 1984;33:503-504.
- Coras B, Hohenleutner U, Landthaler M, et al. Early recurrence of eruptive vellus hair cysts after Er:YAG laser therapy: case report and review of the literature. *Dermatol Surg*. 2005;31:1741-1744.
- Kageyama N, Tope WD. Treatment of multiple eruptive hair cysts with erbium:YAG laser. *Dermatol Surg*. 1999;25:819-822.
- Hueter CJ, Wheeland RG. Multiple eruptive vellus hair cysts treated with carbon dioxide laser vaporization. *J Dermatol Surg Oncol*. 1987;13:260-263.
- Fisher DA. Retinoic acid in the treatment of eruptive vellus hair cysts. *J Am Acad Dermatol*. 1981;5:221-222.
- Urbina-González F, Aguilar-Martínez A, Cristóbal-Gil MC, et al. The treatment of eruptive vellus hair cysts with isotretinoin. *Br J Dermatol*. 1987;116:465-466.
- Saks K, Levitt JO. Tazarotene 0.1 percent cream fares better than erbium:YAG laser or incision and drainage in a patient with eruptive vellus hair cysts. *Dermatol Online J*. 2006;12:7.