

Herpes Simplex Virus Type 2 of the Palm as an AIDS-Defining Complex

Frances Kirkland Lawhead, MD; Sarah G. Smith, MD; Cristina M. Shimek, MD; Robert Skinner, MD

Herpes simplex virus type 2 (HHV-2) is one of the most common sexually transmitted diseases in the world. In the immunocompromised host, including patients with human immunodeficiency virus (HIV), herpes simplex virus is at high risk for reactivation. We present a woman with HIV and a large ulcer of the palm determined to be HHV-2. Not only was the location of her ulcer unusual, but her CD4 lymphocyte count continued to drop despite improvement of the palmar ulceration with treatment. As a result, her palmar HHV-2 ulcer became an AIDS-defining complex.

Cutis. 2012;89:78-80.

Herpes simplex virus types 1 (HHV-1) and 2 (HHV-2) typically are vesicular orolabial and genital eruptions with primary, latent, and recurrent infections. Herpes simplex virus type 2, spread principally by sexual contact, is one of the most common sexually transmitted diseases in the world.

Case Report

A 34-year-old woman with human immunodeficiency virus (HIV) presented with a 6.5×4-cm painful ulcer with deep undermined borders of her right hand (Figure 1A). The ulcer had been increasing in size for several months and had not responded to antibiotic ointment. She had no constitutional symptoms. Aside from HIV, she had no other relevant medical history. The differential diagnosis of the hand lesion

included squamous cell carcinoma, viral infection, mycobacterial infection, and deep fungal infection.

A biopsy showed a broad ulcer with rare degenerated keratinocytes. Multinucleated cells with nuclear molding and intranuclear inclusions were identified, compatible with herpesvirus cytopathic effect (Figure 2). Viral cultures grew HHV-2. At a subsequent visit, the patient was questioned about any history of genital or oral ulceration, which she denied, and she was started on acyclovir 800 mg 3 times daily. The ulcer cleared after 3 weeks of therapy but then recurred despite continued treatment. She was switched to famciclovir 500 mg twice daily and the lesion improved (Figure 1B).

In the 9 months preceding her initial presentation, the patient's CD4 lymphocyte count had dropped from 375 to 267 cells/mm³ (reference range, 500–1000 cells/mm³; AIDS, <200 cells/mm³). Despite improvement of the herpetic ulceration on the hand with treatment of HHV-2, her CD4 lymphocyte count continued to drop from 267 to 181 cells/mm³.

Comment

Herpes simplex virus primary infection usually presents within 3 to 7 days after exposure with a viral prodrome plus localized tenderness and burning.^{1,2} These sensations precede painful vesicles on an erythematous base progressing to pustules and ulceration. Typically, multiple grouped vesicles develop followed by crusting and resolution within 2 to 6 weeks.^{1,2}

The virus replicates at the infection site and traverses through axons to the dorsal root ganglion where it remains dormant until reactivation. Reactivation can occur spontaneously or with a stimulus such as UV radiation, stress, fever, or immunosuppression.^{1,2} Shedding of the virus can occur regardless of symptoms.³ Similar to our patient, 75% to 90% of seropositive HHV-2 patients report no history of primary infection.¹

Herpes simplex virus can occur anywhere on the body including the finger in herpetic whitlow, disseminated forms in eczema herpeticum and herpes

Drs. Lawhead and Skinner are from the University of Tennessee Health Science Center, Memphis. Dr. Smith is from Saint Louis University Medical Center, Missouri. Dr. Shimek is from Duckworth Pathology Group, Memphis.

The authors report no conflict of interest.

Correspondence: Frances Kirkland Lawhead, MD, 956 Court, Coleman Bldg, Room D322, Memphis, TN 38163 (fkirklan@utmem.edu).

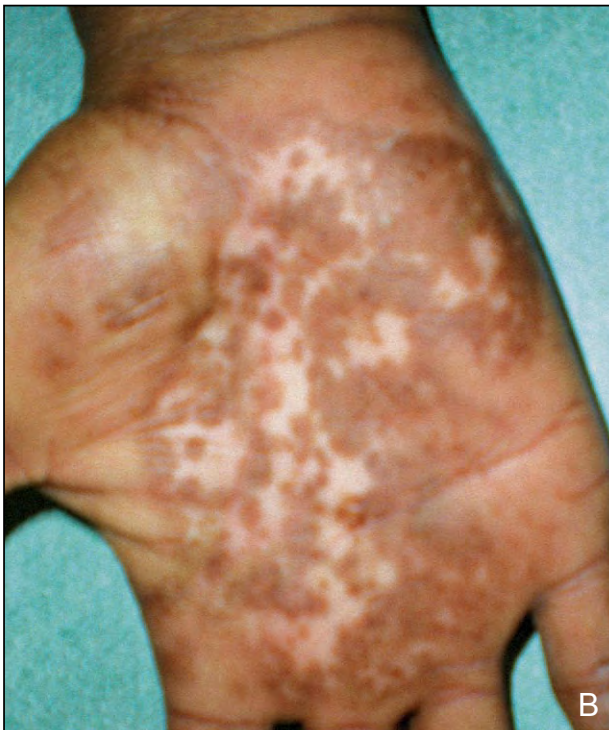
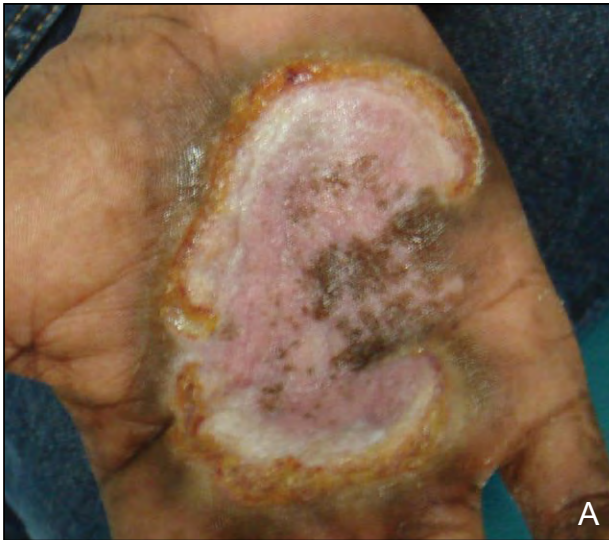
Figure 1. A 6.5×4-cm ulcer with deep undermined borders on the right hand before (A) and after treatment with famciclovir (B).

gladiatorum, the hair follicle in herpes folliculitis, and the brain in herpes encephalitis.² In 1988, Gill et al⁴ discussed 79 patients with herpes simplex virus infection of the hand, most commonly the digits (fingers, 69%; thumb, 21%). Although a chronic lesion on a digit is somewhat common, we did not find cases of the palm, much less as a chronic ulcer caused by HHV-2. Additionally, none of the patients reported

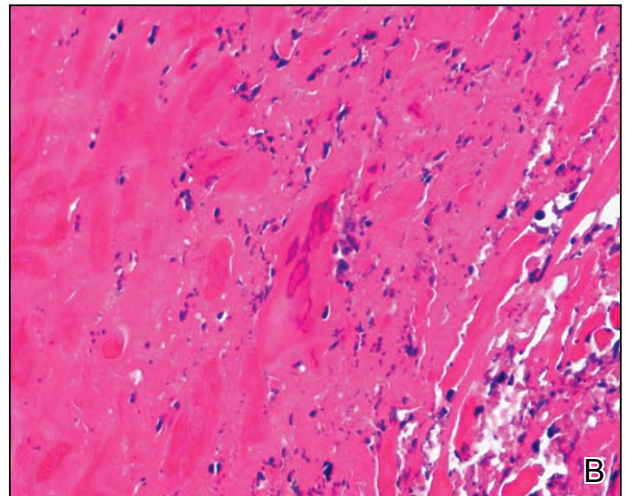
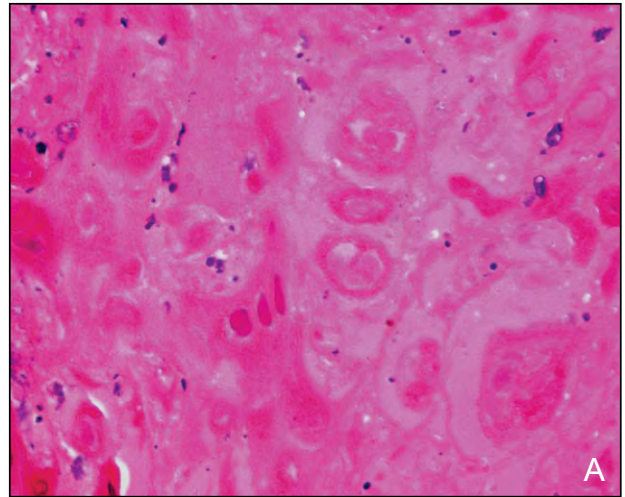


Figure 2. Multinucleated cells with nuclear molding and intranuclear inclusions were identified, compatible with herpesvirus cytopathic effect (A and B)(H&E; original magnifications ×100 and ×400, respectively).

by Gill et al⁴ were known to have HIV. In our research, we did not find a large series comparing herpes simplex virus of the hand in patients with HIV versus age/sex matched controls who are HIV negative.

The location and presentation of herpes simplex virus can be particularly uncharacteristic with immunodeficiency. Frequently, an expanding chronic genital ulceration is seen in immunocompromised patients, but lesions can appear verrucous, exophytic, or pustular. Herpes simplex virus outbreaks tend to be more severe with more frequent viral shedding in immunosuppressed versus immunocompetent hosts.^{2,3}

The Centers for Disease Control and Prevention define herpes as an AIDS-defining complex when there is a herpetic ulceration of more than 1 month's duration.⁵ Most commonly, however, these ulcers

are located in the anogenital area.^{1,3} At the time of our patient's initial presentation, her CD4 lymphocyte count was above 200 cells/mm³, but it continued to drop below that mark while she was being treated with antivirals. Despite the atypical location, her HHV-2 palmar ulceration became her AIDS-defining complex. In a case report, Glickel⁶ discussed 3 patients with AIDS or AIDS-defining complex with herpetic hand infections in 1988. Aside from our patient, herpes simplex virus of the hand with HIV is not a well-documented AIDS-defining complex.

Antiviral therapy has appreciably improved the natural history of herpes simplex virus. For primary and recurrent genital herpes, oral antivirals including acyclovir, famciclovir, and valacyclovir are the desired treatments. In the immunocompromised population, however, acyclovir resistance is of increasing concern and antivirals should be given until the cutaneous lesions completely heal.²

In 2007, Nagot et al⁷ reported that HIV patients on suppressive therapy for herpes simplex virus have a better response to antiretroviral therapy and decreased HIV-1 RNA level. Acquiring HHV-2 subsequent to HIV infection does not notably affect HIV dynamics and CD4 lymphocyte levels⁸; however, HIV patients on suppressive therapy for herpes simplex virus have a better response to antiretroviral therapy manifested by a decreased HIV-1 RNA level.^{1,7}

Our case is of interest because the herpetic ulceration was chronic, it involved the majority of the patient's palm, the isolated virus was

HHV-2, the patient had HIV, and her CD4 lymphocyte count continued to drop despite improvement of the HHV-2 hand ulceration with treatment. In this case, the HHV-2 ulcer of the palm acted as an AIDS-defining complex.

REFERENCES

1. Yeung-Yue KA, Brentjens MH, Lee PC, et al. Herpes simplex viruses 1 and 2. *Dermatol Clin*. 2002;20:249-266.
2. Madkan V, Sra K, Brantley J, et al. Human herpesviruses. In: Bologna J, Jorizzo J, Rapini R, et al, eds. *Dermatology*. 2nd ed. Spain: Mosby Elsevier; 2008:1199-1217.
3. Tying SK, Carlton SS, Evans T. Herpes. atypical clinical manifestations. *Dermatol Clin*. 1998;16:783-788, xiii.
4. Gill MJ, Arlette J, Buchan K. Herpes simplex virus infection of the hand: a profile of 79 cases. *Am J Med*. 1988;84:89-93.
5. AIDS-defining conditions. Centers for Disease Control and Prevention Web site. <http://www.cdc.gov/mmwr/preview/mmwrhtml/rr5710a2.htm>. Published December 5, 2008. Accessed January 17, 2012.
6. Glickel SZ. Hand infections in patients with acquired immunodeficiency syndrome. *J Hand Surg Am*. 1988;13:770-775.
7. Nagot N, Ouédraogo A, Foulongne V, et al. Reduction of HIV-1 RNA levels with therapy to suppress herpes simplex virus. *N Engl J Med*. 2007;356:790-799.
8. Cachay ER, Frost SD, Poon AF, et al. Herpes simplex virus type 2 acquisition during recent HIV infection does not influence plasma HIV levels. *J Acquir Immune Defic Syndr*. 2008;47:592-596.



NEED MORE INFORMATION?

Access these related articles in our online archives at www.cutis.com

- ▾ Herpetic Finger Infection
- ▾ Treatment of Recalcitrant Herpes Simplex Virus With Topical Imiquimod

Use our Advanced Search to find these articles and more online!