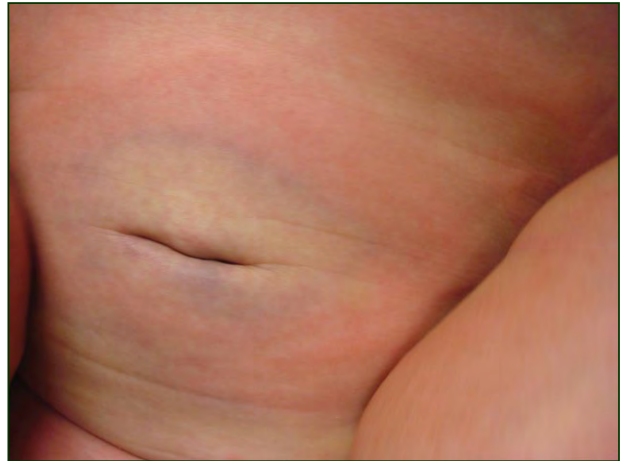
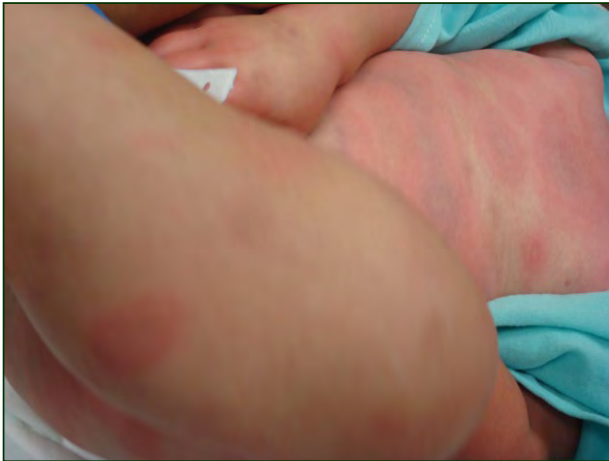
## What Is Your Diagnosis?



A 15-month-old boy presented to his pediatrician and was noted to have increased fussiness, oral thrush, and right-sided otitis media. He was started on nystatin and a 14-day course of oral amoxicillin. One day after the final dose of amoxicillin, he developed several erythematous targetoid macules and patches with dusky purple centers on his face and chest. Two days later he was brought to the emergency department with a fever (temperature, 38.92°C); edema of his hands and feet; and spread of the cutaneous eruption to involve his trunk, extremities, and face.

PLEASE TURN TO PAGE 262 FOR DISCUSSION

Abigail F.W. Donnelly, MD; Brandie Tackett, MD

Dr. Donnelly is from Mayo Clinic, Scottsdale, Arizona. Dr. Tackett is in private practice, Westlake, Ohio. The authors report no conflict of interest.

Correspondence: Abigail F.W. Donnelly, MD, Mayo Clinic, 13400 East Shea Blvd, Scottsdale, AZ 85259 (donnelly.abigail@mayo.edu).

## The Diagnosis: Urticaria Multiforme

The term *urticaria multiforme* (UM) is relatively new, first defined in 2007 by Shah et al<sup>1</sup> as a clinically distinct subtype of urticaria characterized by evanescent annular or polycyclic wheals. These striking arcuate plaques also have been termed *giant urticaria* and *acute annular urticaria*.<sup>2,3</sup> Acute urticaria is common in children, and 15% to 20% of children have had at least 1 urticarial episode. However, the geometric patterns, purpuric centers, and associated angioedema and fever of UM lead to its frequent confusion with more serious misdiagnoses such as erythema multiforme (EM).<sup>4,5</sup>

Differentiation between acute urticaria and EM can be achieved with a thorough clinical history and physical examination. Important clinical features to note are the morphology of individual lesions, mucous membrane involvement or lack thereof, associated systemic symptoms, recent illnesses, medication history, and family history.

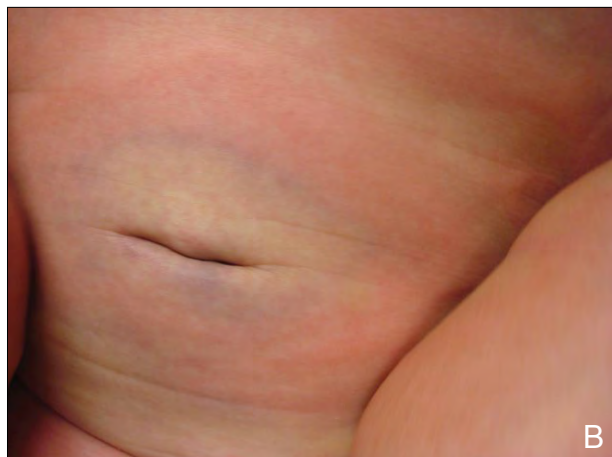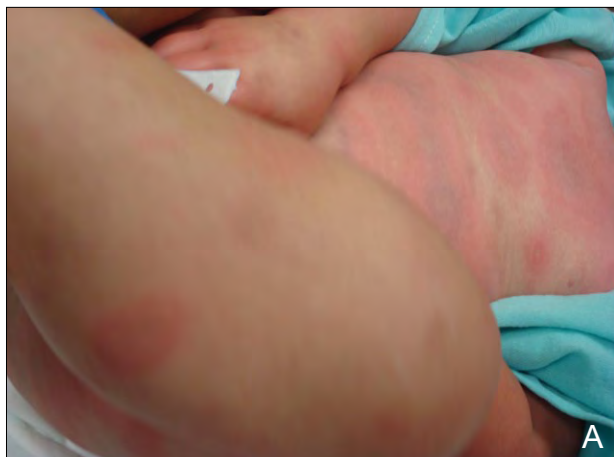Urticaria multiforme begins as small erythematous blanchable macules or papules, as seen in typical urticaria. However, unlike acute urticaria, progression into large evanescent wheals that become arcuate, annular, and polycyclic occurs (Figure 1). They may have an ecchymotic center or show central pallor.<sup>1</sup> Individual wheals fade after several hours and total resolution typically is seen within 24 to 48 hours of antihistamine administration. On the other hand, EM is characterized by a pathognomonic targetoid papule or bull's-eye that often shows a central vesicle or necrotic crust. These lesions

often involve acral skin, especially the palms and soles. Skin necrosis and vesicles are not present in UM, and the individual lesions last a shorter duration than the 7 to 14 days seen in patients with EM.

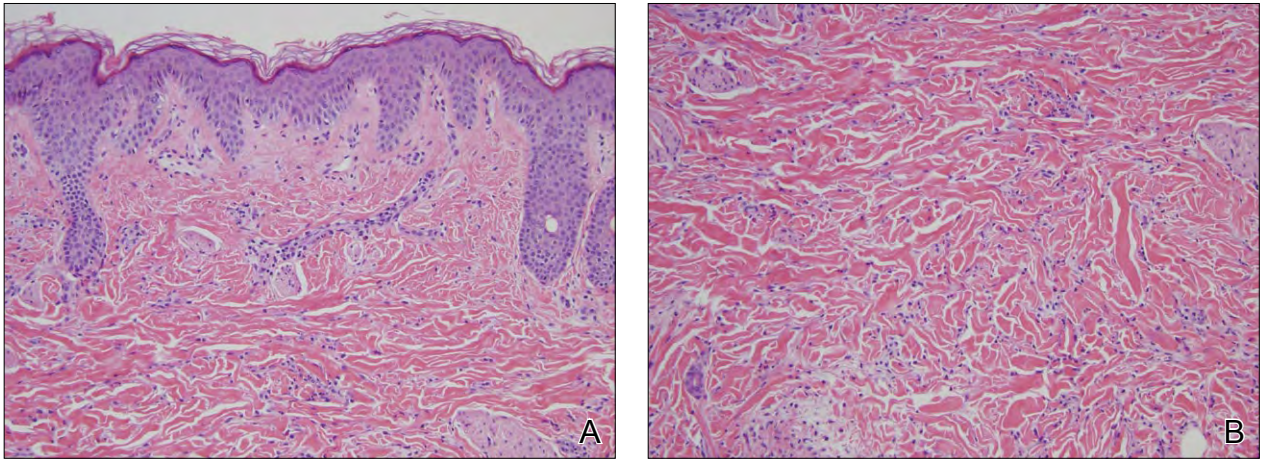
Urticaria multiforme is most often reported in children aged 4 months to 4 years.<sup>1</sup> In contrast, EM is relatively rare in infants and children younger than 4 years.<sup>6</sup> Oral and conjunctival mucosal involvement are common in EM but are not found in UM. The causes of EM are similar to UM and include a wide range of medications and infections, especially recurrent herpes simplex virus infections and less commonly *Mycoplasma pneumoniae* infection.<sup>7</sup>

Biopsy typically is not necessary to differentiate between UM and EM; however, in rapidly progressive cases in which the diagnosis is not certain, biopsy may be performed. Biopsy of UM will reveal a perivascular infiltrate of lymphocytes and eosinophils, dermal edema, and uninvolved epidermis (Figure 2).<sup>8</sup> A perivascular lymphocytic infiltrate also can be seen in EM, but presence of eosinophils is rare. In EM there also is the additional finding of epidermal necrosis, which is not seen in urticaria.

Once the clinician has defined an urticarial eruption such as UM, parents/guardians can be reassured of the benign course of the disease.<sup>1</sup> A defined etiology of the episode is desirable to avoid future triggering agents, but the lengthy list of common triggers renders this process difficult. Infections associated with UM include upper respiratory tract infection, otitis media, and viral gastroenteritis.<sup>1</sup> Medications



**Figure 1.** Urticaria multiforme with annular, arcuate, polycyclic, erythematous wheals present on the patient's trunk, thighs, hands, and feet (A and B).



**Figure 2.** Histology of urticaria multiforme with an uninvolved epidermis, papillary dermal edema, and perivascular infiltrate of lymphocytes and eosinophils (A and B)(both H&E, original magnification  $\times 40$ ).

associated with urticarial eruptions include amoxicillin, cephalosporins, macrolides, aspirin and acetaminophen, and rarely ibuprofen.<sup>2,6,9</sup> Before the onset of his rash, our patient had been exposed to several of these triggers, including otitis media, amoxicillin, and antipyretics.

Patients with UM that has been identified early in the disease process may be successfully treated as an outpatient with oral antihistamines. However, an incomplete response to oral antihistamines is common. The basic mechanism underlying UM involves the release of several vasoactive mediators including histamine, which produces the classic triad of increased vascular permeability, vasodilation, and promotion of an axon reflex. The combination of all of these vasoactive mediators promotes the progression of UM.<sup>10</sup> For this reason, the administration of systemic antihistamines, preferably H<sub>1</sub> and H<sub>2</sub> antihistamine combination therapy, provides maximal benefit. Systemic corticosteroids are not recommended as first-line therapy and are reserved for patients who remain symptomatic following antihistamine therapy.<sup>1</sup>

Because of the high prevalence of urticarial reactions in children, clinicians who interact with the pediatric population need to be able to differentiate UM from other entities that may present with similar dermatologic manifestations. A careful clinical history and physical examination performed by a trained physician is the most valuable diagnostic tool and prevents unnecessary testing and unwarranted treatment. The rapid resolution and transient nature of individual urticarial lesions and acral angioedema in combination with a favorable response to H<sub>1</sub> and H<sub>2</sub> antihistamine therapy aid in the diagnosis of UM. Additionally, lack of

mucosal involvement, skin necrosis, and vesicles will help the clinician differentiate UM from EM.

## REFERENCES

1. Shah KN, Honig PJ, Yan AC. "Urticaria multiforme": a case series and review of acute annular urticarial hypersensitivity syndromes in children. *Pediatrics*. 2007;119:e1177-e1183.
2. Legrain V, Taïeb A, Sage T, et al. Urticaria in infants: a study of forty patients. *Pediatr Dermatol*. 1990;7:101-107.
3. Weston WL, Lane AT. Vascular reactions: urticaria, the erythemas and purpuras. In: Weston WL, Lane AT. *Color Textbook of Pediatric Dermatology*. St Louis, MO: Mosby Year Book; 1991:161-165.
4. Warin RP, Champion RH. Types and incidence of urticaria. In: Rook A, ed. *Major Problems in Dermatology*. London, England: WB Saunders; 1974:10-14.
5. Kauppinen K, Juntunen K, Lanki H. Urticaria in children. retrospective evaluation and follow-up. *Allergy*. 1984;39:469-472.
6. Tamayo-Sanchez L, Ruiz-Malodonado R, Laterza A. Acute annular urticaria in infants and children. *Pediatr Dermatol*. 1997;14:231-234.
7. Krowchuck DP, Mancini AJ, eds. *Pediatric Dermatology: A Quick Reference Guide*. Elk Grove Village, IL: American Academy of Pediatrics; 2007.
8. Johnson BL, Honig PJ, Jaworsky C. *Pediatric Dermatopathology: Clinical and Pathologic Correlations*. Boston, MA: Butterworth-Heinemann; 1994.
9. Mortureux P, Léauté-Labrèze C, Legrain-Lifermann V, et al. Acute urticaria in infancy and early childhood: a prospective study. *Arch Dermatol*. 1998;134:319-323.
10. Alonso Lebrero E. Round Table: urticaria and angioedema: introduction and classification [in Spanish]. *Allergol Immunopathol (Madr)*. 1999;27:71-73.