

Chemotherapy-Induced Inflammatory Seborrheic Keratoses in a Man With Acute Myeloid Leukemia: A Variant of Leser-Trélat Sign?

Evelyn Lilly, MD; Scott R. Granter, MD; Harley A. Haynes, MD; Omar A. Ibrahimi, MD, PhD

Leser-Trélat sign is a controversial paraneoplastic phenomenon characterized by an eruption of seborrheic keratoses (SKs). We report a rare case of eruptive inflammatory SKs in a man undergoing induction chemotherapy for acute myeloid leukemia (AML). We also review the literature on Leser-Trélat sign.

Cutis. 2012;90:235-236.

Case Report

A 51-year-old man who recently was diagnosed with acute myeloid leukemia (AML) presented with a pseudovesicular eruption that had appeared 18 hours prior. He had a history of primary varicella infection in childhood. The patient was on day 6 of induction chemotherapy with cytarabine, daunorubicin, and etoposide when he noticed an asymptomatic pseudovesicular eruption over his chest (Figure 1), inferior neck, and abdomen. Attempts to unroof multiple lesions for Tzanck test and viral culture were unsuccessful. Histopathologic examination of a punch biopsy from a representative lesion revealed a flat-based, basaloid proliferation of keratinocytes with acanthosis, hyperkeratosis, and horn cysts (Figure 2A). Punch biopsies of 2 additional lesions revealed similar findings (Figures 2B and 2C).

Comment

Leser-Trélat sign was first described in 1890, but its validity continues to be controversial. Although there are many case reports of Leser-Trélat sign in patients with malignancies, 3 case-control studies failed to show a significant association between eruption of numerous seborrheic keratoses (SKs) and internal malignancies.¹⁻³ These studies have been hindered by the small number of patients evaluated (maximum of 150 patients) for the considerably rare paraneoplastic phenomenon.

The etiology of Leser-Trélat sign is proposed to be the release of tumor products that act on epidermal

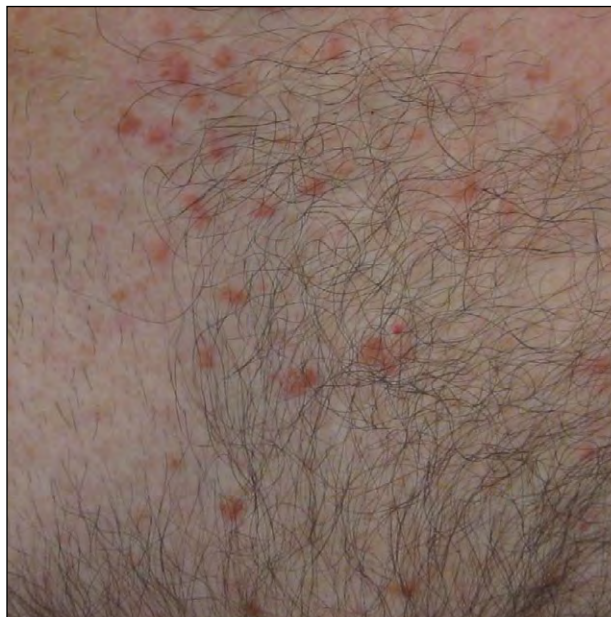

Figure 1. A pseudovesicular eruption over the chest.

From the Departments of Dermatology and Dermatopathology, Harvard Medical School, Brigham and Women's Hospital, Boston, Massachusetts, and the Connecticut Skin Institute, Stamford.

The authors report no conflict of interest.

Correspondence: Omar A. Ibrahimi, MD, PhD, Connecticut Skin Institute, Stamford, CT 06905 (Omar.Ibrahimi@gmail.com).

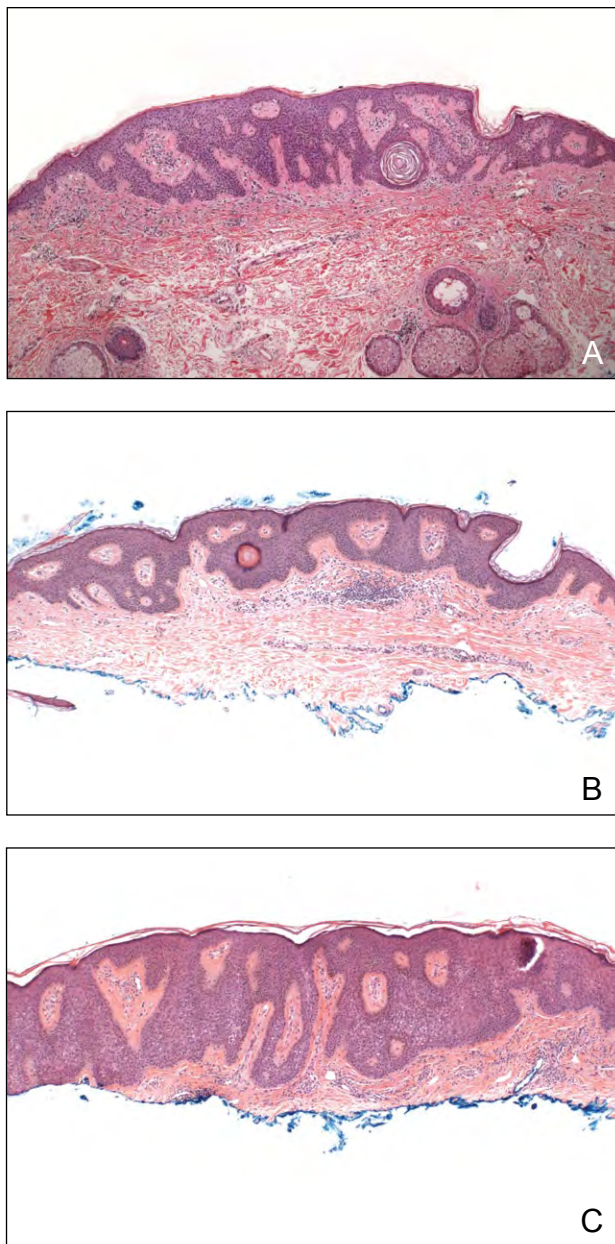


Figure 2. Histopathologic examination revealed a flat-based, basaloid proliferation of keratinocytes with acanthosis, hyperkeratosis, and horn cysts; a superficial lymphocytic infiltrate also was present (A)(H&E, original magnification $\times 20$). Subsequent biopsies of 2 additional lesions showed similar findings (B and C)(H&E; original magnifications $\times 20$ and $\times 20$, respectively).

growth factor receptors.⁴ Approximately one-half of eruptions of SK with concomitant internal malignancy improve with the treatment of the underlying malignancy.⁵

We reported Leser-Trélat sign presenting in a patient during induction chemotherapy for AML. One-fifth of patients with Leser-Trélat sign have lymphoproliferative disorders.⁶ Three other cases of chemotherapy-induced eruptions of SK have been reported.⁷⁻⁹ The previously reported cases and our patient have key commonalities. First, all 4 patients had AML. Second, the onset of the eruptions seemed to coincide with the use of cytarabine. Third, the lesions were all somewhat pseudovesicular, as disseminated herpes zoster was prominent in the differential diagnosis, which is particularly interesting because cytarabine is known to have some antiviral properties. Finally, the SKs in all cases displayed inflammation on histology.

It is unclear if a chemotherapy-induced eruption of SKs shares the same etiology as Leser-Trélat sign in patients with occult internal malignancies who have not yet been treated with chemotherapy. However, our report of cytarabine-induced inflammatory SKs in a patient with AML suggests that the etiology of Leser-Trélat sign should be researched further.

REFERENCES

1. Fink AM, Filz D, Krajnik G, et al. Seborrheic keratoses in patients with internal malignancies: a case-control study with prospective accrual of patients [published online ahead of print March 4, 2009]. *J Eur Acad Dermatol Venereol.* 2009;23:1316-1319.
2. Lindelof B, Sigurgeirsson B, Melander S. Seborrheic keratoses and cancer. *J Am Acad Dermatol.* 1992;26:947-950.
3. Grob JJ, Rava MC, Gouvernet J, et al. The relation between seborrheic keratoses and malignant solid tumours. a case-control study. *Acta Derm Venereol.* 1991;71:166-169.
4. Moore RL, Devere TS. Epidermal manifestations of internal malignancy. *Dermatol Clin.* 2008;26:17-29, vii.
5. Ellis DL, Yates RA. Sign of Leser-Trélat. *Clin Dermatol.* 1993;11:141-148.
6. Kurzrock R, Cohen PR. Cutaneous paraneoplastic syndromes in solid tumors. *Am J Med.* 1995;99:662-671.
7. Patton T, Zirwas M, Nieland-Fisher N, et al. Inflammation of seborrheic keratoses caused by cytarabine: a pseudo sign of Leser-Trélat. *J Drugs Dermatol.* 2004;3:565-566.
8. Williams JV, Helm KF, Long D. Chemotherapy-induced inflammation in seborrheic keratoses mimicking disseminated herpes zoster. *J Am Acad Dermatol.* 1999;40:643-644.
9. Kechijian P, Sadick NS, Mariglio J, et al. Cytarabine-induced inflammation in the seborrheic keratoses of Leser-Trélat. *Ann Intern Med.* 1979;91:868-869.