

# Woringer-Kolopp Disease Mimicking Foot Dermatitis

Yongxue Yao, MD, PhD; Lawrence A. Mark, MD, PhD

*Woringer-Kolopp disease, also known as localized pagetoid reticulosis, is a rare cutaneous lymphoproliferative disorder classified as a solitary variant of mycosis fungoides (MF). Despite the indolent and benign nature of the disease, misdiagnosis and inappropriate treatment may result in years of debilitating symptoms and even loss of function. We present the case of a patient with long-standing Woringer-Kolopp disease that mimicked foot dermatitis. Histopathologic examination demonstrated epidermotropic infiltration of atypical lymphocytes that were CD3<sup>+</sup>CD4<sup>-</sup>CD8<sup>-</sup>. The patient was successfully treated with topical keratolytics and bexarotene gel 1% with minimal residual lesions after 8 years of follow-up. We discuss the characteristics of this rare disease in contrast with localized MF as well as more aggressive forms of epidermotropic T-cell lymphoma.*

*Cutis.* 2012;90:307-309, 316.

## Case Report

A 76-year-old man presented to our clinic with a 35-year history of chronic dermatitis of the left foot. The lesions had progressed slowly and were previously unresponsive to topical steroids or antifungal treatments. The patient was otherwise healthy and did not report any constitutional symptoms such as fever, night sweats, or weight loss. He had no allergies and was on no medications other than daily multivitamins.

Physical examination revealed a healthy white man in no acute distress. There were relatively well-demarcated red patches and plaques with hyperkeratotic scaling on the plantar and dorsal aspects of the left foot (Figure 1). No evidence of interdigital maceration was noted. The patient's toenails were unremarkable.

A potassium hydroxide preparation did not reveal fungal hyphae; a 4-mm punch biopsy of the dorsal foot then was performed. Histology revealed focal collections of atypical lymphocytes within the epidermis (Figure 2). In some areas, these atypical lymphocytes were lined up along the basal layer of the epidermis. Within the dermis, there was scant perivascular mononuclear cell infiltrate. Immunohistochemical stains revealed that the lymphocytes were all CD3<sup>+</sup> T cells (Figure 3A); normal lymphocytes within the epidermis were CD4<sup>+</sup> (Figure 3B), while scattered normal lymphocytes present in the dermis were CD8<sup>+</sup> (Figure 3C). Additionally, diminished CD7 expression was observed (not shown). These clinical and histologic findings were consistent with Woringer-Kolopp disease; therefore, corroborative T-cell clonality studies were deferred.

The patient was treated with urea cream 40% once daily for keratolysis and bexarotene gel 1% 3 times daily. He responded well to treatment and the plaques were at least 75% resolved after a 3-month regimen. The patient also applied desoximetasone ointment 0.25% once daily to diminish concomitant irritation from the retinoid. On his most recent follow-up visit 8 years later, the patient showed no evidence of dissemination despite a small amount of lesional residue on his left foot (Figure 4).

## Comment

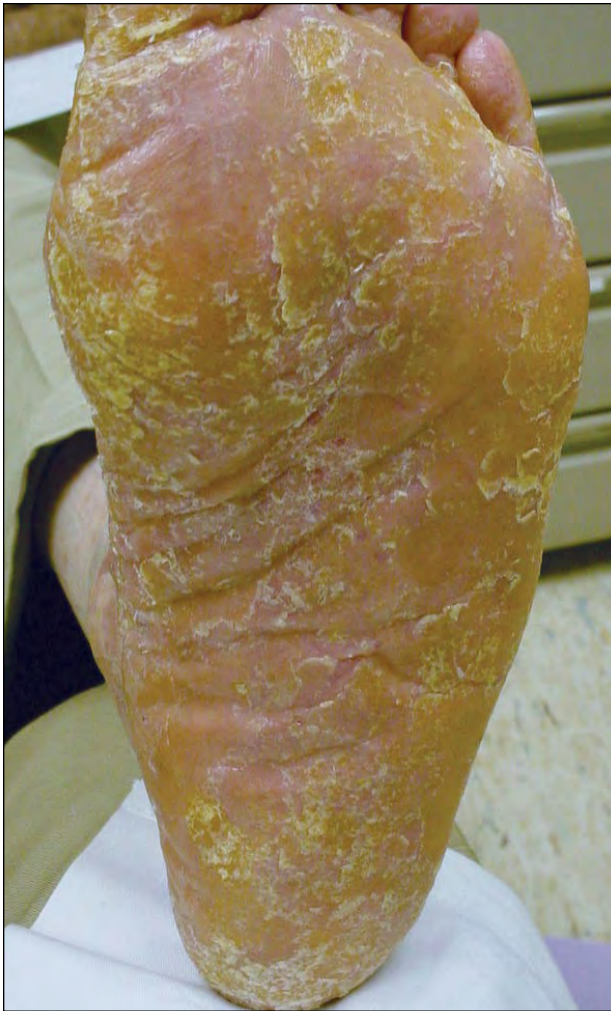Woringer-Kolopp disease, also known as localized pagetoid reticulosis, is a rare cutaneous lymphoproliferative disorder that was first described by Woringer and Kolopp<sup>1</sup> in 1939.<sup>2</sup> Clinical characteristics of this disorder include indolent, slowly progressive, unilesional, erythematous patches or plaques on the

---

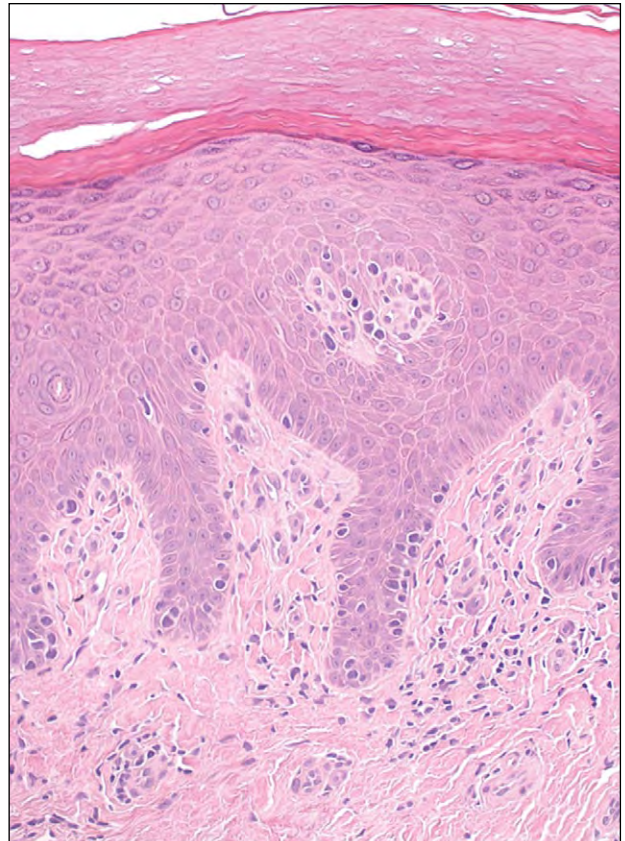
Both from the Department of Dermatology, Indiana University School of Medicine, Indianapolis. Dr. Yao also is from the Herman B. Wells Center for Pediatric Research, Department of Pediatrics, Indiana University School of Medicine.

Dr. Yao reports no conflict of interest. Dr. Mark has been a consultant for Eisai Inc.

Correspondence: Lawrence A. Mark, MD, PhD, Department of Dermatology, Indiana University School of Medicine, 550 N University Blvd, UH 3240, Indianapolis, IN 46202 (lmark@iupui.edu).



**Figure 1.** Initial clinical appearance of Woringer-Kolopp disease mimicking chronic dermatitis on the left foot.



**Figure 2.** Histopathology revealed an epidermotropic infiltrate of atypical lymphocytes (H&E, original magnification  $\times 200$ ).

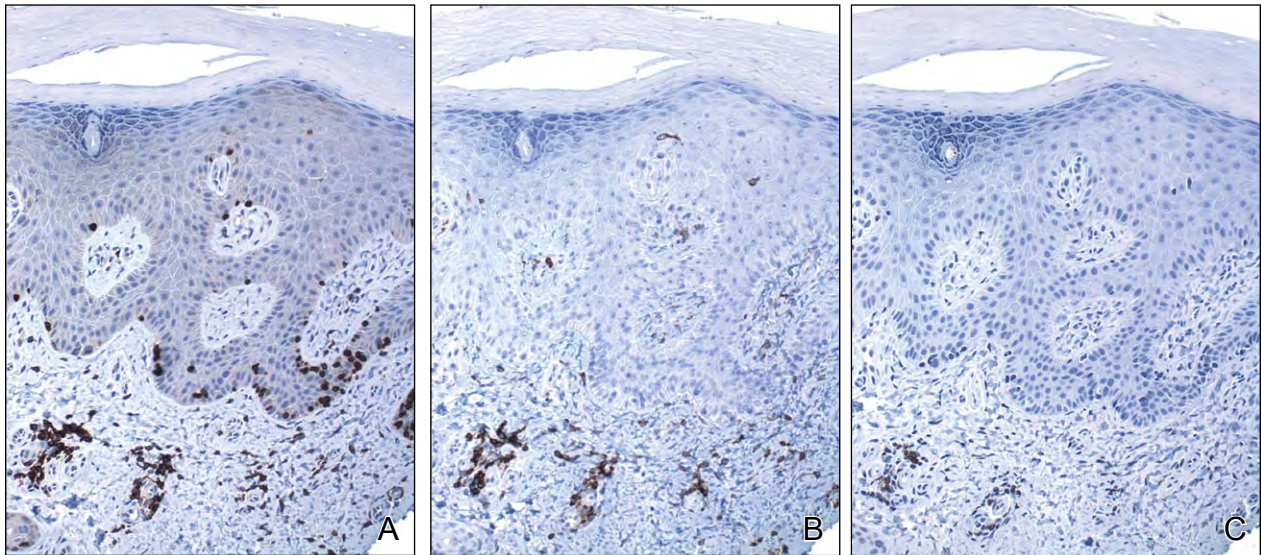
extremities; histologic signs include an epidermotropic infiltrate of atypical T lymphocytes.<sup>3,4</sup> According to the 2005 World Health Organization and European Organization for Research and Treatment of Cancer (WHO-EORTC) classification of cutaneous lymphomas, Woringer-Kolopp disease is classified as a solitary variant of cutaneous T-cell lymphoma (CTCL), also known as mycosis fungoides (MF).<sup>4,5</sup>

There is some debate regarding the relationship between Woringer-Kolopp disease and unilesional MF. Some researchers believe they are synonymous<sup>3</sup>; however, others suggest that they are distinct clinicopathologic entities.<sup>6,7</sup> The key contrasting features include both their clinical courses and histopathologic characteristics. Woringer-Kolopp disease has a more benign clinical course than MF and almost never evolves into disseminated lymphoma, despite the risk for local recurrence.<sup>3,6,8,9</sup> Additionally, the

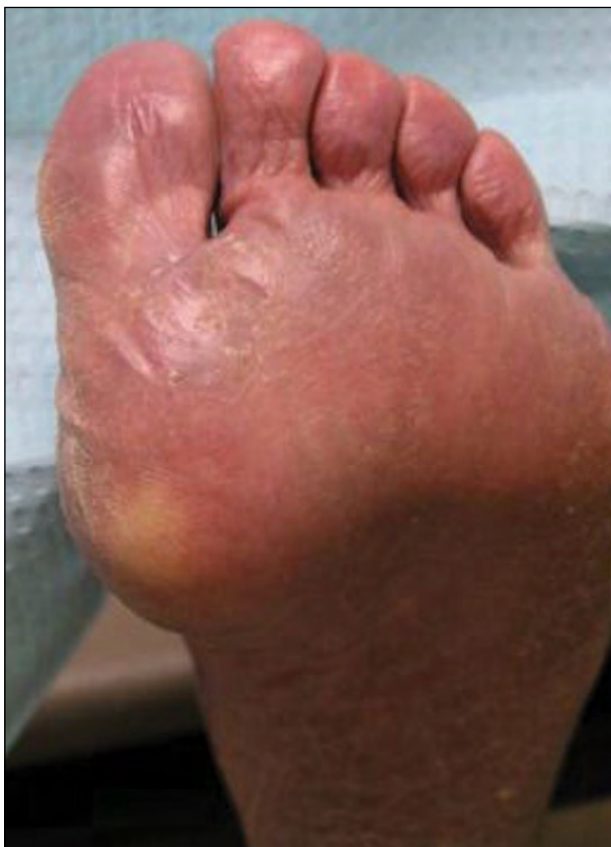atypical lymphocytes found in Woringer-Kolopp disease are confined to the epidermis with nonspecific perivascular lymphohistiocytic infiltrate of the dermis.<sup>7,10</sup> In MF, however, the atypical lymphocytes are most often seen invading the epidermis but also are present in the dermis.<sup>7,11</sup> Therefore, Woringer-Kolopp disease may at most be considered an epidermotropic variant of MF. Furthermore, the immunophenotype of atypical lymphocytes in Woringer-Kolopp disease can be either  $CD3^+CD4^+$ ,  $CD3^+CD8^+$ , or  $CD3^+CD4^-CD8^-$  T cells, which are more variable than the typical  $CD3^+CD4^+$  phenotype in MF.<sup>6,8,9</sup>

In our patient, the atypical lymphocytes were  $CD3^+CD4^-CD8^-$  T cells that were restricted above the dermoepidermal junction. Based on these histopathologic findings and the patient's indolent clinical course, he was diagnosed with Woringer-Kolopp disease of a  $CD3^+CD4^-CD8^-$  immunophenotype. This immunophenotype should be distinguished from cutaneous gamma-delta T-cell lymphoma, a provisional entity under the WHO-EORTC classification that is associated with a highly aggressive clinical presentation.<sup>4</sup>





**Figure 3.** CD3 (A), CD4 (B), and CD8 (C) immunohistochemical stains of the skin biopsy specimen (all original magnification  $\times 200$ ).



**Figure 4.** Clinical appearance after treatment with topical bexarotene. The patient had residual lesions after 8 years of follow-up.

Effective treatments of Woringer-Kolopp disease include topical nitrogen mustard therapy, localized radiation therapy, and phototherapy using either

psoralen plus UVA or narrowband UVB.<sup>8</sup> However, patients with Woringer-Kolopp disease may not be accurately diagnosed until years after initial clinical presentation, partially due to the rarity and indolent nature of the disease. Typical misdiagnoses include fungal or bacterial infection, localized psoriasis, or contact dermatitis. We reported a case of Woringer-Kolopp disease that mimicked foot dermatitis. Our patient was diagnosed by skin biopsy 35 years after the initial onset of the disease. He was successfully treated with topical bexarotene with minimal residual lesions after 8 years of follow-up.

### Conclusion

In summary, we report the unusual case of Woringer-Kolopp disease with a  $CD3^+CD4^-CD8^-$  immunophenotype that mimicked foot dermatitis. We suggest that any skin dermatoses that are refractory to steroids and antifungal treatments warrant a timely skin biopsy to ensure appropriate diagnosis and treatment.

### REFERENCES

1. Woringer FR, Kolopp P. Lésion érythémato-squameuse polycyclique de l'avant-bras évoluant depuis 6 ans chez un garçonnet de 13 ans: histologiquement infiltrate intra-épidermique apparence tumorale. *Ann Dermatol Venerol.* 1939;10:945-948.
2. Braun-Falco O, Marghescu S, Wolff HH. Pagetoid reticulosis—Woringer-Kolopp's disease [in German]. *Hautarzt.* 1973;24:11-21.

CONTINUED ON PAGE 316

CONTINUED FROM PAGE 309

3. Burns MK, Chan LS, Cooper KD. Woringer-Kolopp disease (localized pagetoid reticulosis) or unilesional mycosis fungoides? an analysis of eight cases with benign disease. *Arch Dermatol*. 1995;131:325-329.
4. Willemze R, Jaffe ES, Burg G, et al. WHO-EORTC classification for cutaneous lymphomas (published online ahead of print February 3, 2005). *Blood*. 2005;105:3768-3785.
5. Burg G, Kempf W, Cozzio A, et al. WHO/EORTC classification of cutaneous lymphomas 2005: histological and molecular aspects. *J Cutan Pathol*. 2005;32:647-674.
6. Haghighi B, Smoller BR, LeBoit PE, et al. Pagetoid reticulosis (Woringer-Kolopp disease): an immunophenotypic, molecular, and clinicopathologic study. *Mod Pathol*. 2000;13:502-510.
7. Ringel E, Medenica M, Lorincz A. Localized mycosis fungoides not manifesting as Woringer-Kolopp disease. *Arch Dermatol*. 1983;119:756-760.
8. Lee J, Viakhireva N, Cesca C, et al. Clinicopathologic features and treatment outcomes in Woringer-Kolopp disease [published online ahead of print June 11, 2008]. *J Am Acad Dermatol*. 2008;59:706-712.
9. Mielke V, Wolff HH, Winzer M, et al. Localized and disseminated pagetoid reticulosis. diagnostic immunophenotypic findings. *Arch Dermatol*. 1989;125:402-406.
10. Miedler JD, Kristjansson AK, Gould J, et al. Pagetoid reticulosis in a 5-year-old boy. *J Am Acad Dermatol*. 2008;58:679-681.
11. Kazakov DV, Burg G, Kempf W. Clinicopathological spectrum of mycosis fungoides. *J Eur Acad Dermatol Venereol*. 2004;18:397-415.