

Pili Annulati Associated With Hair Fragility: Cause or Coincidence?

Kimberly Werner, MD; Sharleen St-Surin-Lord, MD; Leonard C. Sperling, MD

Pili annulati is a disorder that produces a spangled appearance to the hair, caused by alternating light and dark banding of hair shafts. This phenomenon is created by abnormal cavities in the cortex of the hair shaft, which produces lighter bands seen on clinical examination. Complications of pili annulati are limited; the most noteworthy complication is increased breakage secondary to weathering of the abnormal hair shafts. We report a case of a 14-year-old adolescent girl with pili annulati and progressive hair loss of 2 months' duration. Most of her hairs were notably short, spangled, and lusterless with light and dark banding observed with handheld magnification. Light microscopy demonstrated alternating light and dark bands, and the dark bands had the typical appearance of air-filled spaces. Gentler hair grooming practices were recommended, and at a follow-up visit, the appearance of the hair had improved with darker and longer shafts. This case should alert clinicians to look for pili annulati when hair fragility is present.

Cutis. 2013;91:36-38.

Pili annulati is a rare condition with autosomal-dominant inheritance and variable penetrance affecting the hair shafts.^{1,2} Some sporadic cases without a family history also have been reported. Clinically, these individuals are noted to have a spangled appearance to their hair,^{1,3} which is caused

by a pattern of light and dark banding of variable periodicity that is visible to the naked eye. There is no association with diurnal rhythms despite the repetitive pattern of closely set air-filled spaces.² This pattern is created by alternating and abnormally wide pockets of air-filled spaces in the cortex of the hair shaft that appear darkened under a microscope. This darkness is due to the reflection of light back to the source (microscope bulb) without penetration and transillumination of the hair. Pili annulati most easily is diagnosed in light-haired individuals because darker hair absorbs the light and obscures the banding.^{1,2} Banding can be present in the axillae, beard, and pubic areas, though it most often is discovered in scalp hair.² Variability in the phenotype of pili annulati can be seen with both affected and unaffected hairs as well as variable banding along the hair shafts themselves.³ Since PA initially was described in 1866, fewer than 50 cases have been published.⁴

Case Report

A 14-year-old adolescent girl presented with a concern of progressive scalp hair loss of 2 months' duration. The patient was accompanied by her mother and both were distraught and anxious, insisting that the hair loss was severe. According to the patient's mother, hair loss had not been present at birth or during childhood. Neither parent nor any other family member had ever experienced similar hair loss. The patient did not have a history of eczema or scaly or serpiginous eruptions.

On physical examination the patient was emotional and tearful. She appeared well-developed and well-nourished. Her facial skin was smooth in texture, but a few milia were seen on both of her cheeks. Her teeth and the skin on her neck and upper torso appeared normal. Numerous erythematous, follicular, keratotic papules were noted on the posterior aspects of both of her upper arms, which was suggestive of keratosis pilaris. Cutaneous examination was otherwise unremarkable.

Dr. Werner is from Walter Reed Army Medical Center, Washington, DC. Dr. St-Surin-Lord is from Howard University College of Medicine, Washington, DC. Dr. Sperling is from the Department of Dermatology, Uniformed Services University, Bethesda, Maryland. The authors report no conflict of interest.

Correspondence: Kimberly Werner, MD, Walter Reed Army Medical Center, 6900 Georgia Ave NW, Washington, DC 20307 (kimberlyawerner@gmail.com).

The patient's hair was light brown with some blonde hairs and was noticeably shorter on the parietal aspects of the scalp compared to the occiput and vertex. Although the hair on the occiput was longer, it was sparse and thin. On clinical examination the overwhelming majority of hairs appeared spangled and lackluster (Figure 1). Handheld magnification revealed light and dark banding of the hairs (Figure 1 [inset]). Numerous split ends and broken hairs also were noted.

Several hair shafts were examined by conventional light microscopy and some of the hairs demonstrated trichoptilosis (Figure 2). Alternating light and dark bands within the shafts of the hair also were noted (Figure 3). The dark bands were roughly spindle shaped and occupied 40% to 80% of the hair shaft diameter (Figure 4). This dark appearance was typical of air-filled spaces. Some narrower, centrally located dark lines, which were typical of normal medullary spaces, also were focally seen. The hair was examined with polarizing filters but did not reveal any additional abnormalities.

The patient was diagnosed with pili annulati. Gentler hair grooming practices were encouraged, with a reduction in the frequency of blow-drying. Hair weaving and other styling methods that required twisting or traction were discouraged. At a follow-up visit 2 months later, her hair was a darker brown, and although she had cut her hair, the hair of the parietal scalp appeared less sparse (Figure 5). She confirmed that she had discontinued hair bleaching and was grooming her hair with greater care.



Figure 1. Spangled and lackluster appearance of hair on clinical examination. Handheld magnification revealed light and dark banding of hair (inset).



Figure 2. Trichoptilosis observed on light microscopy.




Figure 3. Light microscopy revealed light and dark bands within the shafts of the hair.



Figure 4. Spindle-shaped dark bands, occupying 40% to 80% of the hair shaft diameter.

Comment

To date, the pathogenesis of pili annulati is still undetermined, but 3 potential causes have been cited: a cytokeratin abnormality, an abnormality in

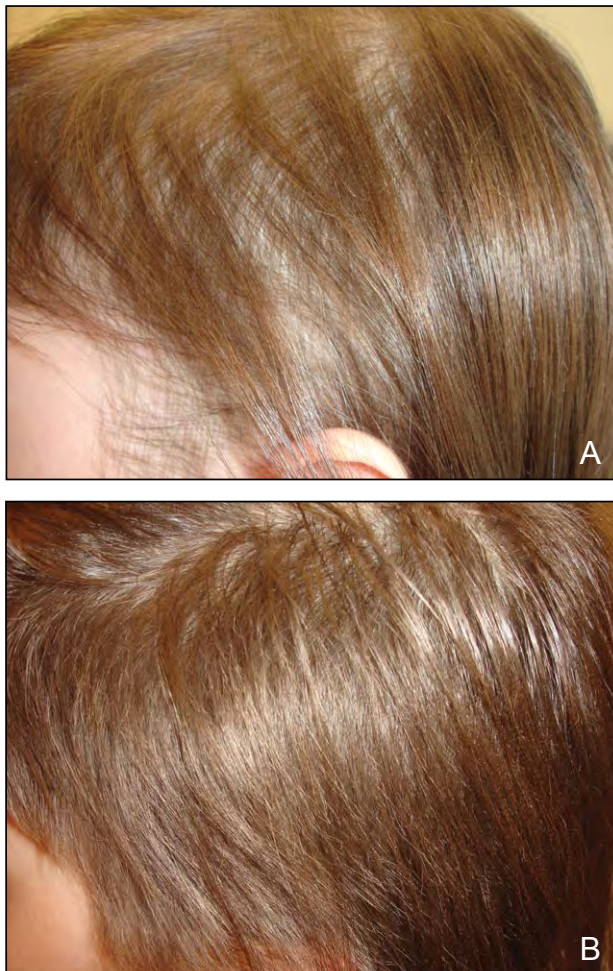

Figure 5. A patient with pili annulati before (A) and after gentle hair care modifications (B).

matrix formation, and a defect in the assembly of structural proteins in the extracellular matrix.^{1,4} None of these hypotheses have yet to be convincingly supported. Studies of cytokeratin expression have shown no difference in the immunohistochemical staining intensity and pattern in affected hairs of pili annulati versus controls.^{1,4} Alterations in the basement membrane zone, which plays a crucial role in the signaling required for cell differentiation and structural organization in hair growth, have been found using transmission electron microscopy and immunohistochemistry.³ Further studies of the pathogenesis of pili annulati clearly are required.

Complications of pili annulati are limited but include a possible increase in breakage from weathering of the abnormal hair shafts. Intermittent breaks in the affected hairs associated with the lighter bands have been documented.³ When using atomic force

microscopy, a tool used to determine the mechanical properties of biologic material, a notable difference was found in the stiffness between the light and dark bands of pili annulati hair samples, with more stiffness in the darker bands.⁵ Amino acid analysis has provided evidence of low cysteine and high lysine levels at lighter points, which provides a possible explanation for the alternating zones of stiffness because cysteine is crucial for hair fiber stability²; however, based on clinical experience, there appears to be no considerable increase in hair shaft fragility in most patients.⁵

Our case demonstrates that pili annulati and hair breakage can present simultaneously, but this connection does not prove that pili annulati is the direct cause of hair fragility. However, the widened intracortical air-filled spaces found in pili annulati suggest that the association is not coincidental, especially in the setting of harsh hairstyling practices. This case should alert clinicians to look for pili annulati when hair fragility is present. A larger study will need to be done to establish causation. Pseudopili annulati should be considered in the differential diagnosis; it can present with similar spangling of the hair but is caused by periodic twisting of the hair shaft. Pseudopili annulati can be excluded by light microscopy.⁴

There also has been some speculation that pili annulati is associated with alopecia areata, but no conclusive evidence for this association exists. Some authors speculate that pili annulati may be more noticeable in patients with alopecia areata because of more careful examination of the hair.²

REFERENCES

1. Giehl KA, Dean D, Dawber RP, et al. Cytokeratin expression in pili annulati hair follicles. *Clin Exp Dermatol.* 2005;30:426-428.
2. Giehl KA, Ferguson DJ, Dawber RP, et al. Update on detection, morphology and fragility in pili annulati in three kindreds. *J Eur Acad Dermatol Venereol.* 2004;18:654-658.
3. Giehl KA, Ferguson DJ, Dean D, et al. Alterations in the basement membrane zone in pili annulati hair follicles as demonstrated by electron microscopy and immunohistochemistry. *Br J Dermatol.* 2004;150:722-727.
4. Giehl KA, Rogers MA, Radivojkov M, et al. Pili annulati: refinement of the locus on chromosome 12q24.33 to a 2.9-Mb interval and candidate gene analysis [published online ahead of print November 25, 2008]. *Br J Dermatol.* 2009;160:527-533.
5. Streck AP, Moncores M, Sarmiento DF, et al. Study of nanomechanical properties of human hair shaft in a case of pili annulati by atomic force microscopy. *J Eur Acad Dermatol Venereol.* 2007;21:1109-1110.