



SURGICAL TECHNIQUES

Mastering the uterine manipulator: Basics and beyond

Why this device is indispensable and how to use it most effectively

Katherine Palmerola, MD, and Mireille D. Truong, MD

An essential but often overlooked component of a successful minimally invasive gynecologic procedure is uterine manipulation. Regardless of whether conservative or extirpative surgery is being performed, the ability to optimally position the uterus within the pelvis is critical to safe and efficient surgical dissection. The addition of a colpotomizer cup to any uterine manipulator further enhances the ability to perform a conventional or robot-assisted laparoscopic hysterectomy.

The following video, produced by my third-year resident, Katherine Palmerola, MD, and my second-year fellow, Mireille Truong, MD, aims to provide a quick reference for gynecologists to use to help teach their surgical assistants the fundamentals of assembly and use of a uterine manipulator. This video also can be used as a resource for educating residents and medical students on the essentials of uterine manipulation.

The objectives of this video are to:

- outline the required instruments and steps for assembling a uterine manipulator and colpotomizer cup
- demonstrate the technical nuances of proper uterine manipulation intraoperatively
- highlight important clinical applications of uterine manipulation during pelvic surgery.

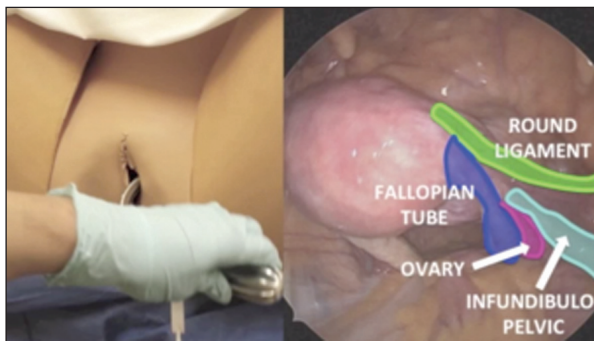
I hope this video proves to be a valuable resource for your practice. 📺

Dr. Palmerola is PGY-3 Resident, Department of Obstetrics and Gynecology, Columbia University Medical Center, New York, New York.

Dr. Truong is Fellow in Minimally Invasive Gynecologic Surgery, Columbia University Medical Center.

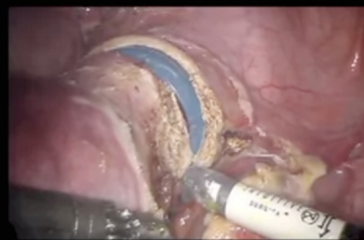
Dr. Advincula is Levine Family Professor of Women's Health, Vice-Chair, Department of Obstetrics and Gynecology, and Chief of Gynecology, Sloane Hospital for Women, Columbia University Medical Center. He also serves on the OBG MANAGEMENT Board of Editors.

Dr. Advincula reports being a consultant to Blue Endo, CooperSurgical, Intuitive Surgical, and SurgiQuest and receiving royalties from CooperSurgical. The other authors report no financial relationships relevant to this article.



COLPOTOMY CUP

- Delineation of anatomy
- Protection of vital structures
- Dissection
- Surgical Technique



▲ To view the video

Visit Arnold Advincula's Surgical Techniques Video Channel in the Video Library at obgmanagement.com or use the QR code at right >>>>



Watch for these video topics coming soon: Tips and tricks to understanding retroperitoneal anatomy and Simple versus radical hysterectomy: Anatomical nuances.

>> Dr. Arnold Advincula