

VIEW AN Accompanying Video

To watch a demonstration of various surgical techniques for managing urethral diverticula, visit www.obgmanagement.com



Pelvic surgery controversies

Managing troublesome urethral diverticula

Which test is best? Does medical therapy work? When should you consider surgery?

Urethral diverticula are often overlooked as a source of recurrent urinary tract infection, voiding dysfunction, dyspareunia, and chronic pelvic pain. Here, in brief, is how to diagnose and manage this condition, including a look at surgical options.

What are the common complaints?

Urethral diverticula present in myriad ways—most often, as recurrent urinary tract infection, overactive bladder, stress urinary incontinence, and pelvic pain. Other common presenting symptoms include voiding dysfunction, a painful or palpable mass, and postvoid dribbling.

What can be done routinely during a pelvic exam to make the Dx?

Become accustomed to massaging the anterior vaginal wall underneath the urethra. Any discharge or excretion of fluid that you observe from the external urethral meatus as you massage is pathognomonic for urethral diverticulum. In addition, palpate the anterior vaginal wall for paraurethral masses. Sometimes, a diverticulum is ballotable but not palpable.

Which test is best?

Imaging has been used in different ways, with variable success.

- Most diverticula are well visualized by voiding cystourethrography or magnetic resonance imaging (MRI); we view these as complementary techniques, in fact, because some diverticula are visualized only by one modality or the other. MRI provides a superior examination for surgical planning because it defines urethral and diverticular anatomy most clearly
- Ultrasonography has been used with some success
- Positive-pressure urethrography, using a Tratner or double balloon catheter, is difficult to perform and uncomfortable for the patient.

What is the role of urethroscopy?

We find urethroscopy very helpful. One caveat: Inability to visualize a diverticulum or its opening does not, by any means, exclude a urethral diverticulum.

How should you manage a urethral diverticulum?

- Urinary tract infection should be treated with a culture-specific antibiotic; in

Mickey M. Karram, MD

Director of Urogynecology, Good Samaritan Hospital, and Professor of Obstetrics and Gynecology, University of Cincinnati, Cincinnati, Ohio

Jerry G. Blaivas, MD

Clinical Professor of Urology, Weill Medical College of Cornell University, New York, NY

Drs. Karram and Blaivas co-chair the 6th Annual International Symposium on Female Urology & Urogynecology, to be held April 26–28, 2007, in Las Vegas (www.urogyn-cme.org).

FAST TRACK

Massage the anterior vaginal wall underneath the urethra; discharge or excretion of fluid from the external urethral meatus is pathognomonic

some cases, the patient will become asymptomatic afterwards

- Overactive bladder symptoms can be treated with an **anticholinergic**
- In most cases, **surgery** proves necessary
- When you identify a urethral diverticulum during pregnancy, manage the patient conservatively during the antenatal period
- A patient who has an asymptomatic urethral diverticulum can be managed expectantly, but perform a pelvic exam periodically.

When is surgery appropriate? By what method?

Several observations are useful:

- Hardness or induration of the diverticular mass is extremely rare; such a finding should prompt surgical excision because it may signal **cancer**
- **Marsupialization** has been demonstrated to be successful for very distal and small urethral diverticula
- Most diverticula at the level of the midurethra and proximal urethra require some form of **excision**, broadly classified as partial ablation or complete excision
- Placement of a **suburethral sling** is controversial, but some experts believe that, to prevent stress incontinence, this intervention should be undertaken simultaneously with any other surgical treatment for diverticula of the proximal urethra
- Sometimes a **Martius fat pad** must be brought into the field to avoid devascularization and breakdown of the repair. When a suburethral sling is necessary, we routinely place a Martius flap between the urethra and the sling. ■

VIEW AN **Accompanying Video**

To watch a demonstration of various surgical techniques for managing urethral diverticula, visit www.obgmanagement.com



FAST TRACK

A urethral diverticulum identified during pregnancy calls for conservative management antenatally

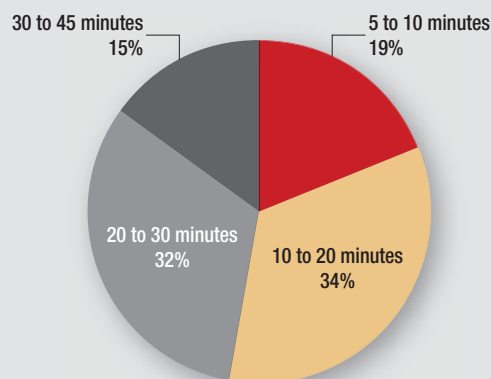
INSTANT POLL RESULTS

Here's how you and your peers voted

What is your crash C-section time?

A woman at term presents to your triage unit with persistent fetal bradycardia confirmed by ultrasonography.

From the time you call for a crash cesarean section, approximately how long does it take your team to deliver?



Metabolic syndrome

Diagnosis requires that we measure waist circumference and blood pressure, and obtain measurements of fasting glucose, triglycerides, and HDL-C. Are you collecting this information from your patients?

