

## Are steroid injections effective for tenosynovitis of the hand?

### Evidence-based answer

Yes. Steroid injections are an effective first-line therapy for flexor tenosynovitis of the hand, with a number needed to treat [NNT] of 2.3 for injection of steroids and lidocaine (strength of recommendation [SOR]: **B**, based on 1 prospective RCT and 2 low-quality studies). Injection into the tendon sheath may not be critical to a successful outcome (SOR: **B**, based on 1 prospective uncontrolled trial).

For de Quervain's tenosynovitis,

steroid injections without splinting are more effective than injection plus splinting or splinting alone. The cure rates are 83% (steroid alone), 61% (steroid plus splinting), and 14% (splinting alone) (SOR: **B**, based on a systematic review of descriptive noncontrolled studies). Injecting into the tendon compartments was more effective than injecting into the surrounding soft tissues (SOR: **B**, based on 1 prospective controlled trial).

### Clinical commentary

#### Steroids are helpful, especially for a quick return to function

I often see flexor and de Quervain's tenosynovitis in my practice, particularly among patients whose occupations require repetitive hand use. Acute treatment for these conditions typically consists of immobilization with buddy taping or finger/thumb spica splinting. For those who do not improve in 4 weeks, or require a quick return to function, I've found that corticosteroid injection using a 25- to 30-gauge needle can be very effective.

De Quervain's tenosynovitis must be injected into the sheath between the

abductor longus and extensor pollicis brevis; flexor tenosynovitis is injected in the nodule. I typically have excellent results, with patients returning to function within 72 hours. Depigmentation and atrophy can occur with injections, especially in small-statured or dark-pigmented patients. Surgical release is rarely required for either condition.

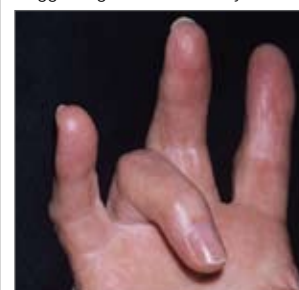
Infectious tenosynovitis must be recognized early; it is typically due to lacerations or puncture wounds. In these cases, I immediately refer to orthopedic surgery for further treatment and evaluation.

Robert Gauer, MD  
Fort Bragg, NC

Jeffrey B. Graham, MD,  
Stephen D. Hulkower, MD,  
and Michele Bosworth, MD  
MAHEC Family Medicine  
Residency Program,  
Asheville, NC

Elizabeth L. White, MLIS  
Carolinas Medical Center,  
Charlotte, NC

"Trigger finger" due to tenosynovitis



### FAST TRACK

**The exact location of a steroid injection for flexor tenosynovitis of the hand does not appear to be important**

### Evidence summary

Flexor tenosynovitis and de Quervain's tenosynovitis are the 2 most common types of tenosynovitis of the hand.

While the term "tenosynovitis" implies an inflammatory condition, pathoanatomically it is better described as a friction overuse injury, resulting in fibrosis

**FAST TRACK****For de Quervain's tenosynovitis, steroid injection into the tendon compartments was more effective than injection into the surrounding soft tissue**

of the surrounding tissue and subsequent narrowing of the synovium.<sup>1</sup>

**Flexor tenosynovitis: Steroid injections provided relief**

A prospective, double-blinded RCT<sup>2</sup> published by an orthopedic group in 1995 compared 24 patients with primary flexor tenosynovitis. Patients were injected with either 1 cc of betamethasone (Celestone 6 mg) and 3 cc of 1% lidocaine, or 4 cc of 1% lidocaine alone. A successful outcome was defined as absence of triggering and pain, both subjectively and on examination. Follow-up examination was completed for all patients at 3 weeks and 4 months after injection.

The treatment group had success outcomes for 10 of 14 patients (71%) at 3 weeks and 9 of 14 patients (64%) at 4 months, compared with 2 of 10 (20%) at both 3 weeks and 4 months in the control group (NNT=2.3;  $P<.05$  at 4 months). No significant side effects were noted. It is unclear how the study blinded the white, thick consistency of betamethasone compared with the clear nature of lidocaine alone.

**Injection site may not matter.** In another prospective, uncontrolled trial, 107 patients with flexor tenosynovitis were injected with 1 cc of betamethasone, 0.5 cc of 1% lidocaine, and 0.5 cc of radio opaque dye.<sup>3</sup> Some patients got their injections in the tendon sheath at the A1 pulley site, others got their injections in the subcutaneous tissue surrounding the pulley, and a third group got injections in both sites. Patients graded their relief subjectively as either good (total alleviation of symptoms), fair (lasting improvement), or poor (only transient improvement or none at all).

Those who received an intrasheath injection reported good results 47% of the time at 2 weeks follow-up, compared with 70% and 50% for patients in the subcutaneous and mixed groups, respectively. There was no statistically significant difference between the groups, suggesting

that the exact location of injection may not be important.

**de Quervain's tenosynovitis: Steroids better than splinting**

A pooled quantitative literature search concerning the treatment of de Quervain's tenosynovitis compared 7 studies (a total of 459 wrists) with identical diagnostic and success criteria.<sup>4</sup> Average follow-up was 9.6 months (range, 1 week to 7 years). There were no control groups in the studies, and none of the studies were randomized. Of the 226 cases treated with steroid injection alone, 83% were cured, though 30 of these needed a second injection. Sixty-one percent of those treated with injection and splint were cured, while 14% treated with splint alone reported cure.

**Steroids outperform splinting and NSAIDs.** A retrospective study not included in the above review compared steroid injection with splinting and nonsteroidal anti-inflammatory drugs (NSAIDs).<sup>5</sup> Researchers stratified subjects into minimal, mild, or moderate-to-severe, based on their severity of disease and limitation on their activities of daily living. Mean follow-up was 2.3 years.

Of those cases treated with splinting and NSAIDs, 15 of 17 in the minimal group had resolution of symptoms, but only 4 of 20 in the mild group and 2 of 8 in the moderate-to-severe group had symptoms resolve. The injection group obtained better results, with 100% of cases in the minimal and mild groups resolving and 76% of those in the more severe group resolving completely, with an additional 7% reporting improvement.

**Injection site appears to matter with de Quervain's tenosynovitis.** In 1 small, controlled, prospective, double-blinded study, the authors attempted to correlate clinical relief of de Quervain's tenosynovitis with accuracy of injection into the first dorsal compartment.<sup>6</sup> The researchers enrolled 19 patients. The same hand surgeon injected 3 cc of 1% lidocaine, 1 cc betamethasone, and 1 cc Omnip-

aque 300 dye into the abductor pollicis longus sheath and then attempted, with ulnar deviation of the needle, to fill the extensor pollicis brevis sheath.

Patients were followed-up at 1 month and 3 months postinjection. Success—defined as a negative Finkelstein’s test, absence of pain, and normal activities of daily living—was noted in 11 of 19 patients at 3 months. In a radiographic check, 4 of 5 of the patients with dye in both compartments were asymptomatic, while the 3 who had no dye in either compartment remained symptomatic. This suggests that the location of injection may be important in de Quervain’s tenosynovitis.

### Recommendations from others

The Brigham and Women’s Hospital guidelines for treatment of de Quervain’s tenosynovitis state that corticosteroid injections “may be very helpful,” and that they should be considered if symptoms persist beyond 6 weeks of conservative treatment.<sup>7</sup> *DeLee and Drez’s Orthopaedic Sports Medicine* text recommends corticosteroid injection for de Quervain’s tenosynovitis after 2 weeks of conservative treatment have failed.<sup>8</sup>

UpToDate recommends steroid injection for de Quervain’s tenosynovitis if pain persists for more than 2 to

6 weeks despite splinting, icing, and NSAID therapy.<sup>9</sup> For flexor tenosynovitis, UpToDate recommends local injection when symptoms persist for 4 to 6 weeks despite splinting.<sup>10</sup> ■

### References

1. Zingas C, Failla JM, Van Holsbeeck M. Injection accuracy and clinical relief of de Quervain’s tendinitis. *J Hand Surgery (Am)* 1998; 23:89–96.
2. Murphy D, Failla JM, Koniuch MP. Steroid versus placebo injection for trigger finger. *J Hand Surg (Am)* 1995; 20:628–631.
3. Taras JS, Raphael JS, Pan WT, et al. Corticosteroid injections for trigger digits: is intrasheath injection necessary? *J Hand Surg (Am)* 1998; 23:717–22.
4. Richie CA 3rd, Briner WW Jr. Corticosteroid injection for treatment of de Quervain’s tenosynovitis: a pooled quantitative literature evaluation. *J Am Board Fam Prac* 2003; 16:102–106.
5. Lane LB, Boretz RS, Stuchin SA. Treatment of de Quervain’s disease: role of conservative management. *J Hand Surgery (Br)* 2001; 26:258–260.
6. Zingas C, Failla JM, Van Holsbeeck M. Injection accuracy and clinical relief of de Quervain’s tendinitis. *J Hand Surgery (Am)* 1998; 23:89–96.
7. Brigham and Women’s Hospital. *Upper Extremity Musculoskeletal Disorders: A Guide to Prevention, Diagnosis and Treatment*. Boston, Mass: Brigham and Women’s Hospital; 2003:9.
8. DeLee J, Drez D, Miller M. *DeLee and Drez’s Orthopaedic Sports Medicine: Principles And Practice*. 2nd ed. Philadelphia, Pa: Saunders; 2003.
9. Anderson BC, Sheon RP. de Quervain’s tenosynovitis. UpToDate [online database]. Updated May 7, 2004. Waltham, Mass: UpToDate; 2004.
10. Anderson BC. Trigger finger (flexor tenosynovitis). UpToDate [online database]. Updated December 26, 2000. Waltham, Mass: UpToDate; 2000.

## Next month in Clinical Inquiries

- What are the most effective non-drug therapies for irritable bowel syndrome?
- Is low-dose aspirin therapy effective in reducing pre-eclampsia and associated maternal-fetal complications?
- What is the best approach to malaria prophylaxis during pregnancy?

### FAST TRACK

**Steroid injection alone had a better cure rate for de Quervain’s tenosynovitis (83%) than steroids plus splinting (61%)**